

## A Rare Case of Soft Tissue Sarcoma of Gingiva

Varsha S Jadhav <sup>1\*</sup>, Avinash S Jadhav<sup>2</sup> and Swati<sup>3</sup>

### Affiliation:

<sup>1</sup>Private Practice, India

<sup>2</sup>Associate Professor Pediatric Surgery, AIIMS Jodhpur, India

<sup>3</sup>Assistant Professor, RUHS College of Medical Sciences, India

\*Corresponding Author: Dr. Varsha S Jadhav, Private Practice, India.

Received: February 16, 2021 Published: April 05, 2021

### Abstract:

Soft tissue sarcoma in children is very rare and very few cases have been reported with primary involvement of oral soft tissues. Only 1 to 3% of primary malignant fibrous histiocytoma occur in head and neck region and they have a poor prognosis. This case report describes an unusual presentation of primary malignant fibrous histiocytoma with an aggressive course originating from the gingiva and covering hard and soft palate with extension in maxillary sinus in a 12 year old girl. Hemi-maxillectomy was performed and chemotherapy and radiotherapy administered.

**Keywords:** Fibrous Histiocytoma; Aggressive; Soft Tissue Sarcoma; Imaging; Gingiva; Maxillary Sinus

### Introduction

Malignant fibrous histiocytoma (MFH) was first described by O'Brien and Stout in 1964 [1] and was distinguished as a primordial, pleomorphic sarcoma with partial fibroblastic and histiocytic differentiation [2]. It is the most common soft tissue sarcoma of late adult life, however, using the current World Health Organization (WHO) classification, it accounts for <5% of soft tissue sarcomas in adults [3] and the prognosis is poor [4]. The extremities and retroperitoneum are the most common sites of involvement. Other than soft tissue, this tumor has been reported to occur in almost every part of the body, including bone, viscera, and skin [4,5]. Only ≈1% to 3% of these tumors occur in the head and neck region [2]. Few cases with involvement of the mandible, maxilla, and maxillary sinus [5,6] have been reported, of which some invaded bone. There have been very few cases with primary involvement of the oral soft tissues, excluding cases of post-radiation MFH and those with the preexistence of other primary malignancies [7,8]. To the best of our knowledge, very few cases of MFH with primary involvement of the gingiva have been reported [8,9]. The present report describes an unusual presentation of primary malignant fibrous histiocytoma with an aggressive course originating from the gingiva and covering hard and soft palate with extension in maxillary sinus in a 12year old girl.

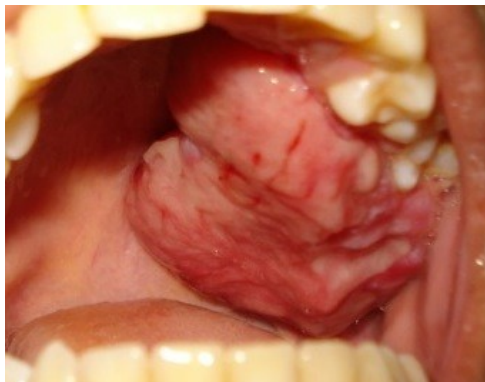
### Case Report

In August 2012, a 12-year-old female came to the Department of Periodontology and Oral Implantology, Government Dental College and Hospital, Jaipur with a complaint of growth of gingiva and hard palate in maxillary left posterior quadrant. The patient reported that she initially noted overgrowth of palatal and buccal gingiva of maxillary left first molar tooth in June 2012. Later, the growth size increased rapidly to the present size and covered the hard and soft palate also. She complained of buccal displacement of first and second molar teeth and also inability to perform routine oral hygiene procedures and discomfort while masticating and swallowing. She gave history of fever 15 days prior to the first visit for which she consulted general physician and on taking medications she was relieved of symptoms in 3 days and was further referred to a dentist.

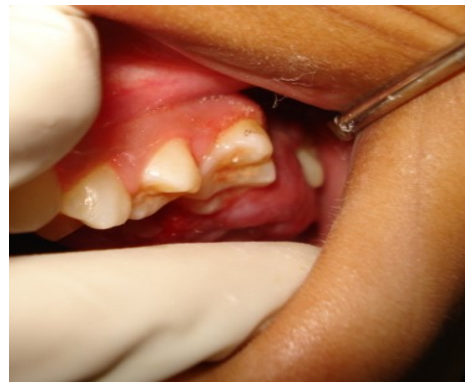On clinical examination, the extent of growth was seen spanning from first premolar (#24) to distal of second molar (#27) and palatally till midline of hard palate and extending to soft palate. The outer surface was smooth, except for areas of occluding surfaces with mandibular teeth where ulceration was evident. The color was similar to that of adjacent gingiva. (fig 1) There were no complaints related to sino-nasal tract. On palpation the growth was firm in consistency and was attached to palatal and buccal gingiva of molars with displacement of both molars and covering but not involving the hard and soft palate. A probe can easily be passed between the growth and hard palate.

On computed tomography scan (fig 2), there was evidence of lytic lesion of soft tissue density in left maxilla extending into left maxillary sinus. Rest of the paranasal sinuses were normal. The hematological investigations were also advised and were found to be within normal limits. Considering the nature and extent of the growth, incisional biopsy was done. Histopathological examination (fig 3) showed a highly cellular neoplasm with interlacing bundles of collagen fibers. In most areas, the cells were arranged in a random and haphazard manner and morphology was variable. The morphology of fibroblast like cells nuclei varied greatly, and were hyperchromatic. There were also many large, plump, round or stellate histiocyte-like cells whose abundant cytoplasm also was often vesicular. They had large, irregular, vesicular nuclei which often contained one or more prominent nucleoli. The tumor cells were arranged in a storiform pattern and were round to polygonal, with cellular pleomorphism, nuclear hyperchromatism, and mitotic figures. Immunohistochemical staining was done to rule out other tumors of vascular, neural, epithelial and muscular origin. Staining was positive for reticulin, but it was negative for CD34, epithelial membrane antigen (EMA), S100, and smooth muscle actin (SMA).

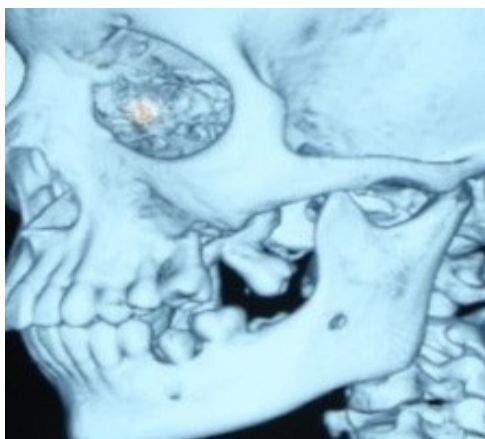
Based on the clinical, histopathologic, and immunohistochemical analysis, the patient was diagnosed with MFH originating from the maxillary gingiva. A posterior-anterior radiograph of the chest was done to check for possible metastases. Lungs were found to be clear radiographically. When patient came eight days after the biopsy was taken, it was found that the growth has increased in size. The patient was referred to Department of Oral and Maxillofacial Surgery for further treatment. Hemimaxillectomy was done and a splint was placed. After the surgical phase, the patient was followed up for 3 months. Recurrence was noted after 3 months and radiograph of the chest revealed metastases to the lungs. The patient was referred to the Department of Oncology and Pediatric Surgery, Sawai Man Singh Hospital, Jaipur. During the course of chemotherapy and radiotherapy, the patient succumbed to the disease in 1 month time.



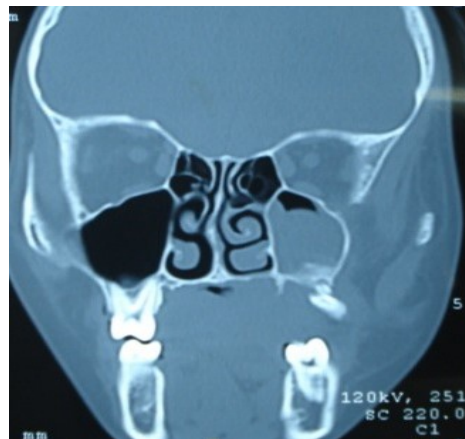**Figure 1:** Showing the anteroposterior extent of the tumor.



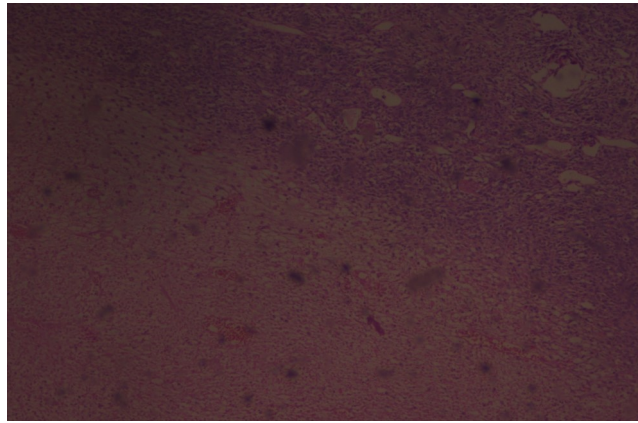
**Figure 2:** Showing the buccal extent of the tumor and displacement of molars.



**Figure 3:** Computed tomography scan revealing displacement of molars



**Figure 4:** Computed tomography scan showing lytic lesion of soft tissue density in left maxilla extending



**Figure 5:** Histopathological picture revealing highly cellular neoplasm with interlacing bundles of collagen fibers. Haphazard and random arrangement of cells can be seen.

### Discussion:

Previous case reports [9,10] have described a slowly growing mass as the most common clinical sign of MFH. However, in the present case, a rapidly growing growth of gingiva was seen, which is an unusual form of presentation of MFH [11]. It was thought of as a tumor of a histiocytic origin, recent advances of immunohistochemistry and numerous monoclonal antibodies demonstrated a closer phenotypic link with the fibroblasts, myofibroblasts, or undifferentiated mesenchymal cells [11]. Histopathologically, MFH can be divided into the following 4 morphologic subtypes in decreasing order, depending on the predominant cellular components: storiform-pleomorphic (50%–60%), myxoid (25%), giant cell (5%–10%), and inflammatory (>5%), some of which have prognostic significance [10,11]. The myxoid variant has better prognosis compared with the storiform-pleomorphic type. The giant cell form was reported as having the worst prognosis [9]. In the present case, several morphologic patterns were observed in one lesion.

Most cases of MFH are between 50 and 70 years of age, and men are afflicted 2–3 times as commonly as women, most commonly in the lower extremity followed by the upper extremity and the retroperitoneum [2]. However, in the present case growth was found in a female child of 12 years age. As morphological features remain far from established due to rarity of these tumours, the diagnosis of MFH is dependent on excellent sampling and the evaluation of hematoxylin and eosin stained sections. In the present case, the storiform pattern of arrangement of fibroblasts was seen, which is diagnostic for MFH. Due to the pleomorphic spindle cell morphology of this tumour, following close differentials need to be excluded by IHC, such as sarcomatoid variant of squamous cell carcinoma, spindle cell melanoma, malignant peripheral nerve sheath tumour, and synovial sarcoma. In the present case, tumors of vascular, neural, muscular and epithelial origin were also ruled out because cells stained negative for CD34, S100, SMA and EMA, respectively. Hematoxylin and eosin stained sections showed some immature fibroblasts for which the reticulin stain was positive; however, reticulin positivity is not confirmatory for MFH. Detailed radiological survey is warranted in these cases so as to establish them as primary lesions. Moreover, CT scan is required to define the tumour extent and to rule out the involvement of surrounding structures.

In general, head and neck MFH is reported to be associated with a poorer prognosis, compared with MFH elsewhere in the body [11]. Inadequate removal of the tumor is associated with a high recurrence rate of 20%–42%. Systemic metastases are also common, reported in 25%–35% [11]. Sabesan et al [12] reported a 48% 5-year survival rate for MFH of the head and neck, which is much lower than 77% for MFH of the trunk and extremities. Tumors that extend into bony structures are associated with a much more aggressive clinical course than those that are restricted to soft tissues. Recurrence was reported in two patients, both with metastases to the lungs [9]. As preoperative radiotherapy remains unpredictable, radical surgical excision is the management of choice [8]. Irradiation and chemotherapy have also been used in combination with surgery. The decision to use radiotherapy is dependent on the size, site, histologic grade, and the width of surgical markings. Chemotherapy consists of the administration of anticancer agents, such as methotrexate, cisplatin, doxorubicin, cyclophosphamide, actinomycin d, vincristine, dacarbazine, and ifosfamide, in patients with soft tissue sarcomas [5]. Hence, hemi-maxillectomy was performed and later combination of chemotherapy and radiotherapy was given in the present case.

### Conclusion:

The occurrence of primary MFH in gingiva and palate is rare and it may have an aggressive course. This tumor can be confused with a variety of fibrous tumors and inflammatory conditions. Hence, a biopsy and complete work up is essential to arrive at a final diagnosis, rule out metastases and provide the patient with appropriate treatment and care.

## References:

1. O'Brien JE, Stout AP. Malignant fibrous xanthomas. *Cancer* 1964, 17:1445-58.
2. Weiss WS, Enzinger FM. Malignant fibrous histiocytoma. An analysis of 200 cases. *Cancer* 1978, 41:2250-66.
3. Fletcher CDM. The evolving classification of soft tissue tumors: An update based on the new WHO classification. *Histopathology* 2006;48:3-12.
4. Huvos AG, Heilweil M, Bretsky SS. The pathology of malignant fibrous histiocytoma of bone: a study of 130 patients. *Am J Surg Pathol* 1985;9:853-71
5. Slootweg PJ, Muller H. Malignant fibrous histiocytoma of the maxilla. Report of a case. *Oral Surg Oral Med Oral Pathol* 1977;44:560-66.
6. Tovi F, Sidi J. Malignant fibrous histiocytoma of the maxillary sinus. *J Oral Surg* 1979;37:500-03.
7. Ohmori T, Arita N, Sano A, et al. Malignant fibrous histiocytoma showing cytoplasmic hyaline globules and stromal osteoids. A case report with light and electron microscopic, histochemical and immunohistochemical study. *Acta Pathol Jpn* 1986;36:1931-41.
8. Amornmarn R, Prempre T, Perez RA, et al. Malignant fibrous histiocytoma of the gingiva. A clinicopathological study. *J Fla Med Assoc* 1991;78:149-52.
9. Agnihotri R, Bhat KM, Bhat GS. A Rare Case of Malignant Fibrous Histiocytoma of the Gingiva. *J Periodontol* 2008;79:955-60.
10. Rapidis AD, Andressakis DD, Lagogiannis GA, Douzinas EE. Malignant fibrous histiocytoma of the tongue: Review of the literature and report of a case. *J Oral Maxillofac Surg* 2005;63:546-50.
11. Park SW, Kim HJ, Lee JH, Ko YH. Malignant Fibrous Histiocytoma of the Head and Neck: CT and MR Imaging Findings. *AM J Neuroradiol* 2009; 30: 71-76.
12. Sabesan T, Xuexi W, Yongfa Q, et al. Malignant fibrous histiocytoma: outcome of tumors in the head and neck compared with those in the trunk and extremities. *Br J Oral Maxillofac Surg* 2006;44:209 -12.

**Citation:** Varsha S Jadhav, Avinash S Jadhav and Swati. "A Rare Case of Soft Tissue Sarcoma of Gingiva". *SVOA Dentistry* 2:3 (2021) Pages 99-102.

**Copyright:** © 2021 All rights reserved by Varsha S Jadhav, et al. This is an open access article distributed under the Creative Commons Attribution License, which permits unrestricted use, distribution, and reproduction in any medium, provided the original work is properly cited.