

Unilateral Cleft Palate Rehabilitated with Zygomatic Implants–Case Report

Fernando Duarte^{1*}, Carina Ramos² and João Neves Silva³

Affiliation

¹ Fernando Duarte, CEO and Clinical Director of Clitrofa - Trofa - Portugal

² MSc student in Oral Oncology at Instituto de Ciências Biomédicas Abel Salazar - Oporto University – Portugal

³ Professor at ISAVE - Instituto Superior de Saúde - Portugal

Corresponding Author: Fernando Duarte, Clitrofa – Centro Médico, Dentário e Cirúrgico, Avenida de Paradela 626, 4785-342 Trofa – Portugal, Phone: (351) 252428960.

Received: April 26, 2021 **Published:** May 05, 2021

Abstract:

Purpose: Unilateral cleft lip and palate is a defect involving the lip, nose and maxilla. These structures are inter-related, and simultaneous early correction of all the aspects of the defect is necessary to obtain a satisfactory result that will be maintained with growth. There are few reports about oral rehabilitation with dental implants, in patients with this condition in the literature.

Material and Method: The presented case report describes the clinical and surgical management of a patient with unilateral alveolar cleft associated to severe posterior maxilla bone resorption. This patient was treated with 2 zygomatic implants (S.I.N.-Implant System, São Paulo, Brazil) in the posterior maxilla and 4 standard axial implants in the anterior maxilla.

Results: The patient is on ten years of postoperative without complaints.

Conclusion: The high survival rate, the increase of patients' demand in immediate functional ability and the less morbidity following the surgical procedure renders this zygomatic implant procedure a viable treatment option of the resorbed fully edentulous maxilla.

Keywords: Zygomatic implant, Unilateral Cleft Palate, Atrophic maxilla

Introduction

Clefts of the lip and palate are commonly encountered congenital anomalies that often result in severe functional deficits of speech, mastication and deglutition. The prevalence of associated congenital malformations, as well as learning disabilities secondary to hearing deficits, is often increased ⁽¹⁾.

Generally, clefts of the lip and palate are classified into four major types: a) cleft lip, b) cleft palate, c) unilateral cleft lip and palate, and d) bilateral cleft lip and palate. Other clefts of the lip and mouth include lip pits, linear lip indentations, submucosal clefts of the palate, bifid uvula and tongue, and numerous facial clefts extending through the nose, lips and oral cavity. Cleaving deformities are extremely variable in character; they may range from furrows in the skin and mucosa to extensive cleavages involving muscle and bone. A combination of cleft lip and palate is the most common cleaving deformity seen ^(1,2).

Etiology and Pathogenesis

Cleft lip and palate account for approximately 50% of all cases, whereas isolated cleft lip and isolated cleft palate each occur in about 25% of cases.

The incidence of cleft lip and cleft palate has been reported to be 1 in 700 to 1000 births, with variable racial predilection. Isolated cleft palate is less common, with an incidence of 1 in 1500 to 3000 births. Cleft lip with or without cleft palate is more common in males, and cleft palate alone is more common in females⁽³⁾.

The majority of cases of cleft lip or cleft palate, or both, can be explained by the multifactorial threshold hypothesis. The multifactorial inheritance theory implies that many contributory risk genes interact with one another and the environment and collectively determine whether a threshold of abnormality is breached, resulting in a defect in the developing fetus. Multifactorial or polygenic inheritance explains the transmission of isolated cleft lip or palate, and it is extremely useful in predicting occurrence risks of this anomaly among family members of an affected individual^(1,2,3).

Disruption of normal patterns of facial growth, including deficiencies of any of the facial processes, may lead to maldevelopment of the lips and palate. Cleft lip generally occurs at about the sixth to seventh week in utero; it is a result of failure of the epithelial groove between the medial and the lateral nasal processes to be penetrated by mesodermal cells^(1,2,3).

Cleft palate is a result of epithelial breakdown at about the eighth week of embryonic development, with ingrowth failure of mesodermal tissue and lack of lateral palatal segment fusion. Most embryologists believe that true tissue deficiencies exist in all clefting deformities and that actual anatomic structures are absent. Various degrees of cleft lip and palate may occur, ranging from mild notching of the vermilion border or bifid uvula to severe bilateral complete clefts of the lip, alveolus, and entire palate^(1,2).

Clinical Features

The Veau system of classification for cleft lip and palate is widely used by clinicians; it helps to describe the variety of lip and palatal clefts seen. The system classifies cleft lip and cleft palate separately into four major categories, with emphasis on the degree of clefting present (Fig. 1).

Cleft lip may vary from a pit or small notch in the vermilion border to a complete cleft extending into the floor of the nose. Using the Veau classification, a Class I cleft of the lip is a unilateral notching of the vermilion border that does not extend into the lip. If the unilateral notching of the vermilion extends into the lip but does not involve the floor of the nose, it is designated as a Class II cleft. Class III lip clefts are unilateral clefts of the vermilion border extending through the lip into the floor of the nose. Any bilateral cleft of the lip, exhibiting incomplete notching or a complete cleft, is classified as a Class IV cleft⁽¹⁾.

Clefting deformities of the palate can also be divided into four clinical types using the Veau system. A cleft limited to the soft palate is a Class I palatal cleft. Class II clefts are defects of the hard and soft palate; they extend no farther than the incisive foramen and therefore are limited to the secondary palate only. Clefts of the secondary palate may be complete or incomplete. A complete cleft includes the soft and hard palate, extending to the incisive foramen. An incomplete cleft involves the velum and a portion of the hard palate, not extending to the incisive foramen. Complete unilateral clefts extending from the uvula to the incisive foramen in the midline and the alveolar process unilaterally are designated as Class III palatal clefts. Class IV clefts are complete bilateral clefts involving the soft and hard palate and the alveolar process on both sides of the premaxilla, leaving it free and often mobile⁽¹⁾.

Submucosal clefts are not included in this system of classification, but they can be identified clinically by the presence of a bifid uvula, palpable notching of the posterior portion of the hard and soft palate, and the presence of a zona pellucida (a thin translucent membrane) covering the defect⁽¹⁾.

Clefts of the soft palate, including submucosal clefts, are often associated with velopharyngeal incompetence or eustachian tube dysfunction. Recurrent otitis media and hearing deficits are common complications. Palatal pharyngeal incompetence results from failure of the soft palate and pharyngeal wall to make contact during swallowing and speech, thus preventing the necessary muscular seal between the nasopharynx and the oropharynx. Speech is often characterized by air emission from the nose and has an hypernasal quality⁽³⁾.

The prevalence of dental anomalies associated with cleft lip and palate is remarkable. Abnormalities of tooth number, size, morphology, calcification and eruption have been well described. Both deciduous and permanent dentitions may be affected. The lateral incisor in the vicinity of the clefts is often involved, but teeth outside the cleft area exhibit developmental defects to a greater degree than is seen in unaffected patients^(3,4,5).

The incidence of congenitally missing teeth is high, especially among deciduous and permanent maxillary lateral incisors adjacent to the alveolar cleft. The prevalence of hypodontia increases directly with the severity of the cleft. Complete unilateral and bilateral alveolar clefts are often associated with supranumerary teeth as well, usually the maxillary lateral incisors. Tooth formation is often delayed and enamel hypoplasia, microdontia and macrodontia, and fused teeth are often seen^(3,4,5).

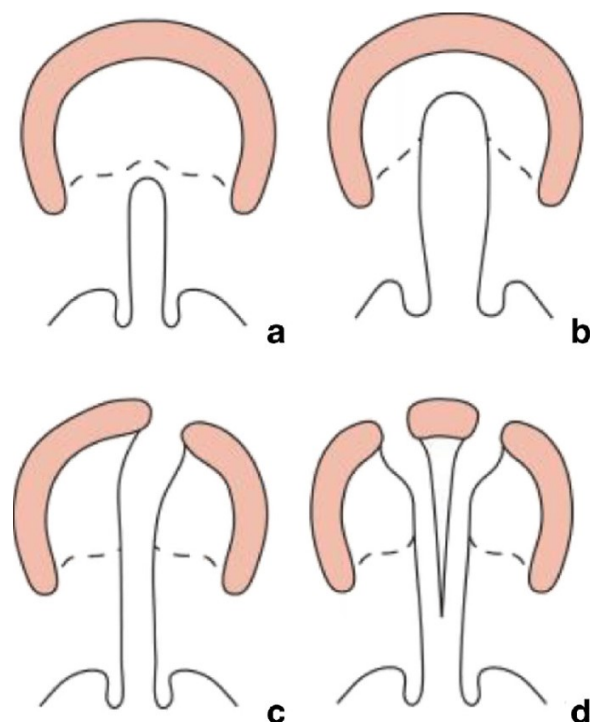


Fig: 1 – Veau classification of cleft lip and cleft palate

Zygomatic Implant Concept

Osteointegration techniques for maxillary rehabilitation are more complex than those for mandibular rehabilitation, due to the proximity of the nasal cavities and maxillary sinuses, the degree of maxillary bone resorption (particularly in the posterior region by early extractions, pneumatization of the maxillary sinuses) and the quality of the maxillary bone, more vascularized and less dense than the mandibular bone⁽⁶⁾. Patients with adequate maxillary bone availability are exceptions, most have different degrees of atrophy that require the use of alternative techniques for using existing bone (eg pterygoid implant), using autogenous or alloplastic bone grafts (eg onlay bone grafts in the maxilla, bone grafts of the maxillary sinus) or osteogenic distraction techniques (eg Le Fort I maxillary fracture)⁽⁷⁾. These procedures, although offering higher success rates for osteointegration, have disadvantages, namely, the need for multiple surgical interventions, restriction of the use of prosthesis for a long transitional period (minimum 4 months), greater morbidity, higher surgical and hospitalization costs^(6,7).

In the early 1990s, with his experience in animal and human research, PI Brånemark acknowledged that the introduction of implants in the maxillary sinuses did not necessarily compromise breath health. The use of the zygomatic bone as an anchorage point for implants, would ensure the prosthetic rehabilitation of mutilated patients, resulting from surgeries of tumor resection, trauma or congenital facial defects^(6,7). As these interventions were successful and the long-term stability of these implants was verified, Brånemark developed the zygomatic implant, which provides bone fixation under conditions of severe resorption or bone loss in the posterior maxilla, with the advantage of eliminating the need for bone grafts in its intervention area^(6,7,8).

The zygomatic implant design and placement protocols have been extensively described previously. In short, the implant, ranging from 32 mm to 62 mm, is introduced into the second premolar area, traversing the maxillary sinus and is anchored in the zygomatic bone. In addition to 2 zygomatic implants, 2 to 4 conventional implants are required in the anterior maxilla to support the prosthesis^(9,10). Zygomatic implants have shown good clinical success rates in clinical studies, most often close to 100% success with follow-up periods of up to 5 years^(11,12,13,14). Furthermore, placement of four zygomatic implants in the same maxilla has also been reported to be a clinically successful treatment option, with similar complications to those experienced with the original technique⁽¹⁵⁾.

Due to the high osseous density of zygomatic bone and to the high clinical survival rates associated with zygomatic implants^(11,12,13,14), this tissue/implant interface is particularly suitable for immediate function.

The surgery for placing zygomatic implants has an outpatient nature and is performed under general anesthesia, and the patient may be discharged a few hours after its completion^(7,8,16). The procedure begins with a palatal incision along the entire maxillary ridge, or optionally, with an incision at the bottom of the maxillary vestibule (type Le Fort I), and discharge incisions may be necessary to facilitate soft tissue detachment throughout the thickness of the maxilla, from the posterior aspect to the nasal cavities and the folding of the tissue, from the maxillary crest to the region of the body of the zygomatic bone^(7,8,16,17,18).

The nerve and infraorbital vessels, the zygomatic process of the maxilla and the zygomatic notch must be identified ⁽⁸⁾. Then, the palatal fibromucosa is detached and folded, identifying the posterior palatal orifices ⁽⁸⁾. At this stage the entire jaw is exposed.

A bone window opens in the superolateral region of the anterior wall of the maxilla, at the limit between the zygomatic bone and the maxillary sinus, to allow access to the interior of the maxillary sinus, the removal of the Schneiderian membrane, the visualization and routing of the implant ⁽⁸⁾. This access is also useful, during the surgical procedure, for cooling the drills, irrigating and cleaning the sinus during and after implant placement ⁽⁸⁾.

Surgical instrumentation now begins, with drilling and widening of the bone bed that receives the implant. Perforations are made in the palatal aspect of the alveolar region of the maxilla, reach the maxillary sinus and continue close to the lateral wall of the maxillary zygomatic process, until it enters the cortical bone again into the body of the zygomatic bone. It is intended to transfix the body of the zygomatic bone, in order to guarantee a bicortical anchorage and the use of the entire area liable to osteointegration. Once the maxillary and zygomatic bone bed has been created, the implant is inserted using a low-speed motor or an appropriate manual key.

After implant placement, its intraoral end is closed with a cover screw or multi-unit and soft tissues are sutured ⁽⁸⁾. There is no evidence to support the closure of maxillary sinus trepanation ⁽⁸⁾.

The original technique described above can be adapted and simplified in certain cases, in order to allow the emergence of the implant on the alveolar crest and in more anterior regions of the maxilla. In this procedure, called Sinus Slot Technique, the implant does not cross the maxillary sinus, a groove is created on the external face of the anterior wall of the maxilla, through which the implant is guided from the intra-oral perforation site to the insertion site zygomatic, at the junction between the lateral orbital edge and the zygomatic arch ^(7,18).

According to the original PI Brånemark protocol, the anterior maxilla sector is rehabilitated using 2 to 4 conventional osteointegrated implants, according to local bone availability, and it is sometimes necessary to proceed with bone graft techniques to ensure the viability of the implants. Implants ^(7,8). The Quadrilex method, modifies the original protocol by using four zygomatic implants, in order to eliminate the need for bone grafts or other techniques to increase bone heritage ⁽¹⁷⁾. This technique allows the rehabilitation of the patient in just one surgical period and, despite being more demanding in technical terms for the surgeon, it does not present major postoperative complications than the original procedure ⁽¹⁷⁾.

Clinical Case

A 59-year-old female patient, caucasian, attended the Oral-Maxillofacial Surgery consultation at Clitrofa - Centro Médico, Dentário e Cirúrgico, in Trofa - Portugal, to perform an implant-supported rehabilitation of the upper and lower jaws.

The clinical evaluation reveals a unilateral cleft palate patient, a partially edentulous upper jaw with the presence of teeth 1.1, 1.3 which supported a fixed ceramic bridge and 2.7 (Fig. 2).

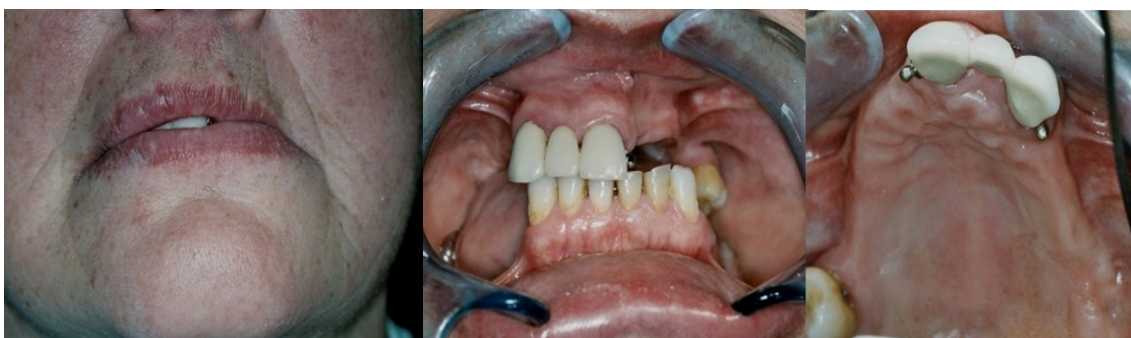

Fig: 2 - Intra-oral aspect of initial clinical condition

After anamnesis, there was no allergies or use of medications. To complete the pre-surgical evaluation, computed tomography was performed, which revealed an extremely resorbed maxilla in the posterior sector. Clinical case with indication for placing 2 zygomatic implants (S.I.N.-Implant System, São Paulo, Brazil) in the posterior sector and 4 standard axial implants in the anterior sector of the maxilla (Fig. 3).

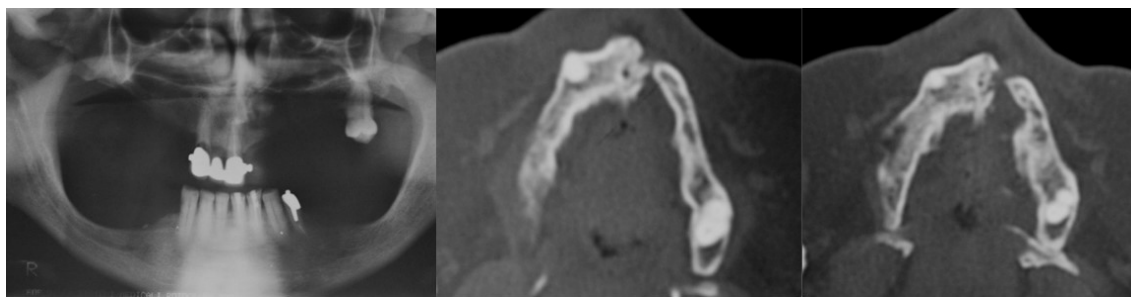


Fig:3 – Initial Orthopantomography and computed tomography with coronal sections

After full-thickness flap with bilateral identification of the infraorbital nerves, an osteotomy was performed to create a bone window to access the interior of the maxillary sinus. Maintenance of the relevant anatomical structures integrity and placement of the zygomatic implant in the ideal position for each clinical case are crucial. Zygomatic implants allowed to achieve an excellent primary stability as well as an adequate positioning for prosthetic rehabilitation. Final position of the 2 zygomatic implants placed in the posterior sector of the maxilla and the 4 standard axial implants placed in the anterior sector of the maxilla (Fig. 4).

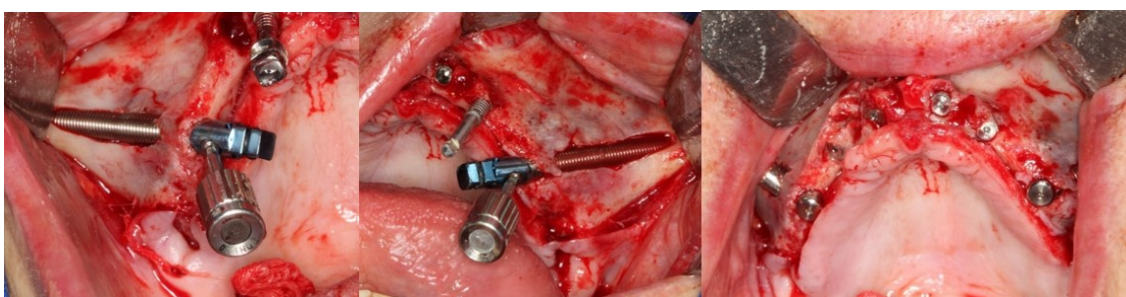


Fig. 4 – Intraoperative aspect of implants placement (S.I.N.-Implant System, São Paulo, Brazil)

After the period of bone consolidation, the preparation of the final prosthetic structures begins, it should be noted that the platform of the zygomatic implant is regular and compatible; it differs only in relation to the stabilization of the implants, which must be done through a rigid containment in passive adjusted structure that can be made of titanium as in this case or zirconia. This type of structure has a predictable and perfect fit at the abutment or implant level (Fig. 5).

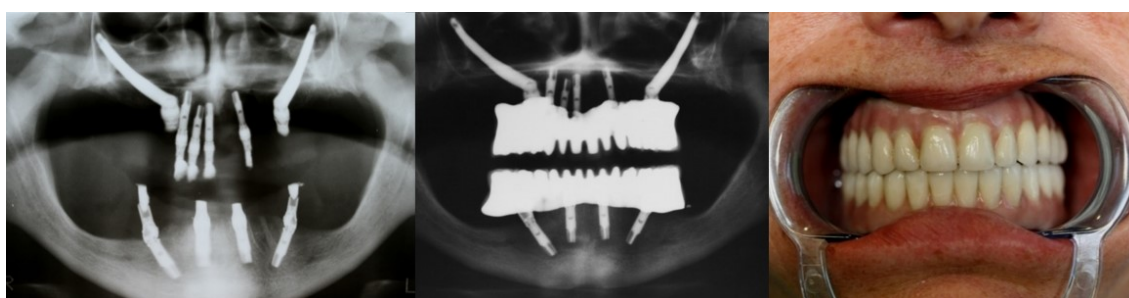


Fig: 5 – Final Orthopantomography and intra-oral aspect of final maxillary and mandibular rehabilitation

Complications

Peri and post-surgical complications are uncommon, prospective follow-up studies of patients between 6 months and 10 years after implant placement report success rates above 90% (7,19,20). The most prevalent complications are: sinusitis, peri-implant infection, implant dehiscence, perforation of the orbital floor, false path of the implant path, oro-sinusal fistula, neurological lesions (facial paresthesias), hygiene difficulties, dysarthria (usually resolved) with alteration of the prosthesis or use of speech therapy) and aesthetic dissatisfaction (18,19,20,21).

Conclusion

The development of the zygomatic implant occurred with the aim of rehabilitating patients with major facial mutilations, such as: hemimaxylectomy, tumor resection, trauma or birth defects. This procedure has been gaining an increasing number of indications, which include extensive maxillary resorption (mainly in the posterior sector), cleft palate, bone graft dehiscence or when this is contraindicated (7,8,19,20,22,23). The use of zygomatic implants should be considered a first-line technique in patients with low bone availability for orofacial rehabilitation.

Conflict of Interest

The author declares that there is no conflict of interest regarding the publication of this article.

References

- Allori A.C., Mulliken J.B., Meara J.G., Shusterman S., Marcus J.R., Classification of Cleft Lip/Palate: Then and Now. *Cleft Palate Craniofac J*, 2017 Mar;54(2):175-188.
- Sandham A., Classification of clefting deformity. *Early Hum Dev*, 1985 Oct;12(1):81
- Coleman Jr J.R., Sykes J.M., The embryology, classification, epidemiology, and genetics of facial clefting. *Facial Plast Surg Clin North Am*, 2001 Feb;9(1):1-13.
- Watkins S.E., Meyer R.E., Strauss R.P., Aylsworth A.S., Classification, epidemiology, and genetics of orofacial clefts. *Clin Plast Surg*, 2014 Apr;41(2):149-63.
- Tolarová M.M., Cervenka J., Classification and birth prevalence of orofacial clefts. *Am J Med Genet*, 1998 Jan 13;75(2):126-37.
- Rigolizzo M, Camilli J, Francischone C, Padovani C, Brånemark P-I., Zygomatic bone: anatomic bases for osseointegrated implant anchorage. *Int J Oral Maxillofac Implants*, 2005. 20(3):441-447.
- Ferrara E, Stella J., Restoration of the edentulous maxilla: The case for the zygomatic implants. *J Oral Maxillofac Surg*, 2004. 62:1418-1422.
- Malevez C, Daelemans P, Adriaessens P, Durdu F., Use of zygomatic implants to deal with resorbed posterior maxillae. *Periodontology*, 2003. 33:82-89.
- Kato Y., Kizu Y., Tonogi M., Ide Y., Yamane G., Internal structure of zygomatic bone related to zygomatic fixture. *J Oral Maxillofac Surg*, 2005. 63(9):1325-1329.
- Bedrossian, E., Stumpel L., Beckely M.L., Indresano T., The zygomatic implant: preliminary data on treatment of severely resorbed maxillae. A clinical report. *Int J Oral Maxillofac Implants*, 2002. 17(6):861-865.
- Malevez, C., Abarca M., Durdu F., Daelemans P., Clinical outcome of 103 consecutive zygomatic implants: a 6-48 months follow-up study. *Clin Oral Implants Res*, 2004. 15(1):18-22.
- Patel, R.R., Brook M.I., Wragg P.F., Zygoma implants or sinus augmentation and conventional implants? *Clin Oral Implants Res*, 2003. 14:
- Stevenson, A.R., Austin B.W., Zygomatic fixtures-the Sydney experience. *Ann R Australas Coll Dent Surg*, 2000. 15:337-339.
- Brånemark, P.I., Gröndahl K., Öhrnell L.O., Nilsson P., Petruson B., Svensson B., Engstrand P., Nannmark U., Zygoma fixture in the management of advanced atrophy of the maxilla: technique and long-term results. *Scand J Plast Reconstr Surg Hand Surg*, 2004. 38(2):70-85.
- Duarte F., Ramos C., Silva JN., Immediate function with four Zygomatic implants in patients with extreme maxillary atrophy – Case Series. *JSPIR* 2019; 1(2):51-55.
- Balshi T e Wolfinger G. (2002). Treatment of congenital ectodermal dysplasia with zygomatic implants: A case report. *Int J Oral Maxillofac Implants*, 17(2): 277-281.
- Bothur S, Jonsson G e Sandahl L. (2003). Modified technique using multiple zygomatic implants in reconstruction of atrophic maxilla: A technical note. *Int J Oral Maxillofac Implants*, 18(6): 902-904.
- Peñarrocha M, Uribe R, García B e Martí E. (2005). Zygomatic implants using the sinus slot technique: Clinical report of a patient series. *Int J Oral Maxillofac Implants*, 20(5): 788-792.
- Vrielinck L, Politis C, Schepers S, Pauwels M e Naert I. (2003). Image-based planning and clinical validation of zygoma and pterygoid implant placement in patients with severe bone atrophy using customized drill guides. Preliminary results from prospective clinical follow-up study. *Int. J. Oral Maxillofac. Surg.*, 32: 7-14.
- Malevez C, Abarca M, Durdu F e Daelemans P. (2004). Clinical outcome of 103 consecutive zygomatic implants: a 6-48 months follow-up study. *Clin. Oral Impl. Res.*, 15: 18-22.
- Al-Nawas B, Wegener J, Bender C e Wagner W. (2004). Critical soft tissue parameters of the zygomatic implant. *J Clin Periodontol*, 31: 497-500.
- Pham A, Abarca M, Mey A e Malevez C. (2004). Rehabilitation of a patient with cleft lip and palate with an extremely edentulous atrophied posterior maxilla using zygomatic implants: Case report. *Cleft Palate-Craniofacial journal*, 41(5): 571-574.

23. Nakai H, Okazaki Y e Ueda M. (2003). Clinical application of zygomatic implants for rehabilitation of severely resorbed maxilla: A clinical report. *Int J Oral Maxillofac Implants*, 18(4): 566-570.

Citation: Duarte F, Ramos C and Silva JN. “Unilateral Cleft Palate Rehabilitated with Zygomatic Implants–Case Report”. *SVOA Dentistry* 2:4 (2021) Pages 119-125.

Copyright: © 2021 All rights reserved by Fernando Duarte et al. This is an open access article distributed under the Creative Commons Attribution License, which permits unrestricted use, distribution, and reproduction in any medium, provided the original work is properly cited.