

Pulp Survival in Multirooted Teeth After Accidental Apicectomy of One Root: A Case Report

Otmar M.E. Wikkeling, DMD, MD, Life fellow of the IAOMS*

Stichting Ormaxfa, Jan van Scorelstraat 150, 3583 CV Utrecht, The Netherlands.

***Corresponding Author:** Dr. Otmar M.E. Wikkeling, DMD, MD, Life fellow of the IAOMS, Stichting Ormaxfa, Jan van Scorelstraat 150, 3583 CV Utrecht, The Netherlands.

Received: January 24, 2022 **Published:** February 16, 2022

Abstract

As early as the 1970s it was shown in animal experiments that the pulp of a multi-root tooth can survive if, without further therapeutic measures, an apex resection of one of the roots is performed. It is unethical to conduct such tests on humans. This article reports on the possible outcome in human pulp survival after accidental resection of one root in a multirooted tooth. There is also an example of survival of the pulp of a single root tooth after accidental lesion of the apex.

Keywords: Surgery, Oral, Apicectomy, Tooth-vitality, Pulp-survival

Preface

In the early eighties I was employed at the Dental Institute of the State University in Utrecht the Netherlands as a "wetenschappelijk hoofdmedewerker" (associate professor). During that period, this contribution was prepared for publication. At the same time, preparations were made for the liquidation of this institute. The manuscript that was then ready, fell out of sight and was recently found again. With some minor adjustments, the original paper is now being published.

Introduction

Egyedi and Visser (1973) ⁽¹⁾ demonstrated pulp-survival in cats after deliberately cutting of one apex in a multirooted tooth under sterile conditions. In a similar experiment the recovery of pulps in multirooted dogteeth was reported by Waldhart and Linares (1972) ⁽²⁾.

It was shown ⁽¹⁾, ⁽²⁾ that regeneration of pulps in cats and dogs was fast and uneventful.

In September 1978 a 37 year old Caucasian woman visited our clinic (patient A). Her dentist had persuaded her to undergo an apicectomy in tooth no. 25 for an apical radiolucency he happened to find by accident on a routine X-ray photograph. The patient was unaware of her anomaly since she had no clinical signs or complaints originating from 25 or surroundings.

The lady was operated on by one of our junior staff-members. After closing the wound, the doctor had an intra-oral control-radiograph made and now it became evident that he had accidentally treated the mesio-buccal root of 26 instead of 25.

Cognizant of the papers just mentioned ⁽¹⁾, ⁽²⁾ and facing the fact that the patient was reluctant to have the 25 treated at the time, we decided to wait and see what was going to happen.

In the days to follow the patient suffered excruciating pain and so the pulp-chamber of tooth no. 26 was opened, and a root-canal treatment was performed (Dr. A. Taeed, Endodontic Department, State University, Utrecht). From then on recovery was uneventful.

Case Report

The present case concerns a 35 year old Caucasian female (Patient B). The patient was referred by her dentist to have her impacted, upper left cuspid removed because the dentist was planning a complete dental rehabilitation.

The operation was performed on March 29, 1980, in local anaesthesia. It took us over 30 minutes to remove the 23 and we had to approach from the buccal as well as from the palatal aspects. At the end of the operation, it appeared that the 24 was accidentally apicectomized.

An instant intra-oral X-ray picture revealed 2 roots, of which one was severed. We decided to conduct a retrograde root filling of the severed root of tooth no. 24. The post-operative pain was endurable (the patient did not use the prescribed analgesics) and recovery was uneventful.

At a 7-months recall the 24 reacted normally to vitality tests and an X-ray film revealed a radiologic normal periodontal membrane.

Discussion

In our opinion there is no justification to repeat the experiments of Egyedi and Visser (1) and Waldhart and Lenares (2) on human beings. In addition to pure extrapolation one can learn from accidents as recorded here.

The patient described in the introduction (patient A) suffered severe pains after apicectomy and retrograde amalgam filling of one root in a multirooted vital tooth. There upon endodontic treatment was done and no micro-organisms could be cultured from the pulp in question, so we assume the pulp was sterile.

Our endodontic department does not routinely perform histologic examination and so, as we realized this too late, we missed that opportunity. After completing the endodontic treatment, the patient had no pain and refused the originally planned operation in 25.

Today the patient is still free from pain and reluctant to be operated.

Conclusion

Knowing that neither the cats (1) nor the dogs (2) did complain, we waited impatiently for the next event of this kind in the treatment of humans.

Even in a university clinic like ours one does not come across an accidentally apicetomized root of a vital, multi-rooted tooth very often, so we carefully recorded the case presented here (Patient B) hoping more or less, to get the opportunity this time for histological examination, but what happened this time (uneventful healing) seems to be in complete concordance with the outcome of the experiments of Egyedi and Visser (1) and Waldhart and Lenares(2).

Summary

In oral-surgery procedures sometimes an apex of a tooth adjacent to the surgical site, is cut accidentally. It was shown before in animal studies that healthy pulps in multi-rooted teeth could survive.

The present case is the recording of such an event in a human upper first bicuspid. (Patient B)

Fazit

The unintended delay of publication also has an advantage in retrospect. In December 2016, during an apicectomy procedure 34 the apex of 33 was accidentally severely damaged (Fig 1), (Patient C). The postoperative course was uneventful.

At follow up one year later, the patient had no subjective complaints and complete recovery had occurred periapical 33 and the usual tests show a vital pulp 33. Fig. 2 is the situation five years after the event.

We have not yet been able to persuade the patient to have the 34 retreated.

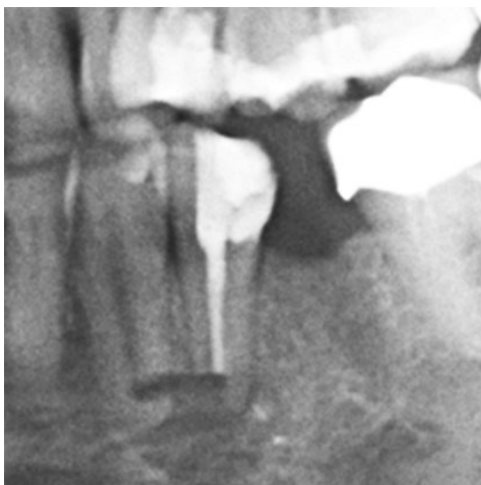


Fig. 1: Patient C: Post apicectomy 34 with accidental damage of root 33

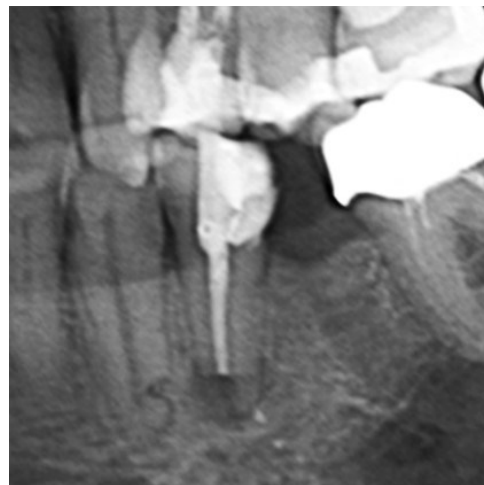

Fig. 2: X-ray five years after damage: recovery of root 33

Conclusion: There is a chance of recovery in case of unintended severe apical damage to single rooted teeth.

Acknowledgements

We extend our thanks to Dr. A. Taeed for his help in the treatment of patient A.

References

1. EGYEDI, P. and VISSER, J. (1973) Pulp vitality of Multirooted Teeth after Injury to one root. *Journal of Maxillo-Facial Surgery* 1; 207-208.
2. WALDHART, E. and LINARES, H.A. (1972) Zur Frage der Regenerationsfähigkeit der Odontoblasten. *Deutsche Zeitschrift für Zahn-Mund- und Kieferheilkunde* 58; 10-17.

Citation: Wikkeling OME. "Pulp Survival in Multirooted Teeth After Accidental Apicectomy of One Root: A Case Report". *SVOA Dentistry* 3:2 (2022) Pages 60-62.

Copyright: © 2022 All rights reserved by Wikkeling OME., et al. This is an open access article distributed under the Creative Commons Attribution License, which permits unrestricted use, distribution, and reproduction in any medium, provided the original work is properly cited.