

Digital Workflow for Fully Guided Full-Arch Implant Reconstruction

Tarek Assi*

Alpha Dental Practice & Implant Center, USA

*Corresponding Author: Tarek Assi, Alpha Dental Practice & Implant Center, USA.

DOI: <https://doi.org/10.58624/SVOADE.2023.04.0121>

Received: February 21, 2023 Published: March 02, 2023

Abstract

A large portion of the US population today is edentulous. It is estimated that over 23 million individuals are completely edentulous and 12 million are edentulous in one arch. In addition to that, we have a growing population with terminal dentition conditions. Traditionally, these patients were treated with staged implant placement and delayed loading. Such traditional approach requires multiple surgeries and longer treatment time. Consequently, the traditional treatment approach is associated with increased morbidity and longer healing periods. Utilizing this Digital workflow for implant reconstruction to treat patients with terminal dentition and those who are fully edentulous will significantly increase predictability, precision, and reduce treatment chair side time which overall increases patient satisfaction.

Keywords: Digital Workflow, Implant reconstruction, Full-Arch Implant Reconstruction, edentulous.

Learning Objectives

- Describe the digital workflow for fully guided full-arch implant surgery, immediate provisional loading, and final prosthesis.
- Discuss the benefits of applying the digital workflow vs. conventional workflow.
- Summarize treatment options for terminal dentition and fully edentulous patients.

Case Report

A 59-year-old female presented to our practice for implant consultation. Her concern was her inability to function properly and very poor esthetics. Based on clinical and radiographic evaluation, it was determined that she has terminal dentition and will be treated accordingly.

The treatment that was suggested to the patient included the removal of all remaining teeth, followed by teeth replacement. Options for teeth replacement were discussed as, implant supported fixed prosthesis, implant supported removable prosthesis, implant retained- tissue supported removable prosthesis, conventional denture, or do nothing. She decided to move forward with an implant supported fixed prosthesis for both Arches.

Digital Records

The digital records required for this case consisted of a series of frontal and profile photographs of the patient, a bite registration, a cone beam computed tomography (CBCT) taken with the bite registration in place and according to desired occlusal vertical dimension (OVD), a digital impression of existing dentition in standard triangle language (STL) format. All of which were submitted to a digital lab for virtual planning session once all digital data put together.

Digital Workflow

Step One: Digital Records

Step Two: Digital Planning

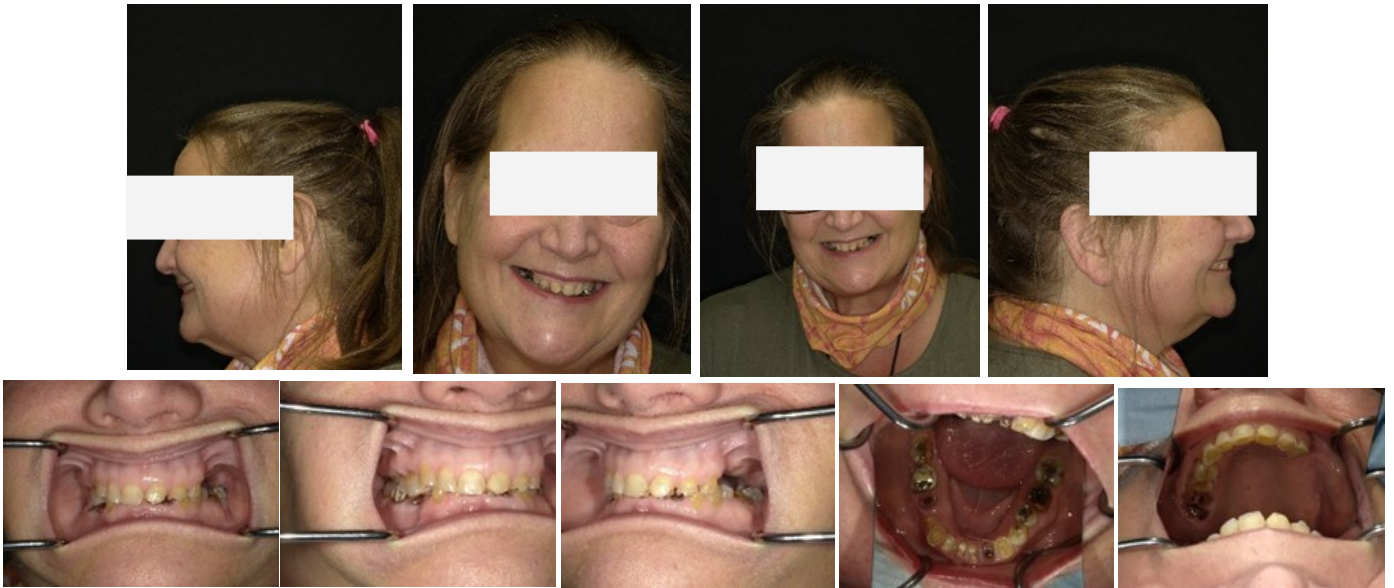*****Surgery & Immediate Load*****

Step One: Bite & Tissue Impression

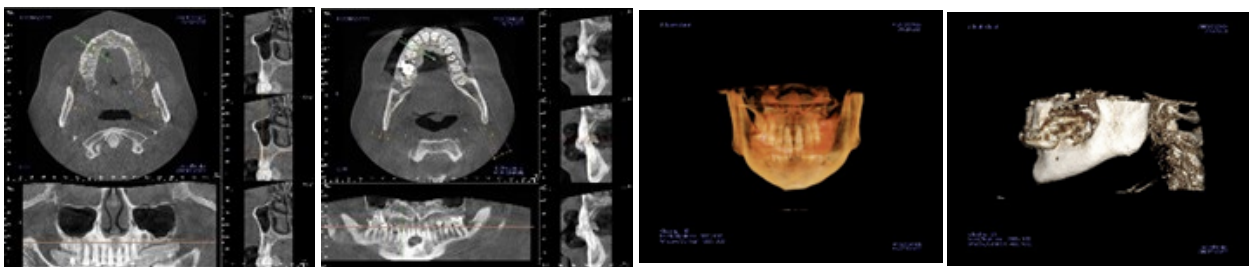
Step Two: Try in

***** Delivery Final Prosthesis*****

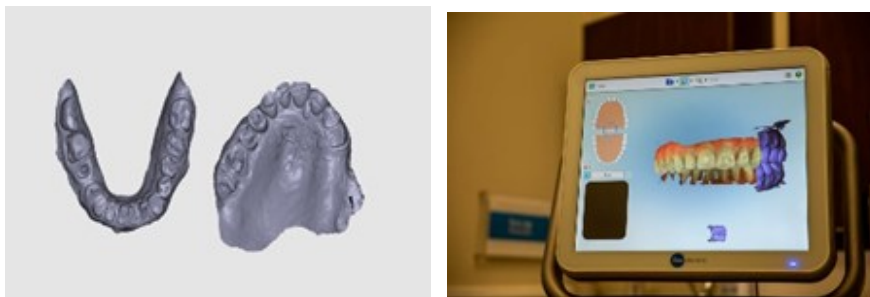Digital Data



Pre-op photos



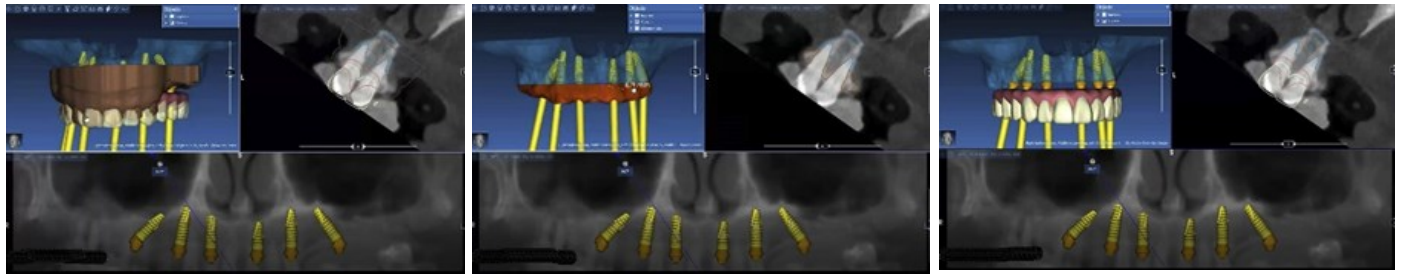
Pre-op CBCT



Digital Impressions

Digital Planning

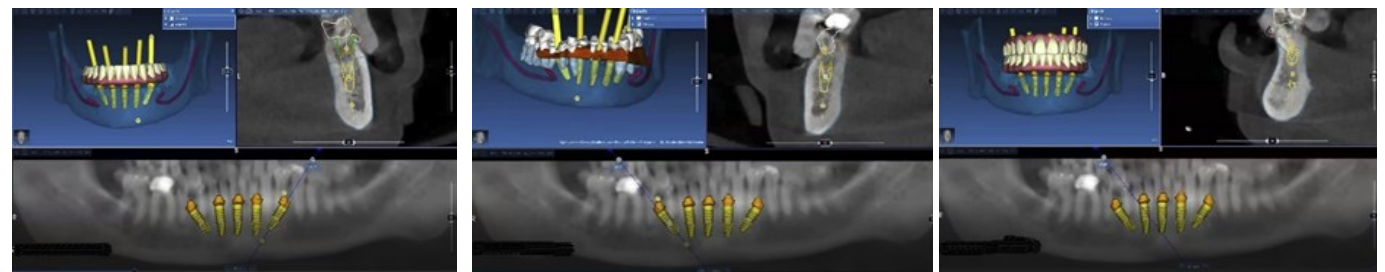
At the virtual meeting we reviewed the digital data merged together in the planning software. Starting with the end in mind, we determined the teeth position starting with the incisal edge. Then, we determined the amount of bone reduction required to allow proper restorative space and to hide the transitional line. Then the number, position and distribution of implants were planned, and the multi-unit abutments (MUAs) angulations and collar heights were selected accordingly to allow proper path of insertion. According to our plan, the digital lab fabricated multiple guides to assist us performing the surgery exactly as planned.



*Digital Planning Teeth Position
Implant Position*

Digital Planning Bone Reduction

Digital Planning



*Digital Planning Teeth Position
Implant Position*

Digital Planning Bone Reduction

Digital Planning

Surgery and Immediate Provisional Loading

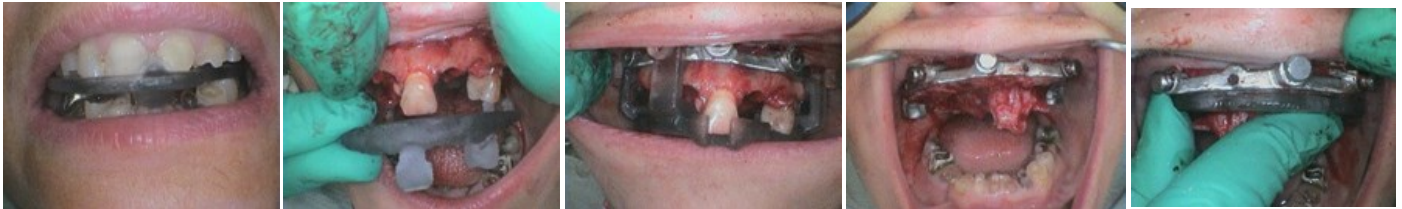We started by placing the start bite in the patient's mouth to verify her bite. The start bite is a 3D printed bite according to which all the stackable guides were fabricated. So, confirming the accuracy of the start bite is confirming that all guides will fit properly as planned including the Provisionals. Once profound anesthesia was achieved, all upper teeth were extracted except for two teeth. Soft tissue was reflected beyond the bone foundation guide (BFG) seating line. Once the (BFG) was seated properly as a tooth-bone supported guide, it was fixated in place with three pins. Then the two teeth, we choose to preserve to support the guide while being seated, were extracted. Bone reduction was performed to the level of the (BFG). Bone reduction could be achieved using surgical bur, Piezo surgery, Rongeur, or surgical saw. Once the bone was reduced, we placed the bone reduction verification guide to confirm bone reduction was done as planned. Then the implant guide was seated on the (BFG) and implant drilling sequence protocol followed according to manufacturer recommendations. Then implants were placed following the implant timing indicated on the implant guide to ensure proper position. Based on implant insertion torque values and implant stability quotient (ISQ) values it was determined to proceed with immediate loading. The implant surgical guide was removed and a bone profiler was used around implants to ensure that the multi-unit abutments (MUAs) seated completely. Then, the angle rotation guide was seated and (MUAs) were seated in place accordingly and torqued to recommended torque value. Temporary cylinders were seated on (MUAs) one by one and path of insertion was checked each time by placing the long term provisional (LTP) in and out. Then, the gasket and plastic block-out plugs were placed to ensure proper isolation. The long term provisional (LTP) was seated and fixated to the (BFG). By using dual cure (self-cure/light cure) material the temporary cylinders were secured into the (LTP). The same steps were repeated to lute the duplicate (LTP). Then (BFG) was removed. Healing caps over (MUAs) were placed during closure. Sharp bone edges were smoothed and surgical site was grafted as necessary. Soft tissues were trimmed to remove excess tissue as a result of bone reduction keeping in mind to preserve sufficient keratinized and non-mobile soft tissue around the implants for better long-term prognosis. L-PRF (Platelet Rich Fibrin) was utilized to enhance soft tissue healing. The closure around healing caps was achieved with combination of horizontal and vertical internal mattress using 4-0 and 5-0 monofilament absorbable sutures. The same steps were followed for the opposing arch.

Once the maxillary and mandible (LTP)s were finished and polished, they were seated in place and occlusion was evaluated and adjusted accordingly. Post-op instruction and home care were reviewed with patient. By the end of this session, patient was discharged with (LTP)s in place and the procedure was performed exactly as planned at the digital planning session.

Follow ups:

Patient was seen 2 days after surgery, then 2 weeks, 2 months, and 4 months. Each follow up visit we evaluated the healing, irrigated surgical sites with saline water, and checked occlusion.

Surgery and Immediate Loading

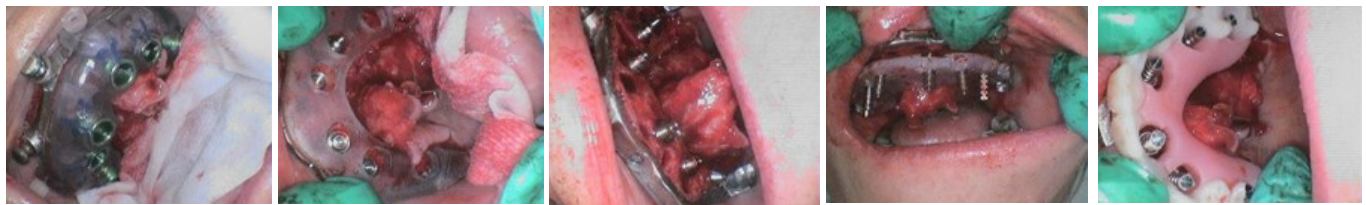

*Start Bite Verify
Bone Reduction*

Leaving 2 Teeth

Teeth Supported Guide

Bone Reduction

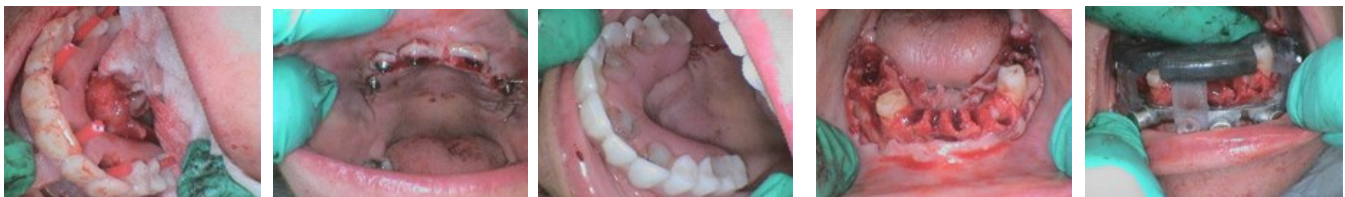

Implant Guide PMMA

MUA Guide

MUA's

Provisional Sleeves

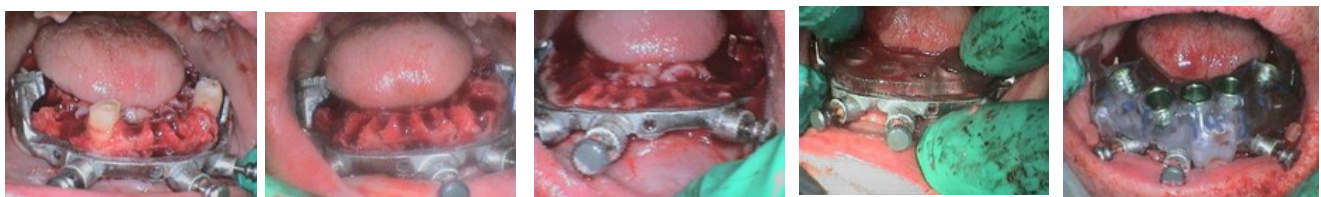

*Block out for Pick up
Teeth supported
Guide*

Closure

PMMA delivered

Leaving 2 Teeth

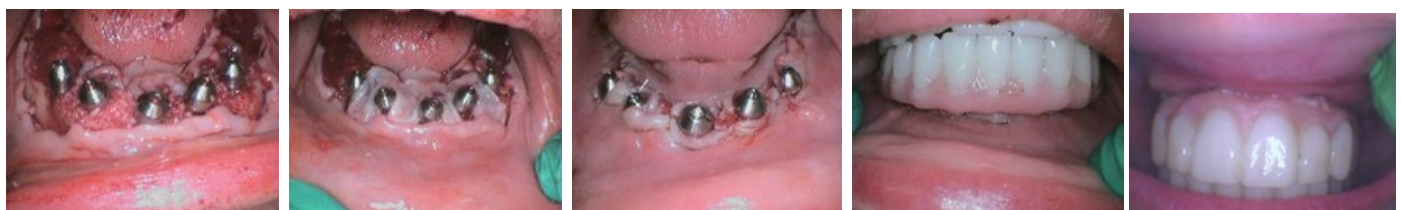

*BFG in Place
Implant Guide*

Pre Bone Reduction

Post Bone Reduction

Verify Bone Reduction



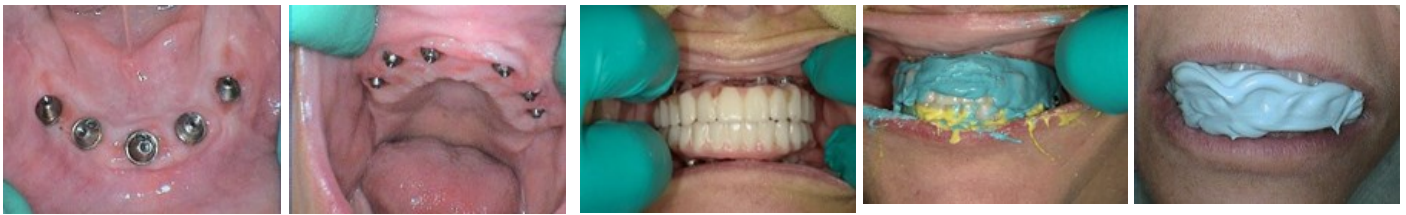*Bone Grafting
PMMA Place*

L-PRF

Closure

PMMA in Place

Final Impression & Bite & Try in

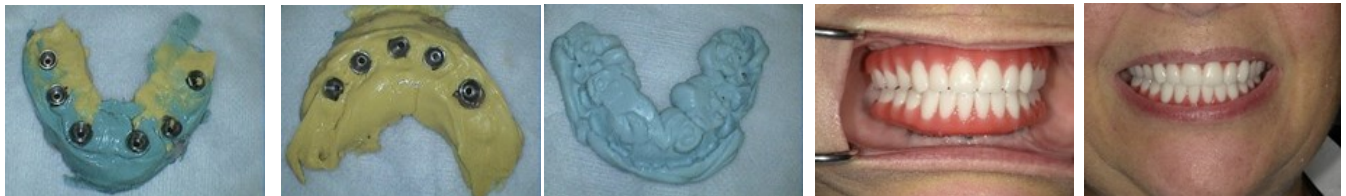

4 Months Upper and Lower Bite Registration

PMMA both Removed

Duplicate PMMA in place

VPS to capture gap



Upper Duplicate PMMA Try in

Lower Duplicate PMMA

Bite Registration

Try in

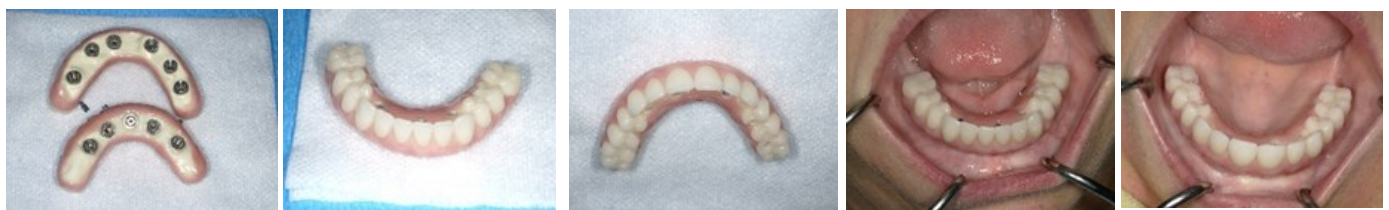Definitive Restoration

After a 5-month period of healing, the (LTP)s were removed and the duplicate (LTP)s were placed. The space between the soft tissue and the intaglio surface was captured by injecting polyvinyl siloxane (PVS) material underneath the duplicate (LTP). Both duplicate (LTP)s were submitted to the lab along with bite registration to have the teeth set up fabricated for try-in. Once esthetics, phonetics, and function were confirmed at the try-in visit, the case was sent back to lab for production. At delivery visit (LTP)s were removed and definitive prostheses were seated. Screw access holes were closed with Teflon tape and composite. Occlusion was evaluated and adjusted according to implant mutual protected occlusal scheme. An occlusal guard was fabricated and delivered.

Follow ups:

Patient was seen for a follow-up to evaluate occlusion and patient's function at one week and at one month. Then, three-month implant maintenance sessions were implemented.

Final Prosthesis Delivery

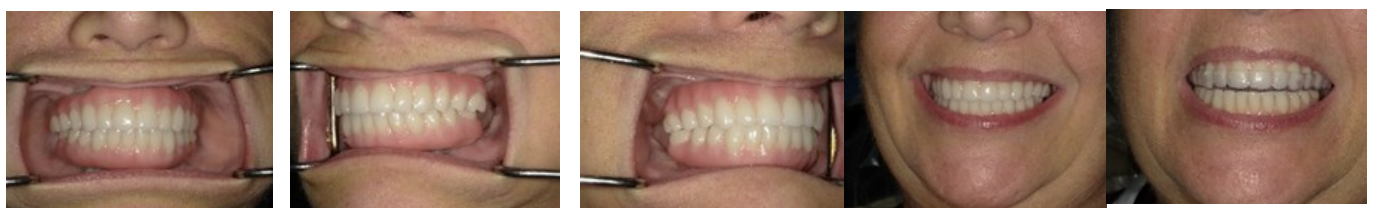

Final Prosthesis Final Upper Prosthesis

Lower Nano Ceramic

Upper Nano Ceramic

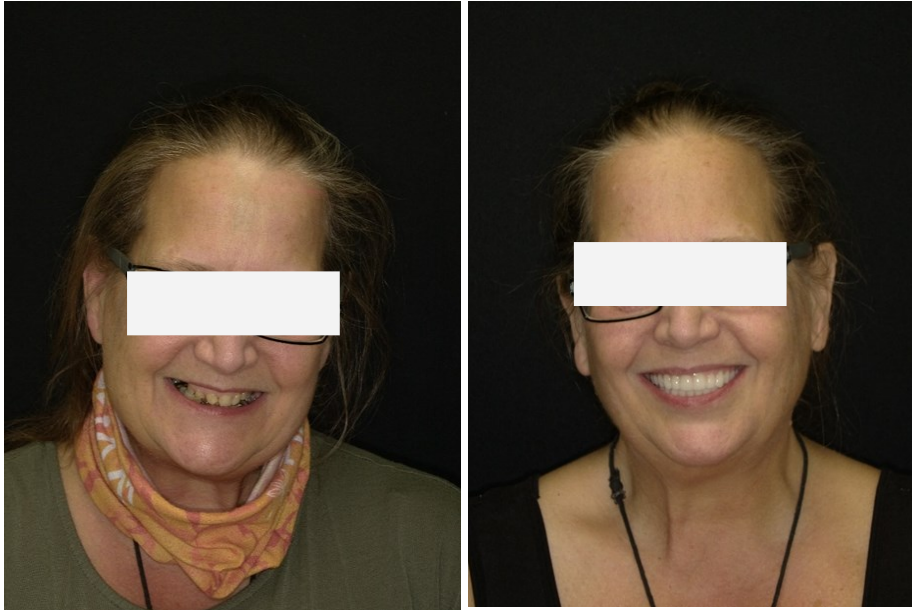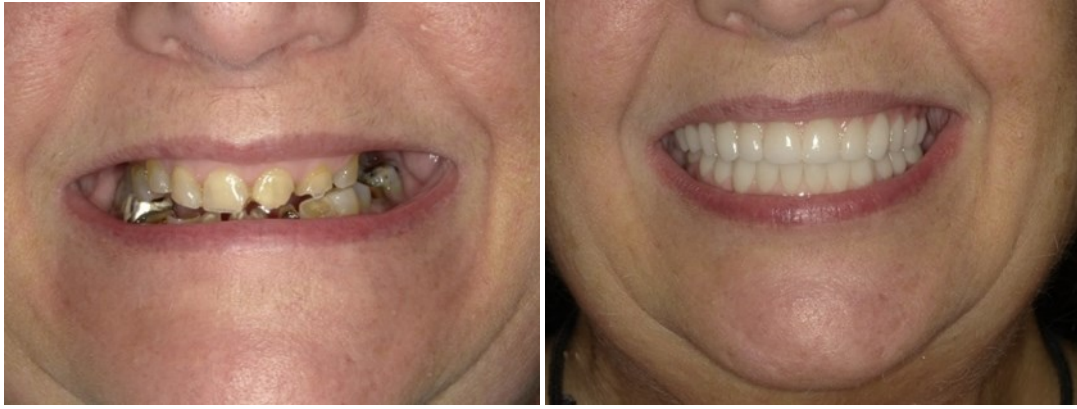Final Lower Prosthesis



Final Prosthesis Occlusal Guard

Final Prosthesis

Before & After



Before

After

Conclusion

Following this digital workflow and prosthetic-driven implant placement for full arch implant reconstruction will help clinicians be more efficient and provide higher precision and more predictable outcome. Utilizing stackable guides allows, not only bone reduction and implant placement to be guided, but also multi-unit abutments (MUAs) placement and (LTP) long term provisional loading to be done guided as well. Additionally, this allows us to reduce chair-side time and overall treatment time. Also, reduce morbidity, improve post op healing experience, and increase patient satisfaction.

Conflict of Interest

The author declare no conflict of interest.

References

1. Terrence J. Griffin, J Periodontal 2006;77:2070-2079
2. Brunski, BJ Skalk, R 1992; Pilar RM1995
3. Leora Walter, Gary Greenstein. The Journal of the American Dental Association, Vol. 151, Issue 10, P790-795 Published in issue: 2020
4. Uta Scherer, Marcus Stoetzer, Martin Ruecher, Nils-Claudius Gellrich Constantin von See Clin Oral Investig, 2015 July; 19(6):1339-46. Doi: 10.1007/500784-014-1346-7. Epub 2014 Oct 30.
5. Briec Hanozin, Lou Li Manni, Geoffrey Lecloux, Miljana Bacevic, France Lambert
6. Int J Implant Dent. 2022 FEP 7; 8(1):7. 10.1186/s40729-022-00406-6.
7. Jacques Vermeulen. Int J Oral Maxillofac Implants. Mar/Apr 2017;32(3):617-624. doi:10.11607/jomi.5065. Epub 2016 Oct 14.

8. Matteo Capelli, Francesco Zuffetti, Massimo Del Fabbro, Tiziano Testori
9. Int J Oral Maxillofac Implants. July-Aug 2007; 22(4):639-44.
10. German O Gallucci, Jean-Pierre Bernard, Michel Bertosa, Urs C Belser
11. Int J Oral Maxillofac Implants. Jul-Aug 2004; 19(4):524-33.
12. Othman Shibly, Ahmad Kuthut, Nishith Patel, Jasim M Albandar. Clin Implant Dent Relat Res. 2012 Oct; 14(5):663-71. Doi: 10.1111/j.1708-8208.2010.00310.x. Epub 2010 Oct 26.
13. Chee W, Jivraj S. Clin Impl Dent. Vol 5 No.1 2003: p.52-56
14. From Misch CE: *Bone classification training keys. Dent Today* 8:39-44,1989

Citation: Assi T. Digital Workflow for Fully Guided Full-Arch Implant Reconstruction. *SVOA Dentistry* 2023, 4:2, 20-26.

Copyright: © 2023 All rights reserved by Assi T., et al. This is an open access article distributed under the Creative Commons Attribution License, which permits unrestricted use, distribution, and reproduction in any medium, provided the original work is properly cited.