

# Full Oral Rehabilitation - Quad Zygoma with Extra-Sinusal Implants Placement Technique with Pterygoid Implants and Four Traditional Implants in The Lower Jaw with Immediate Loading: A Case Report

Ruggero Leoncavallo\*

Implantologist at VL Dental, Santena, Turin, Italy.

\*Corresponding Author: Dr. Ruggero Leoncavallo, Implantologist at VL Dental, Santena, Turin, Italy.

DOI: <https://doi.org/10.58624/SVOADE.2023.04.0137>

Received: May 27, 2023 Published: July 10, 2023

## Abstract

Today it is more and more frequent to find ourselves faced with severe atrophy of the upper jaw due to bone defects of various kinds, physiological, pathological and iatrogenic. With the help of extraoral bone anchorage it is possible to solve those cases that cannot be solved with traditional implantology. Zygomatic implantology can manage these types of atrophies by rehabilitating the patient with a fixed prosthesis and, where possible, with immediate loading. These solutions represent an alternative to bone grafts (graftless solutions) which provide for much longer healing times and with patient discomfort given the contraindication to immediate loading. The same goes for the lower arch which involves rehabilitation with a low number of implants, two of which tilted to avoid noble anatomical structures such as mental nerves in order to reach the posterior areas (premolar area) minimizing the prosthetic cantilever. I present a clinical case where through the use of zygomatic and pterygoid implants for the upper jaw and four lower implants it was possible to restore function and aesthetics by installing two screw-retained temporary fixed prostheses.

**Keywords:** Zygomatic implants, pterygoid implants, oral surgery, graftless solutions, immediate loading, tilted implants

## Introduction

Since the early 80's P.I. Branemark began studying alternative bone anchorages in order to solve severe atrophies of the upper jaw in order to rehabilitate those patients in whom it was not possible to do it with traditional implantology following the classic protocol he always created of Toronto bridge with 5-6 interforaminal axial implants in mandible or in the area of the pre-maxilla in the upper arch. This approach favored the number of implants over the distribution.

By virtue of this, in the early 2000s Dr. Paulo Malò presented the All-on-4®<sup>[1]</sup> technique which involves the use of four implants, two axial and two distal inclined, avoiding anatomical structures such as the emergence of mental nerves or maxillary sinuses hyper-pneumatized in such a way as to be able to widen the implant polygon thus minimizing the prosthetic cantilever.

The big news was the advent of immediate loading rehabilitation, that is, the insertion of a fixed provisional screwed prosthesis a few hours after surgery. In addition to giving mechanical benefits, i.e. the splinting of the implants from the day of the surgery, it also increases compliance by patients who tend to refuse long therapies, preferring more and more fixed-type solutions with immediate function, thus reducing the need to wear a temporary mobile prosthesis for several months [2]. [3].

A further step forward has been made with zygomatic implantology as thanks to the use of longer implants (up to 60mm) it is possible to reach portions of basal bone such as the zygomatic bone.

To date there are different techniques to be able to insert zygomatic implants, ie extrasinusal and intrasinusal. The first involves the detachment and, as far as possible, the preservation of the Schneider membrane and the creation of a slot along the external body of the maxillary bone in which the implant will then be housed [4], [5].

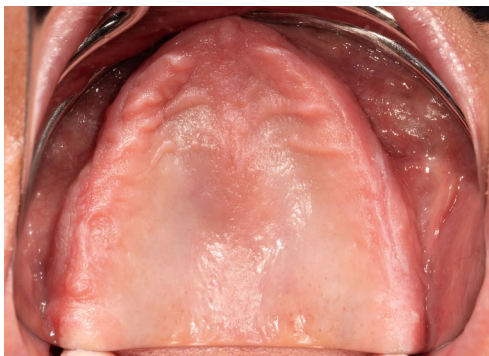Using an implant with internal connection, it is possible to deepen the implant in such a way as to vestibularize the prosthetic hole, considerably reducing the thickness of the prosthesis, as long as there is a basal bone support at the level of the implant neck to avoid bending movements.

In the intrasinusal technique, which provides for a more palatal starting point, the thickness of the prosthesis would be wider and therefore an invasion of the palate is created which would be uncomfortable for the patient during swallowing and phonics.

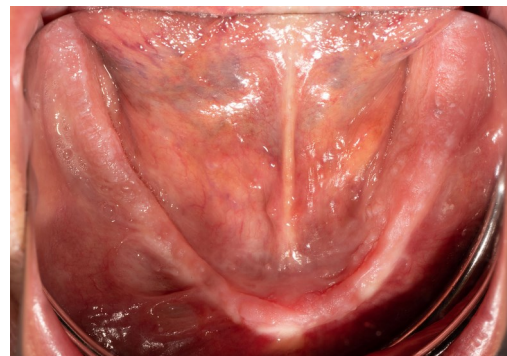
It is also clear that you have to choose which technique to intervene with also according to the patient's anatomy. An important classification was made by C. Aparicio, ZAGA classification which relates the position of the bone crest to the zygomatic bone [6], [7]. In a ZAGA IV class you can proceed with extrasinus technique, while in a ZAGA class I, II, III you can proceed with the extrasinus technique making a slot as described above or intrasinusal. [5]

## Case Report

67-year-old female has been visiting with complete edentulism and has been wearing removable prostheses for many years. After a careful radiological examination with orthopantomography and CT cone beam, a marked atrophy of the upper and lower jaw is highlighted.



*Initial situation - Upper jaw*



*Initial situation - Lower jaw*

The solution is envisaged with bone grafts, such as large right and left maxillary sinus lift and nasal cavity lift in order to insert 6 implants. However, this solution provided for healing / osseointegration times of about 12-15 months. As the patient was tired of wearing removable prostheses, her request was that of a graftless solution with considerably shorter times.

Therefore I decide to proceed with the planning of four zygomatic implants (JDentalCare Zygoma ONE Ø3.9) and two pterygoid implants in the upper arch and four lower implants, all with immediate load if the bone during the intervention had allowed a primary stability of at least 35 N / cm.

The surgery is performed in an anxiolysis regime (intravenous conscious sedation).

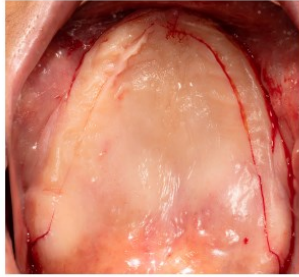
It begins with a deep anesthesia of the upper jaw with Mepivacaine 2% with adrenaline 1: 100,000 in the infratemporal fossa, tronculars of both infraorbital nerves, subperiosteal in the vestibular areas of the maxilla to facilitate elevation flap maneuvers, major palatine nerves, nasopalatine and on the entire palatal perimeter.

In addition, external skin anesthesia was performed with Mepivacaine 2% without adrenaline in the area of the right and left zygomatic bones.

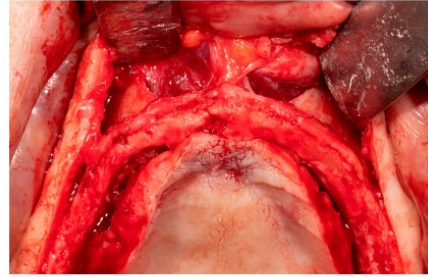
A crestal-palatal incision is made to try to move as much keratinized tissue as possible to the vestibular side with two distal discharge cuts on the pterygoid process and one on the midline.

It is essential to ensure around the body of the zygomatic implants that will be located with an extramaxillary path an excellent seal to implant with a good quality of the soft tissues to avoid complications [8] such as the dehiscence of the implant body.

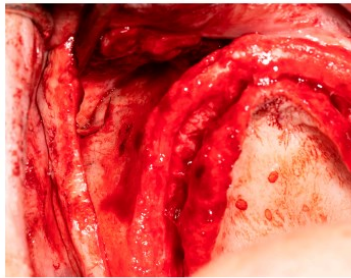
After a full thickness detachment, the nasal cavities and infraorbital nerves are isolated and then the zygomatic bone is isolated until the masseter muscle fibers are visualized.



*Flap design*

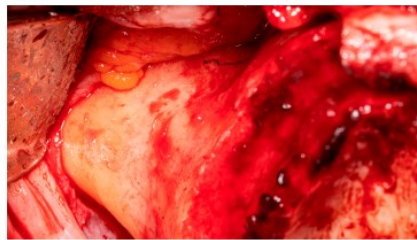

*Isolation of nasal cavities*

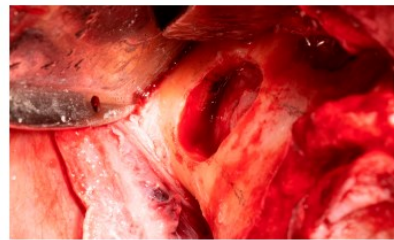


*Isolation of infraorbital nerve*

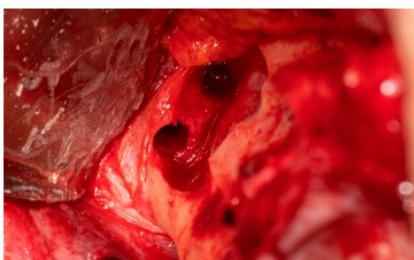
A window is made in order to detach the Schneider membrane and visualize the area of the zygomatic bone where the implant osteotomies will be made.



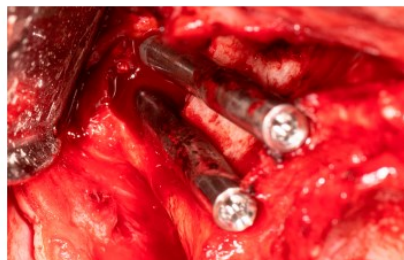
*Zygomatic bone*



*Window on the zygomatic bone*

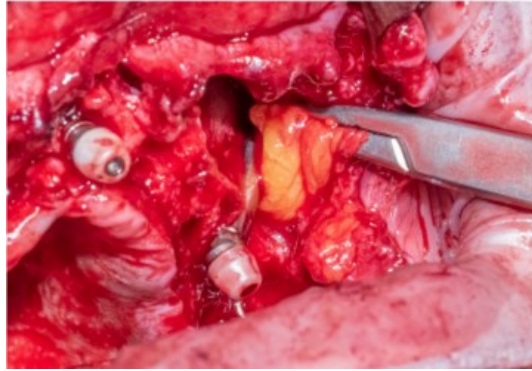


*Implants osteotomies*



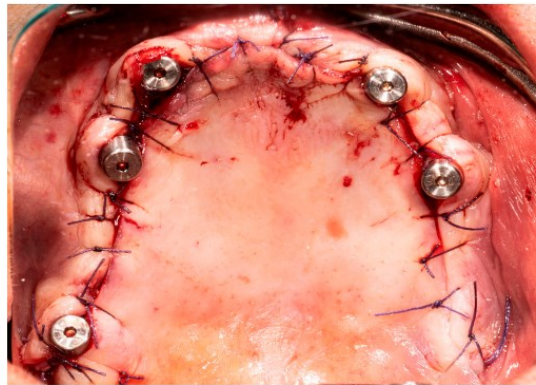
*Inserted implants*

If the membrane should have small perforations there are no problems, if it should instead have large perforations so as to be able to create possible oral antral communications it is preferable to proceed with the herniation of the buccal fat pad (Bichat's fat pad) in order to increase and improve the histology of soft tissues by reducing the risk of exposure of the implant body and to avoid possible oro-antral communication [9], [10].

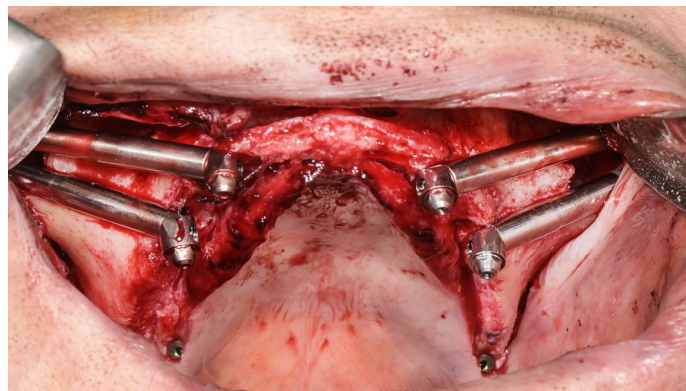


*Herniation of the Bichat fat pad (image of another clinical case of mine because in the case in question it was not necessary to take out both buccal fat pads due to the presence of good keratinized tissue).*

We proceed with the drilling protocol by completely perforating the external cortical of the zygomatic bone in order to be sure of avoiding important structures such as the orbital cavity and thus reaching a fundamental bicorticalism for obtaining a primary stability that therefore allows immediate loading.



Once the four osteomies have been prepared, we proceed with the insertion of the zygomatic implants.

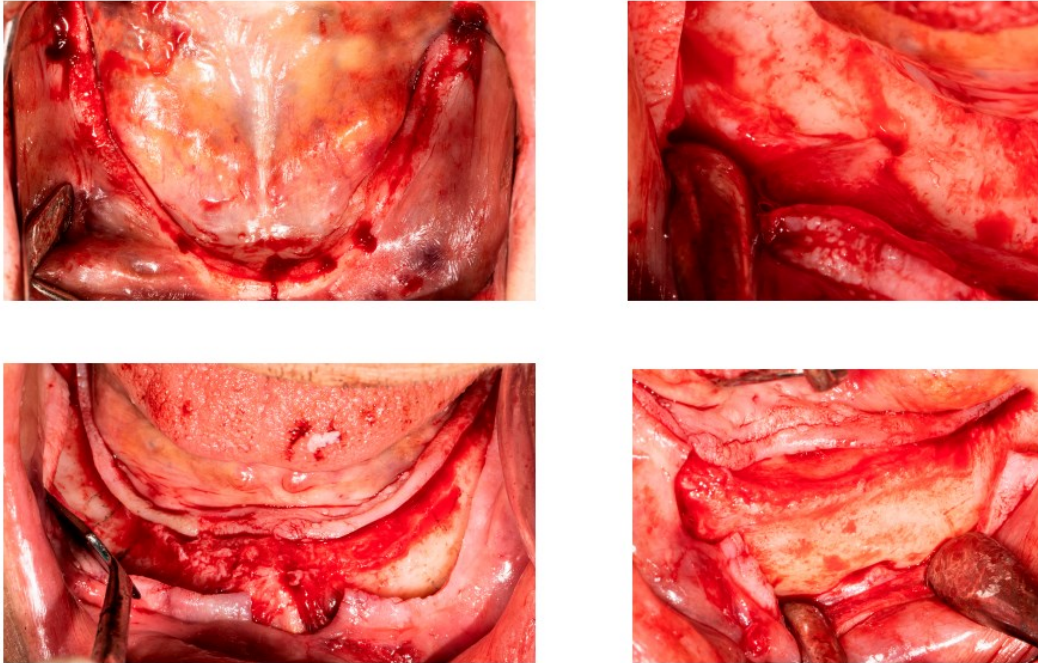


The pterygoid implants are inserted in the tuberal area, reaching with the apex the pterygoid bone between the internal and external lamina where the bone quality is better than the tuber itself.

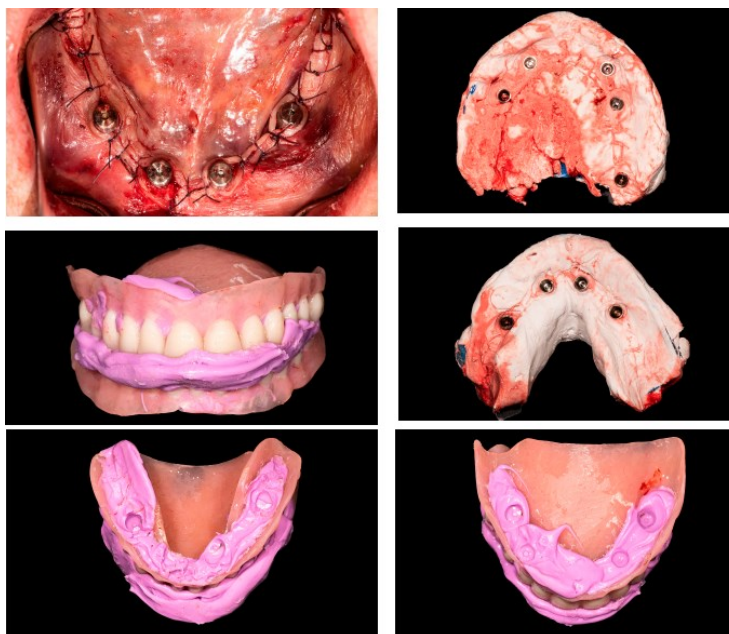The four zygomatic implants and the right pterygoid implant reached a suitable torque to be able to proceed with immediate loading, while the left one had a torque of 15-20 N / cm therefore it was decided to follow a conventional loading protocol for this implant submerging it.

In the lower arch, on the other hand, we proceeded tilting two distal implants in order to increase the extension of the implant polygon while minimizing the prosthetic cantilever.

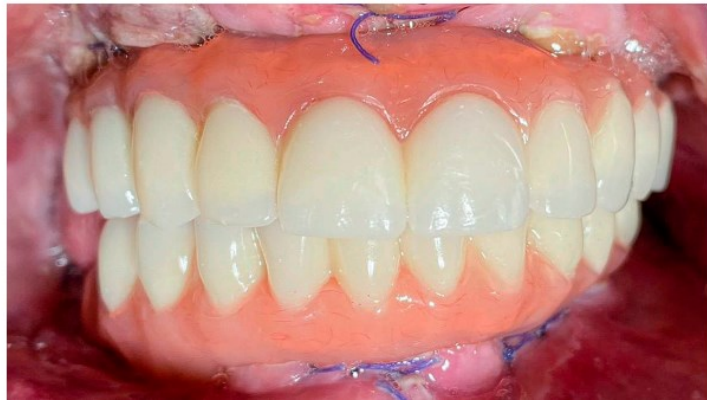
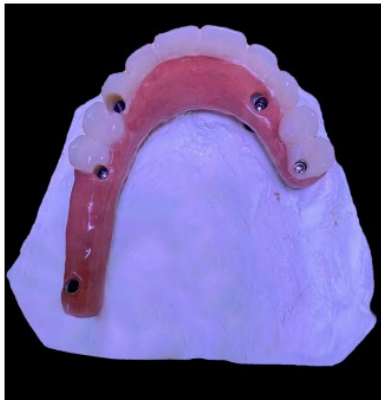Both mental nerves were isolated in order to proceed in total safety, avoiding any risk of paresthesia caused by the contact of the implant with the nerve itself and the crest was regularized by means of a crestal osteotomy with a bone bur.



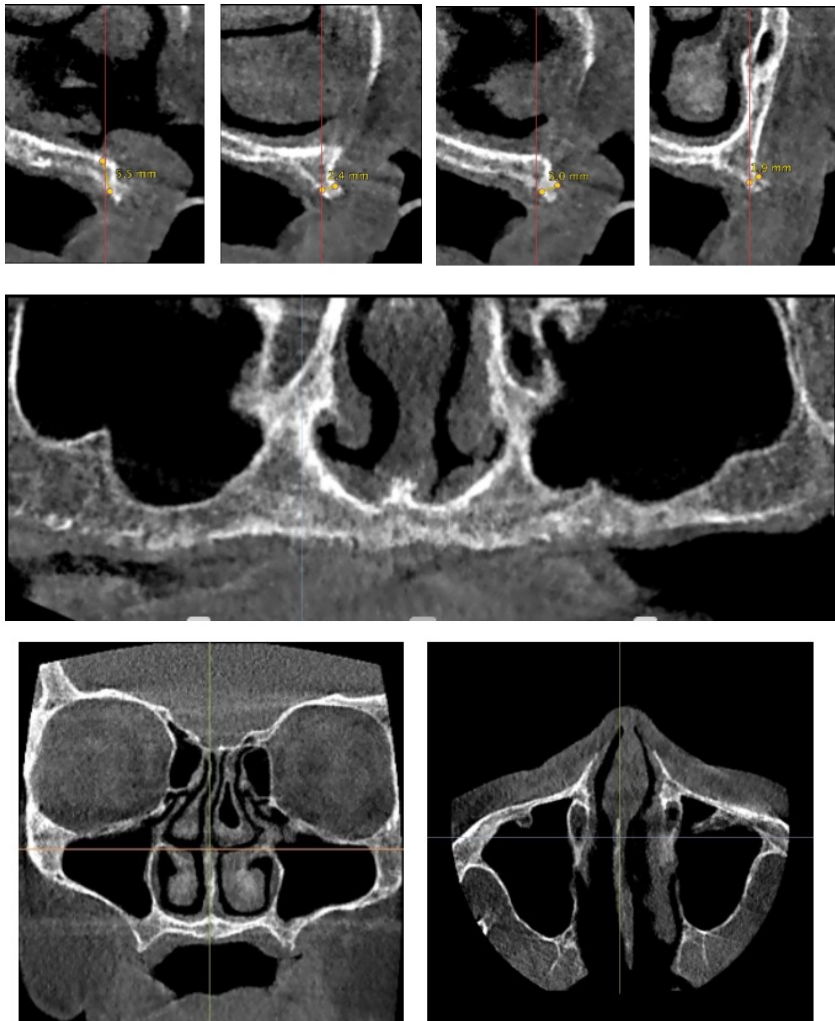
Once all the implants have been inserted, the multi-unit abutments are inserted and we proceeded with the plaster impression of the transfers and the taking of the vertical dimension (VDO) with pre-extractive prostheses previously packaged relining them with silicone for addition for occlusal registration (Occlufast rock - Zhermack) on the healing abutments



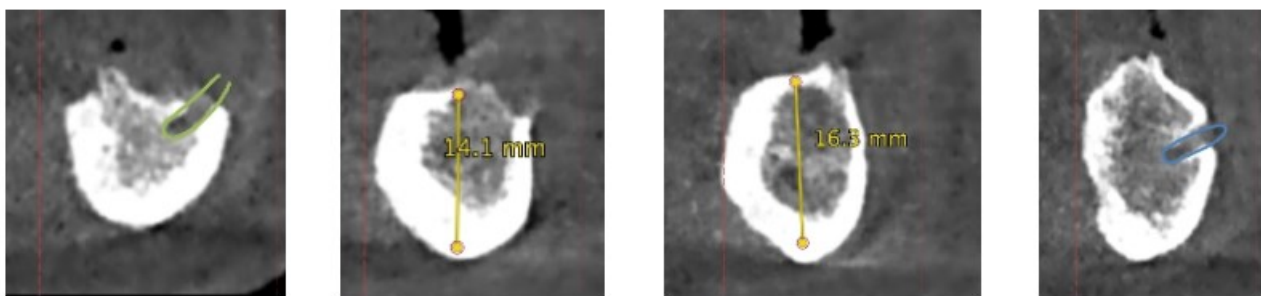
After 72 hours, the two screwed provisional prostheses were inserted without cantilever and without molars. It was chosen to mount up to the premolars precisely in order not to overload the chewing thus generating excessive stress on the implants, the definitive ones will also have deluded the molars. An occlusal scheme was given by distributing all contacts along the entire extension of the prosthesis with lighter contacts in the anterior area.

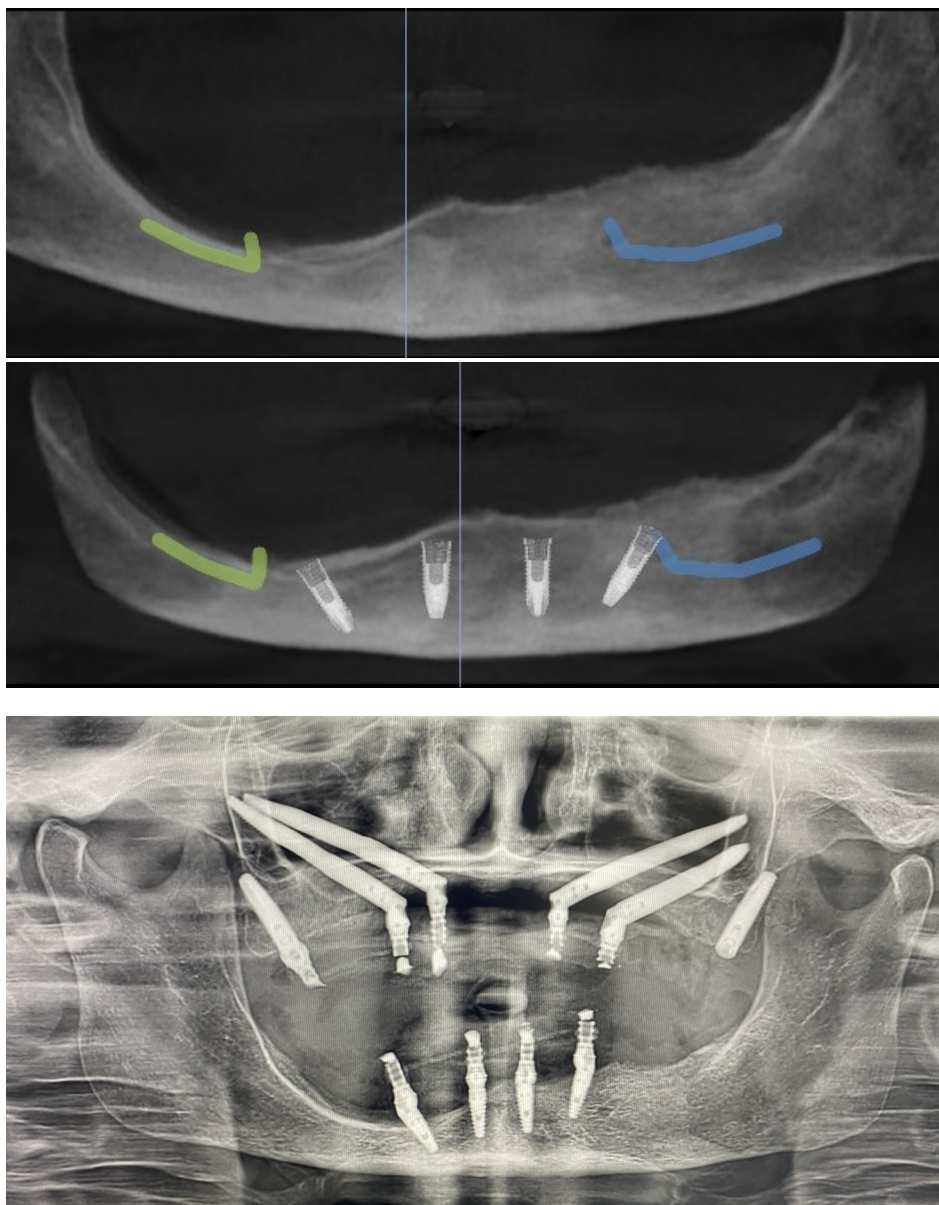


Preoperative CBCT Scan Upper jaw



Preoperative CBCT Scan Lower jaw



*Digital implants planning**Final OPG*

## Discussions

The objective of this study is to demonstrate the effectiveness of this type of graftless treatment by highlighting the current percentage of success with full arch implant rehabilitations with the use of zygomatic and pterygoid implants which is comparable to the percentage of success that occurs with traditional implants, for example with the All-on-4® protocol, ie around 95-98%. [11], [12] A fundamental aspect to take into consideration in this type of treatment is the possibility, if the conditions exist, of carrying out the immediate load with which the newly inserted implants are splinted with each other by the prosthesis, minimizing their micro-movements, which would cause a fibrointegration rather than an osseointegration [2]. This could happen when wearing a temporary removable prosthesis in case of bone regeneration.

## Conclusions

The use of this method has allowed the total rehabilitation of the oral cavity with implants and immediate loading, quickly restoring function and aesthetics as required by the patient. It is true that they are techniques that require experience on the part of the operator but from the moment in which the appropriate skills are possessed, it is possible to complete clinical cases of marked bone atrophy that would involve the use of bone grafts. Not to be confused, the use of these graftless techniques does not in any case exclude grafting solutions. It is a totally different approach but no one forbids you to proceed with a graft solution. One of the main problems is the provisional prosthesis as a mucocompressive mobile prosthesis would compromise the outcome of the regeneration. Generally, provisional implants are placed in strategic positions such as tuber and palate (premaxilla area) and make a provisional prosthesis that retained with locators on these implants without compressing the mucosa. [13] For this reason I preferred in this clinical case a graftless solution

## Conflict of Interest

The authors declare no conflict of interest.

## Acknowledgement

I thank Dr. Martina Viziale for helping me with the editing of this article, Dr. Matteo Giorgi for teaching me and passing on the passion for zygomatic implantology, Massimo Pagani for the clinical photo documentation and Prof. David Harley Brown, my English teacher who helped me in writing this article.

## References

1. P. Malo, B. Rangert, M. Nobre, All-on-4® immediate-function concept with Brånemark System implants for completely edentulous mandibles: a retrospective clinical study, *Clin. Implant Dent. Relat. Res.* 5 (Suppl 1) (2003) 2–9, <https://doi.org/10.1111/j.1708-8208.2003.tb00010.x>.
2. Tuminelli FJ, Walter LR, Neugarten J, Bedrossian E. Immediate loading of zygomatic implants: A systematic review of implant survival, prosthesis survival and potential complications. *Eur J Oral Implantol.* 2017;10 Suppl 1:79-87. PMID: 28944370.
3. Davo R, Pons O, Rojas J, Carpio E. Immediate function of four zygomatic implants: a 1-year report of a prospective study. *Eur J Oral Implantol.* 2010 Winter;3(4):323-34. PMID: 21180685
4. Aparicio, C.; Ouazzani, W.; Aparicio, A.; Fortes, V.; Muela, R.; Pascual, A.; Codesal, M.; Barluenga, N.; Manresa, C.; Franch, M. Extrasinus zygomatic implants: Three year experience from a new surgical approach for patients with pronounced buccal concavities in the edentulous maxilla. *Clin. Implant Dent. Relat. Res.* 2010, 12, 55–61.
5. P. P. T. Araújo, S. A. Sousa, V. B. S. Diniz, P. P. Gomes, J. S. P. da Silva and A. R. Germano. Evaluation of patients undergoing placement of zygomatic implants using sinus slot technique *International Journal of Implant Dentistry* (2016) 2:2 DOI 10.1186/s40729-015-0035-x
6. Aparicio, C.; Manresa, C.; Francisco, K.; Aparicio, A.; Nunes, J.; Claros, P.; Potau, J.M. Zygomatic Implants Placed Using the Zygomatic Anatomy-Guided Approach versus the Classical Technique: A Proposed System to Report Rhinosinusitis Diagnosis. *Clin. Implant Dent. Relat. Res.* 2014, 16, 627–642.
7. Aparicio C. A proposed classification for zygomatic implant patient based on the zygoma anatomy guided approach (ZAGA): a cross-sectional survey. *Eur J Oral Implantol.* 2011 Autumn;4(3):269-75. PMID: 22043470.
8. Antonio D'Agostino, Giorgio Lombardo, Vittorio Favero, Annarita Signoriello, Anna Bressan, Fabio Lonardi, Riccardo Nocini, Lorenzo Trevisiol, Complications related to zygomatic implants placement: A retrospective evaluation with 5 years follow-up, *Journal of Cranio-Maxillofacial Surgery*, Volume 49, Issue 7, 2021, Pages 620-627, ISSN 1010-5182, <https://doi.org/10.1016/j.jcms.2021.01.020>.
9. de Moraes EJ. The buccal fat pad flap: an option to prevent and treat complications regarding complex zygomatic implant surgery. Preliminary report. *Int J Oral Maxillofac Implants.* 2012 Jul-Aug;27(4):905-10. PMID: 22848893
10. Guennal P, Guiol J. Use of buccal fat pads to prevent vestibular gingival recession of zygomatic implants. *J Stomatol Oral Maxillofac Surg.* 2018 Apr;119(2):161-163. doi: 10.1016/j.jormas.2017.10.017. Epub 2017 Nov 3. PMID: 29107123
11. Malo P, de Araujo Nobre M, Lopes A, Ferro A, Moss S. Extramaxillary surgical technique: clinical outcome of 352 patients rehabilitated with 747 zygomatic implants with a follow-up between 6 months and 7 years. *Clin Implant Dent Relat Res* 2015;17(S1):e153-162.
12. Malo, M. de Araujo Nobre, A. Lopes, C. Francischone, M. Rigolizzo, All-on-4®" immediate-function concept for completely edentulous maxillae: a clinical report on the medium (3 years) and long-term (5 years) outcomes, *Clin. Implant Dent. Relat. Res.* 14 (Suppl 1) (2012) e139–150 *Eur J Oral Implantol.* 2011 Autumn;4(3):269-75.
13. Istvan urban Manual: Vertical and horizontal ridge augmentation: new perspective

**Citation:** Leoncavallo R. Full Oral Rehabilitation - Quad Zygoma with Extra-Sinusal Implants Placement Technique with Pterygoid Implants and Four Traditional Implants in The Lower Jaw with Immediate Loading: A Case Report. *SVOA Dentistry* 2023, 4:4, 115-122.

**Copyright:** © 2023 All rights reserved by Leoncavallo R. This is an open access article distributed under the Creative Commons Attribution License, which permits unrestricted use, distribution, and reproduction in any medium, provided the original work is properly cited.