

## Guided Bone Regeneration with BoneHeal™ Membrane after Explantation of Fractured Implant: Case Report

Débora Nascimento de Sá<sup>1</sup>, Marcelo do Lago Pimentel Maia<sup>2</sup>, Marcelo Yoshimoto<sup>2</sup>, Munir Salomão<sup>3</sup> and Irineu Gregnanin Pedron<sup>4\*</sup>

<sup>1</sup> DDS, Postgraduation student, Marcelo Yoshimoto Institute, São Paulo, Brazil.

<sup>2</sup> Professor, Department of Oral Implantology, Marcelo Yoshimoto Institute, São Paulo, Brazil.

<sup>3</sup> DDS, MSD. Professor and Independent Researcher, São Paulo, Brazil.

<sup>4</sup> Independent Researcher and Professor, IMED - Instituto de Medicina, Estudos e Desenvolvimento, São Paulo, Brazil.

**\*Corresponding Author:** Irineu Gregnanin Pedron, IMED - Instituto de Medicina, Estudos e Desenvolvimento, São Paulo, Brazil.

DOI: <https://doi.org/10.58624/SVOADE.2023.04.0145>

**Received:** July 27, 2023 **Published:** August 18, 2023

### Abstract

Implantoprosthesis rehabilitation has become the main method to reestablish totally or partially edentulous patients, with a high success rate. However, some complications can cause implant loss. The main one is periimplantitis, with bone loss around the osseointegrated implant. However, implant fractures or incorrect implant position may compromise implant rehabilitation and require implant removal. Several techniques can be used for implant explantation, and the dental surgeon should opt for the easiest and most conservative technique, ensuring the greatest preservation of remaining bone tissue and aiming at the future reinstallation of another osseointegrated implant. Sometimes, associated Guided Bone Regeneration techniques may be necessary in conjunction with future implant installation, using various procedures or biomaterials. The purpose of this article is to present the case of a patient who underwent explantation of a fractured implant. A polypropylene membrane (BoneHeal™) was used and an implant was reinstalled 8 months after explantation.

**Keywords:** Tissue Regeneration; Bone Regeneration; Explantation; Oral Surgery; Bioengineering; Implantology.

### Introduction

Dental implants have become the main method of aesthetic and functional rehabilitation for totally or partially edentulous patients. They have a high success rate, ranging from 97.1% to 96.5% in 5 and 10 years, respectively. However, several complications can lead to the need for implant removal. Periimplantitis, loss of bone tissue, incorrect implant position and implant fractures may compromise implant rehabilitation and require implant removal<sup>1,2</sup>.

Several techniques can be employed in implant explantation, including reverse torque technique, the use of twist drills, diamond or carbide tips, piezosurgery, lasers or the combination of different techniques<sup>1-3</sup>.

It is important to emphasise that proper planning is essential for the best management, ensuring the greatest preservation of remaining bone tissue and aiming at the future reinstallation of another osseointegrated implant. Additionally, the presence of anatomical structures adjacent to the implant to be removed, the amount of remaining bone and the implant design should be considered in the implant explantation<sup>1,2</sup>.

Associated Guided Bone Regeneration techniques may be required for future implant placement, employing various procedures or biomaterials. The purpose of this article is to present the case of a patient who underwent explantation of a fractured implant. A polypropylene membrane (BoneHeal™) was used and an implant was reinstalled 8 months after explantation.

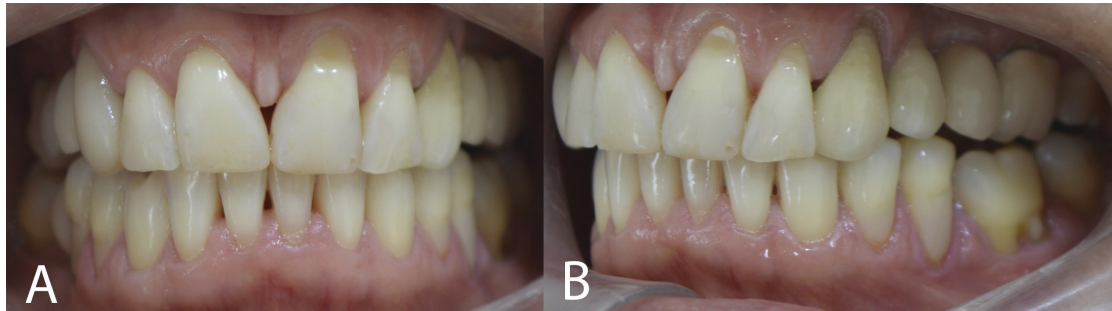## Case Report

A Caucasian female patient, 58-years-old, attended the clinic complaining of a prosthetic crown on an implant with mobility.

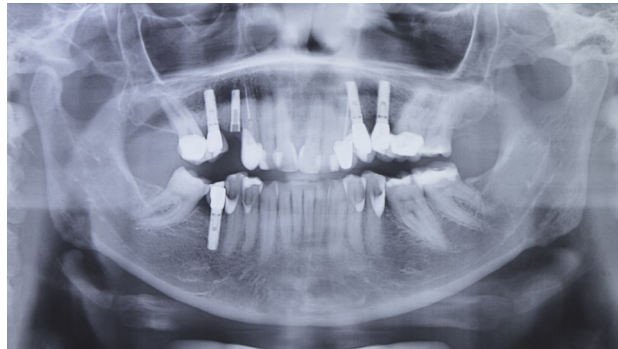Clinically, mobility of the metal-ceramic crown over the implant was observed in the region of tooth 25. Periodontal disease and suspected periimplantitis were not observed (Figure 1).

Radiographically, absence of bone loss and periodontal and periimplant diseases were observed (Figure 2). However, cone beam computed tomography revealed fracture of the implant buccal wall and the external hex connection of implant 25 (Figure 3).

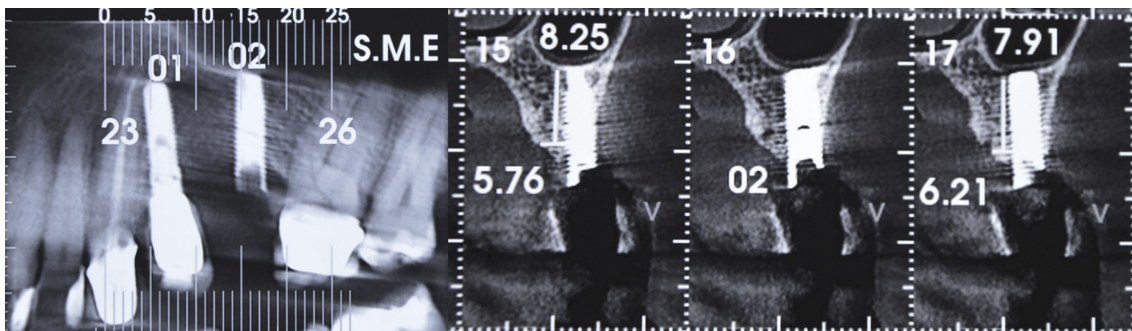
Upon removal of the prosthesis, the fracture and the removal of the connection fragment was noted (Figure 4).



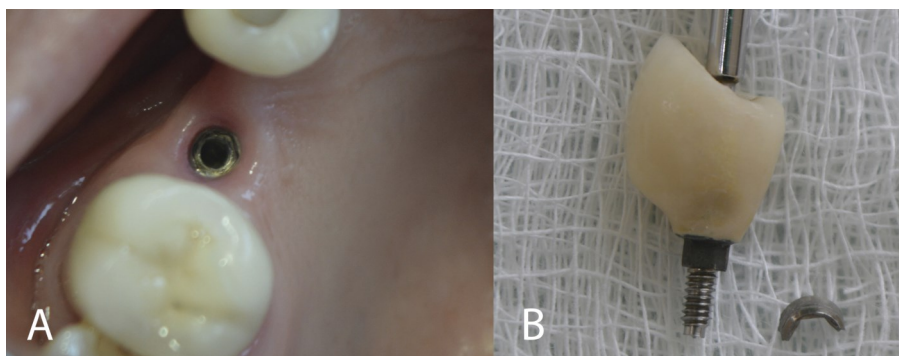
**Figure 1:** Initial clinical aspects: frontal (A) and left lateral (B) views.



**Figure 2:** Initial radiographic aspects (panoramic radiograph).



**Figure 3:** Computed tomography presenting fracture of the implant buccal wall and the external hex connection of implant 25.



**Figure 4:** Intraoral clinical aspect of implant fracture (A) and removed fragment (B).

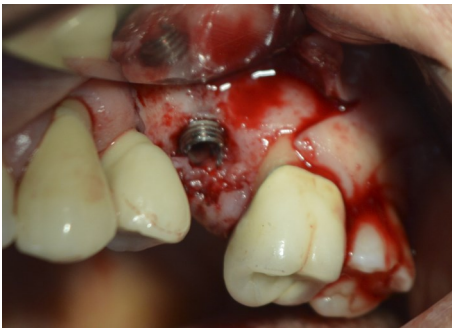Implant explantation was indicated, followed by the use of a polypropylene membrane for bone preservation and clot maintenance, with a view to future osseointegrated implant installation and subsequent implantoprosthesis rehabilitation. After due explanations, the patient agreed to the procedure.

After local anaesthesia, intrasulcular and over the bone crest incisions and mesial and distal relaxations were made, flapping the mucogingival flap and exposing the implant (Figure 5). In an attempt to use the counter-torque technique associated with small bone wear parallel to the long axis of the implant, the implant was removed (Figures 6 and 7). The region was abundantly curetted and washed with saline, with bleeding present. The polypropylene membrane (BoneHeal™, São Paulo, Brazil) was adapted and installed over the surgical site and sutured. Analgesic, anti-inflammatory and antibiotic drugs were prescribed to the patient.

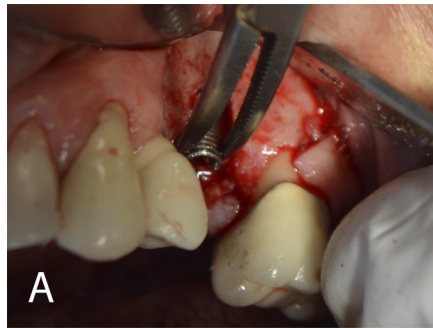
At the subsequent visit, after 15 days, the membrane and sutures were removed (Figures 8 to 10). No complaints or complications were reported.

After 8 months, the installation of the osseointegrated implant was planned. Clinically, the preservation of bone tissue and gingival mucosa was observed (Figure 11), favoured by the use of the polypropylene membrane. Computed tomography revealed preservation of bone remnant, compared to the tomography before explantation (Figure 12).

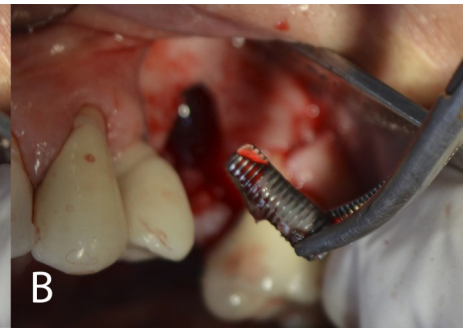
A 3.8 X 10mm Morse Cone implant (SIN Implantes, São Paulo, Brazil) was installed. After the osseointegration period (8 months after installation), the screw-retained implant prosthesis was made (Figures 13 and 14).



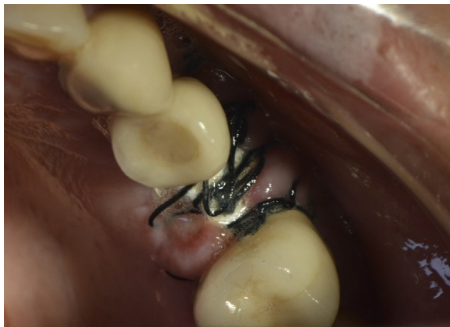**Figure 5:** Mucogingival flap and implant exposure.



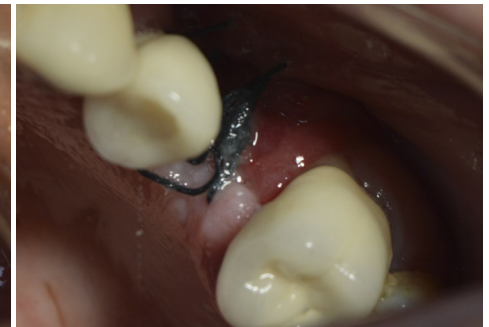**Figure 6:** Seizure of the implant with needle holder (A) and implant explantation (B).



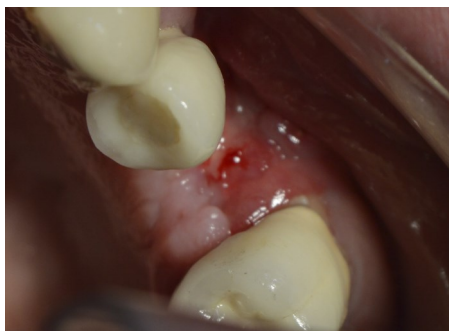**Figure 7:** Implant removed.



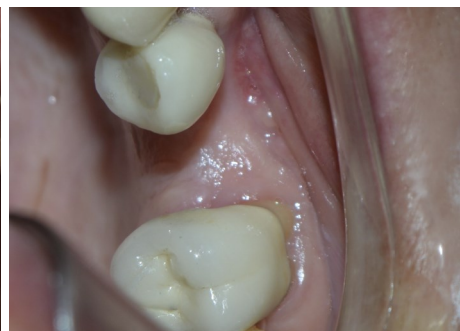**Figures 8:** Polypropylene membrane and sutures after 15 days.



**Figures 9:** Polypropylene membrane removed after 15 days.

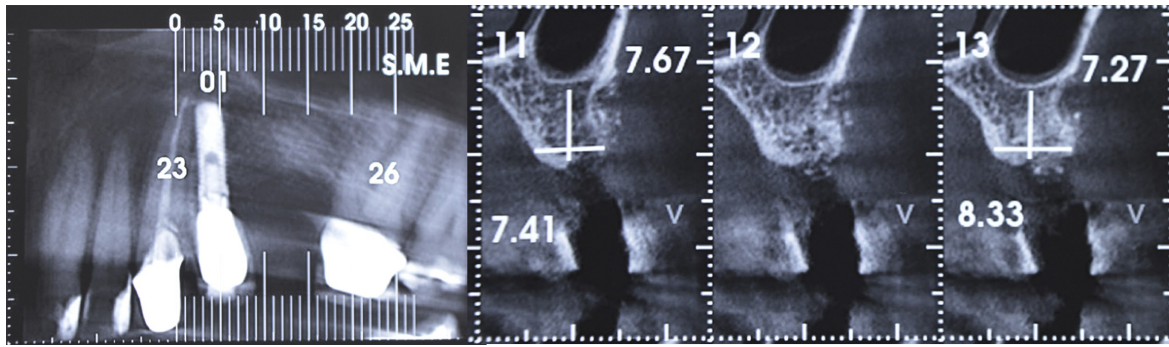


**Figures 10:** Remaining sutures removed after 15 days.

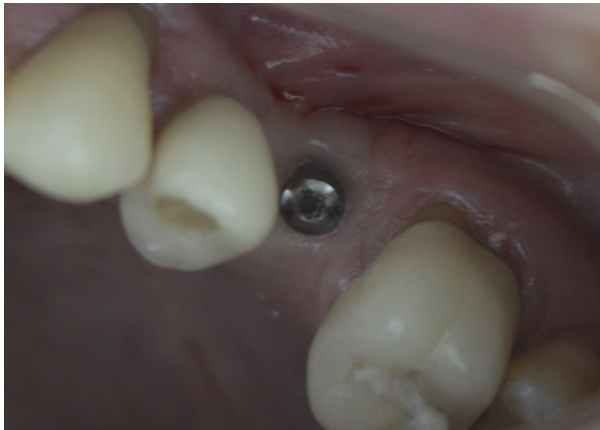

**Figure 11:** Preservation of bone tissue and gingival mucosa after 8 months.

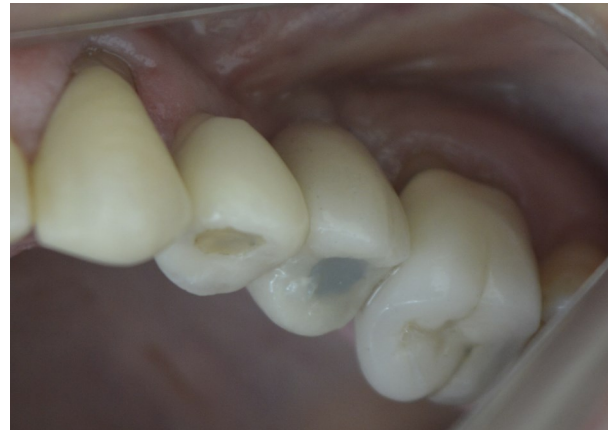



**Figure 12:** Computed tomography revealed preservation of bone remnant, compared to the tomography before explantation.



**Figures 13:** Morse cone implant installed.




**Figures 14:** Screw-retained implant prosthesis.

## Discussion

The Systematic Review presented by Roy et al. (2020) established that 10.8% of implants were removed due to implant or prosthetic component fracture. In contrast, 8.4% of explants were caused by malpositioning and 1.4% by neurosensory deficit of the jaws. However, the main causes of explantation were periimplantitis and bone loss (59.9% and 16.7%, respectively).

The application of counter-torque in an anti-clockwise direction to disrupt osseointegration is the most commonly used and the most conservative technique, allowing removal of the implant and removal of little or no bone. When implant explantation is not possible, with fractured implants or prosthetic components, or with a torque greater than 200Ncm, the use of trephines is required. Additionally, the use of Implant Retrieval can also be employed (Figure 15)<sup>1-3</sup>.



**Figure 15:** Implant Retrieval (A) and trephines (B and C) and can be employed.

The explantation technique using trephines can be performed with or without flaps, and with immediate or delayed replacement implantation. Obviously, the flapless technique requires a computerised tomography scan prior to the execution of the technique. And late implant installation is considered the gold standard, precisely because of the need to achieve primary stability of the replacement implant. In the case of hollow drills with an internal diameter greater than the implant diameter, the use of trephines is clearly more aggressive than the counter-torque technique<sup>1-3</sup>.

The use of other types and shapes of drills, in the adjacent wear of bone tissue or the implant, favouring its removal, can be associated. However, when performing implant wear, the possibility of the presence of titanium particles in the adjacent bone should be emphasised<sup>1,2</sup>.

Osteotomy performed using piezosurgery or surgical laser (Er,Cr:YSGG) has also been reported in the literature with successful explantation. Osteotomy using piezosurgery is safer and more precise without the risk of injury to soft tissues or adjacent anatomical structures<sup>1-3</sup>.

Winnen et al.<sup>3</sup> (2021) presented 5 methods of equipment that, through the application of energy (ultrasonic, induction or electromagnetic heat), would promote osseodesintegration at the interface between implant and bone. However, these processes are discouraged by the lack of control in the generation of energy and subsequent production of heat or cold to the adjacent bone tissue, which can cause bone necrosis.

It is important to consider that each case must be individualised, sometimes requiring the combination of several techniques. Another consideration to be emphasised is the possibility of immediate or delayed reinstallation of a replacement implant. If late, the use of biomaterials should be established in techniques that prioritise Guided Bone Regeneration and Guided Tissue Regeneration. The main biomaterials include autogenous bone graft (en bloc or particulate), plasma rich in growth factors and xenogenic, allogenic or alloplastic biomaterials<sup>1,2</sup>.

Over the last few years, several techniques and materials have been developed to perform Guided Bone Regeneration techniques. Usually, the techniques require the placement of grafts, biomaterials or membranes covered by a total flap in order for healing to occur by first intention. In this perspective, surgical techniques and approaches are often very complex, especially in procedures with autogenous grafts, which greatly increases the morbidity of these surgeries. In contrast, membranes that can be exposed to the oral environment and do not require grafts to fill the socket or bone defect are essential, such as the BoneHeal membrane (polypropylene)<sup>4-16</sup>, used in this case.

The prevention of bone resorption by means of the polypropylene membrane begins with the maintenance of the blood clot inside the bone cavity. As the clot is rich in platelet supply and factors involved in bone healing and neoformation, its maintenance by the membrane contributes to Guided Bone Regeneration<sup>4-16</sup>.

The polypropylene membrane has been widely used in Guided Bone Regeneration procedures. Basically, its primary indication occurs after extraction and future implant installation<sup>4-11</sup>. The use of the polypropylene membrane after the exeresis of cystic lesions<sup>12,13</sup> and in Guided Bone Regeneration in implants affected by periimplantitis and severe bone loss<sup>14</sup> have also been described. In a comparative study, Borges et al.<sup>15</sup> (2011) presented satisfactory results in the simultaneous elevation of the maxillary sinus membrane and placement of dental implants with the use of the polypropylene barrier and without bone graft, after 6 months of follow-up. Recently, Macedo et al.<sup>16</sup> (2023) presented the preservation of the periimplant mucosa by the use of a polypropylene membrane after tooth extraction, favouring not only gingival aesthetics, but also the protection generated by the periimplant mucosa.

## Conclusion

The use of polypropylene membrane is highly promising in Guided Bone Regeneration. Despite confronting rigid concepts of Implant Dentistry, such as the need for grafts to recover bone defects or the non-exposure of the barrier to the oral environment, it is highly beneficial to patients, eliminating costs and procedures. The feasibility of this procedure and technique, together with its reduced morbidity, opens up new perspectives in this dental area of rehabilitation. This paradigm shift towards more conservative procedures for patients and dental surgeons may favour biocompatibility and make Guided Bone Regeneration less invasive procedures.

## Conflict of Interest

The authors declare no conflict of interest.

## References

1. Roy M, Loutan L, Garavaglia G, Hashim D. Removal of osseointegrated dental implants: a systematic review of explantation techniques. *Clin Oral Investig* 2020;24(1):47-60.
2. Solderer A, Al-Jazrawi A, Sahrman P, Jung R, Attin T, Schmidlin PR. Removal of failed dental implants revisited: questions and answers. *Clin Exp Dent Res* 2019;5(6):712-724.
3. Winnen RG, Kniha K, Modabber A, Al-Sibai F, Braun A, Kneer R, Hölzle F. Reversal of osseointegration as a novel perspective for the removal of failed dental implants: a review of five patented methods. *Materials (Basel)* 2021;14(24):7829.
4. Pedron IG, Salomão M, Bispo LB. Regeneração óssea guiada com membrana de polipropileno na preservação alveolar pós-exodontia prévia a futura instalação de implante osteointegrado. *Revista Maxillaris Portugal* 2017;83(10):36-45.
5. Pedron IG, Bispo LB, Salomão M. Selective polypropylene membrane: alveolar behavior in post-extraction repair with a view to the future installation of osseointegrated implants. *Italian Journal of Dental Medicine* 2018;3(2):33-8.
6. Pedron IG, Magno Filho LC, Salomão M, Varoli FP, Al-Juboori MJ. Guided bone regeneration with polypropylene membrane associated with dental implant placement. *J Health Sci Inst* 2018;36(4):275-80.
7. Pedron IG, Salomão M. Polypropylene membrane in post-extraction alveolar repair with a future perspective on osseointegrated implants. *Implants - International Magazine of Oral Implantology* 2019;20(1):10-15.
8. Pedron IG, Salomão M. 聚丙烯膜在拔牙术后牙槽骨修复中的应用 -- 展望骨内种植修复发展前景 (The application of polypropylene membrane in alveolar bone repair after tooth extraction - looking at the prospect of developing intraosseous repair with implants). *Cosmetic & Implants China* 2019(1):17-20.
9. Pedron IG, Salomão M, Medeiros JMF, Shitsuka C, Magno Filho LC. Placement of dental implant after use of guided bone regeneration with polypropylene membrane. *Scientific Archives of Dental Sciences* 2019;2(8):25-30.
10. Bispo LB, Salomão M, Roque Neto A, Shitsuka C, Pedron IG. Uso de membrana como fator preditivo do comportamento ósseo alveolar pós-exodontia. *Revista Odonto* 2020;28(55):21-29.
11. Barros NMV, Salomão M, Shitsuka C, Pedron IG. Use of polypropylene membrane after exodontia for maintaining bone thickness: Case report. *SVOA Dentistry* 2021;2(4):161-167.
12. Santos LN, Najar ET, Cerqueira JS, Salomão M, Kuramochi MM, Medeiros JMF, Shitsuka C, Pedron IG. Use of polypropylene membrane to accelerate bone maturation after cystic exeresis. *Scientific Archives of Dental Sciences* 2020;3(12):46-53.
13. Pedron IG, Seroli W, Salomão M, Kubo H, Shitsuka C. Reparação óssea por meio de membrana de polipropileno após exérese cística. *Revista Maxillaris Portugal* 2020;15(112):36-43.
14. Bacaro KD, Salomão M, Lourenço D, Magno Filho LC, do Lago Pimentel Maia M, Pedron IG. Bone regeneration using polypropylene membrane in peri-implant bone loss: Case Report with 4 years of follow-up. *SVOA Dentistry* 2022;3(3):162-167.
15. Borges FL, Dias RO, Piattelli A, Onuma T, Cardoso LAG, Salomão M, Scarano A, Ayub E, Shibli JA. Simultaneous sinus membrane elevation and dental implant placement without bone graft: a 6-month follow-up study. *J Periodontol* 2011;82(3):403-12.
16. Macedo SBS, Salomão M, Maia MLP, Yoshimoto M, Pedron IG. Preservation of peri implant mucosa by the use of polypropylene membrane after dental extraction: A case report. *SVOA Dentistry* 2023;4(4):156-161.

**Citation:** de Sá DN, Maia MDP, Yoshimoto M, Salomão M, Pedron IG. Guided Bone Regeneration with BoneHeal™ Membrane after Explantation of Fractured Implant: Case Report. *SVOA Dentistry* 2023, 4:5, 172-177.

**Copyright:** © 2023 All rights reserved by Pedron IG., et al. This is an open access article distributed under the Creative Commons Attribution License, which permits unrestricted use, distribution, and reproduction in any medium, provided the original work is properly cited.