

# Socket Preservation Technique Using Resorbable Collagen Membrane v/s High Density d-PTFE Membrane: A Must in Today's Implant Rehabilitations. A Literature Review and 2 Clinical Cases Report

Carine Tabarani, DDS, MSC<sup>1\*</sup> and Saleh Al Hijawi, DDS<sup>2</sup>

<sup>1</sup> Senior lecturer- Consultant Oral Surgeon, Private Practice exclusive Oral Surgery, Implantology, Oral Medicine, Abu Dhabi-UAE.

<sup>2</sup> Private Practice, Abu Dhabi-UAE.

\***Corresponding Author:** Carine Tabarani, DDS, MSC, Senior lecturer- Consultant Oral Surgeon, Private Practice exclusive Oral Surgery, Implantology, Oral Medicine, Abu Dhabi-UAE.

DOI: <https://doi.org/10.58624/SVOADE.2024.05.0165>

**Received:** January 12, 2024 **Published:** January 29, 2024

## Abstract

Following tooth extraction, resorption in alveolar bone results in narrowing of remaining ridge in the extraction site leading to compromised functional and aesthetic outcomes. The overall goal of the present article is to shed light on the importance of the socket preservation procedure in preserving the original bone dimensional contours, while comparing two essential approaches, using non-resorbable high density d-PTFE membranes v/s the non-cross linked collagen resorbable membranes, by assessing the clinical results in terms of regenerated bone volume, postoperative complications and evaluation of keratinized tissue in grafted areas with either one of the above mentioned membranes.

**Keywords:** Extraction, socket preservation, collagen membrane, d-PTFE

## Introduction

Bone resorption following tooth extraction is considered an obstacle for implant rehabilitation in desired positions and requires more complicated bone reconstruction procedures.

The aim of the socket preservation technique is to preserve the original bone dimensional contours by limiting the post-extraction resorption<sup>1,10</sup>.

Standard alveolar ridge preservation involves filling the extraction site with biomaterials associated most of the time to autologous bone graft<sup>4</sup>, with the use of barrier membranes such as non-cross linked collagen membrane or non-resorbable high-density polytetrafluoroethylene (d-PTFE) membrane. Several materials may be used in the mentioned procedures, including allografts, xenografts, autografts.

The following article describes the advantages of using membranes in socket preservation technique while highlighting the importance of the d-PTFE in optimizing the aesthetic results by enhancing both hard and soft tissues in host sites. We used in the following clinical cases, two different types of membranes as part of the socket preservation procedure with xenograft as biomaterial to fill the extracted socket. Both patients with anterior teeth indicated for extraction requiring ridge preservation to limit bone resorption and guarantee adequate implant placement in ideal position delivering functional and aesthetic results.

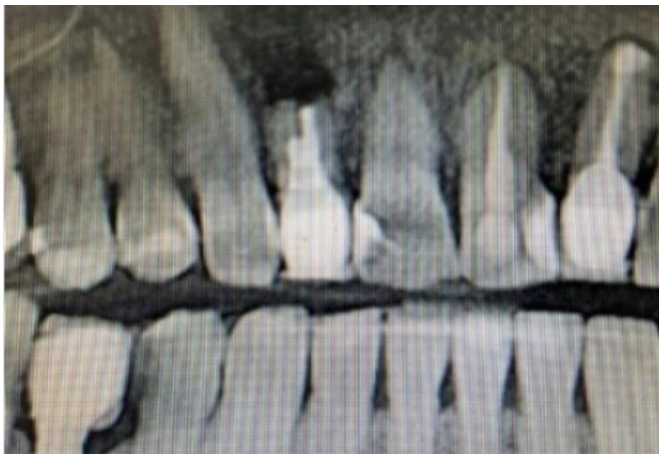The overall goal of the above article is to shed light on the importance of the socket preservation technique by providing the clinicians with valid tools to help them optimise their clinical outcomes.

### Clinical Case 1:

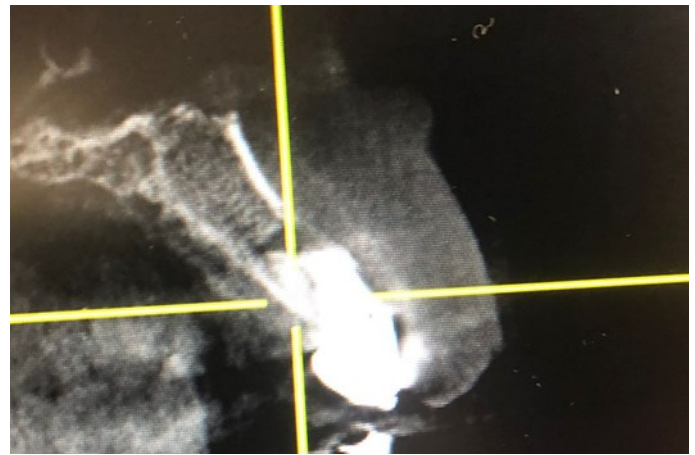A 51-year-old patient came to our center for a recurrent lesion following a failed apicectomy and retro-filling that was conducted two years ago on tooth no 7.

Intraoral examination showed a painless swelling on apex of tooth#7 with no pain on vertical and horizontal percussion. OPG showed radiolucent lesion on resected apex no 7 with insufficient crown to root ratio and absence of buccal bone as per CBCT. (Figure 1,2). Patient had no health issue to report. An atraumatic extraction for tooth no 7 was planned, followed by alveolar ridge preservation using non-cross-linked collagen membrane (ZIMMER BIOMET, Socket repair membrane) associated to xenograft under local anesthesia. A provisional acrylic Maryland was prepared prior to intervention (Figure 3). Atraumatic extraction with curettage of apical lesion (Figure 3,4) were done followed by socket preservation (Figure 5,6), the membrane was placed inside the socket with xenograft, Nylon non resorbable stitches 3(0) were used. Post-operative recommendations were given.

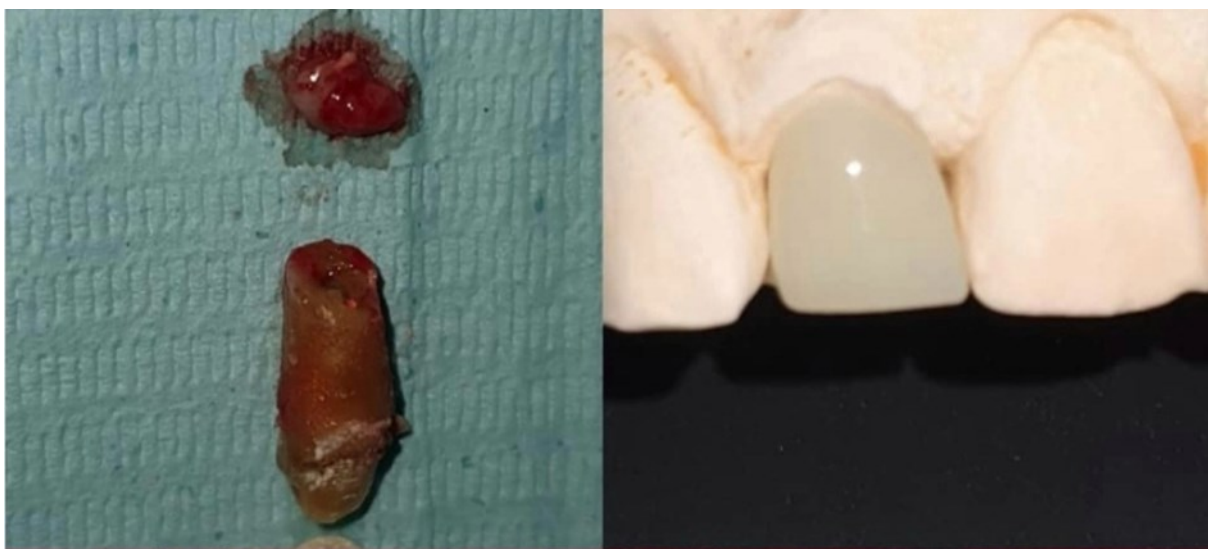Six months post-operative CBCT (Figure7,8) showed sufficient amount of bone formed in socket with satisfactory soft tissue in grafted site. An implant STRAUMANN, BLT 3.3\*10mm was placed (Figure 9), followed 3 months later by final cemented crown over implant (Figure 10). Two years follow-up showed an excellent functional and esthetic outcome with an idea 3-dimensional soft tissue anatomy (Figure 11).



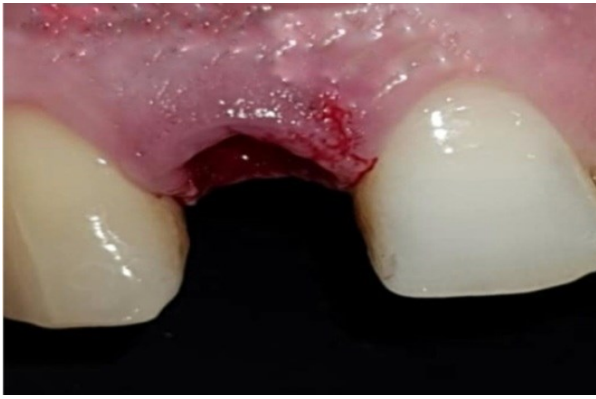**Figure 1:** Frontal cut showing the recurrent periapical lesion with the previously resected root of tooth#7.



**Figure 2:** Cone beam computed tomography showing the previously resected apex with recurrent lesion on apex#7, note the thin buccal plate.



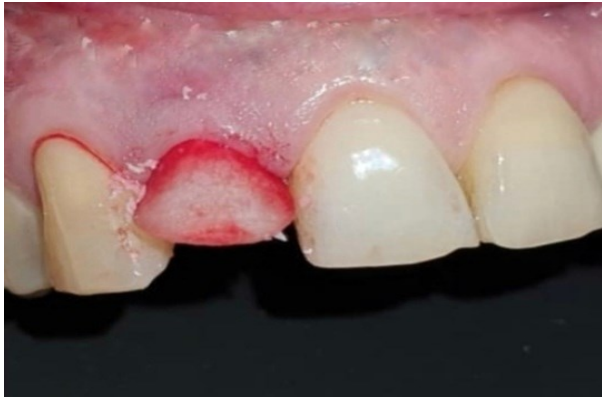**Figure 3:** Extracted tooth#7 with periapical lesion. A temporary Maryland bridge is prepared to guide soft tissue healing.



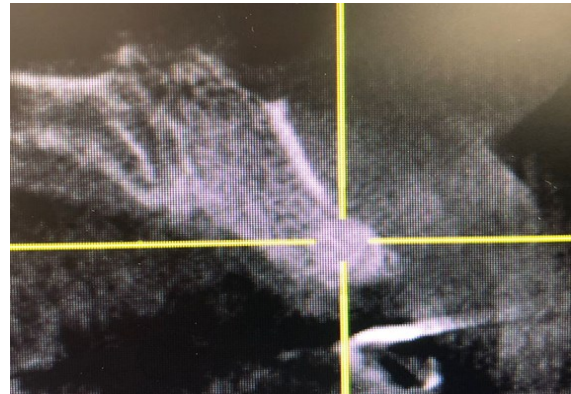**Figure 4:** Intraoral view following conservative atraumatic extraction of tooth#7.



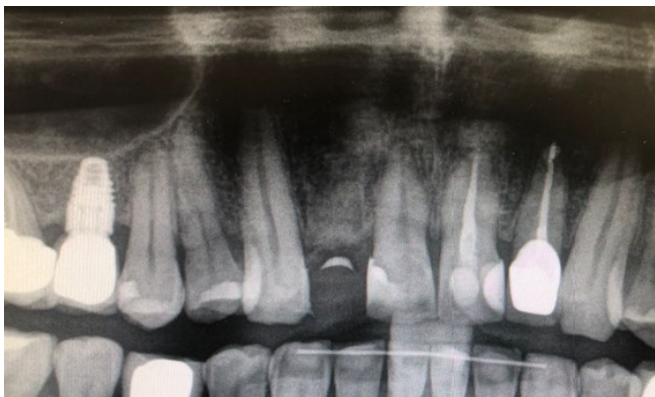**Figure 5:** Collagen membrane (Zimmer Socket Repair Membrane) used for socket preservation.



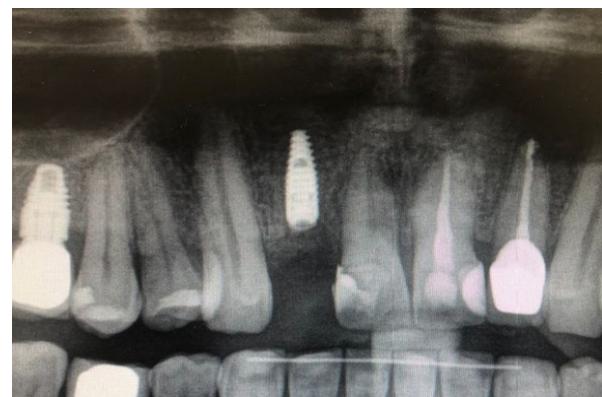**Figure 6:** Following conservative extraction of tooth#7, non- cross linked collagen membrane (Zimmer Socket Repair membrane) was placed inside the bone socket.



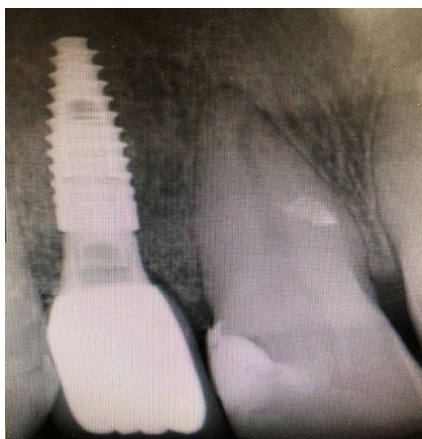**Figure 7:** Six months post-operative Cone beam computed tomography, showing the amount of bone preserved sufficient for implant placement in ideal 3D position.



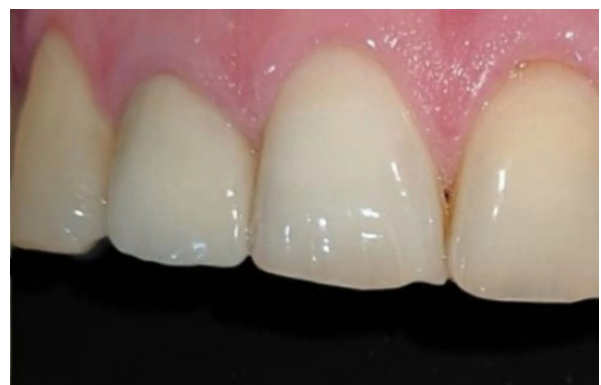**Figure 8:** Panoramic X-ray six months following socket preservation technique.



**Figure 9:** OPG three months following implant (STRAUMANN, BLT: 3.3\*10 MM) placement, note the amount of bone surrounding implant site#7.



**Figure 10:** Intraoral X-ray, 2 years following occlusal loading.



**Figure 11:** Intraoral view 2 years post-operatively, showing a satisfactory functional and aesthetic outcome.



## Clinical Case 2:

A 37-year-old female patient came to us for an asymptomatic cracked tooth no 9. Intraoral examination showed an unrestorable upper left central incisor (Figure 12). No pain was detected on vertical and horizontal percussion.

The OPG and CBCT revealed an unfavorable crown to root ratio for tooth no 9 which is a clear indication for extraction, associated to a supernumerary central incisor located in palatal area neighboring tooth no 9, making the intervention more challenging in limiting bone loss during procedure (Figure 13,14).

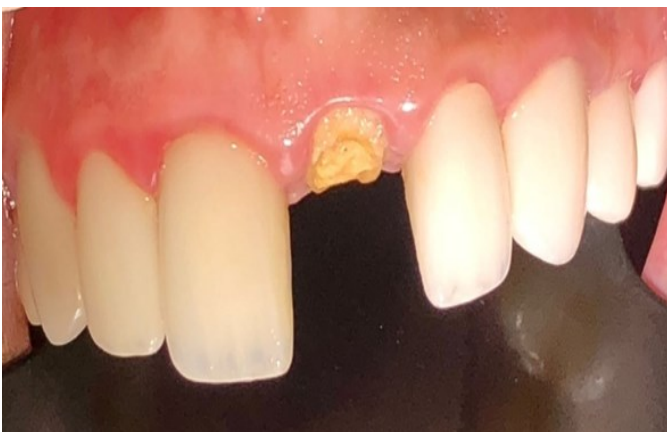A mucoperiosteal flap was elevated in the palate area and the maxillary central incisor no 9 was extracted with the supernumerary tooth under local anesthesia (Figure15,16).

Non resorbable d-PTFE membrane (CYTOPLAST TXT-200) associated to xenograft were placed in site of tooth no 9 as part of the socket preservation procedure (Figure 17), the d-PTFE membrane was partially exposed following closure with Nylon 3(0) stitches as part of the open technique resulting in preservation of soft tissue architecture and keratinized tissue width. Post-operative recommendations were given to patient. The membrane was removed non surgically one month post-operatively using tissue forceps with topical anesthesia and an OPG taken, showing sufficient amount of bone in area of tooth no 9 (Figure 18).

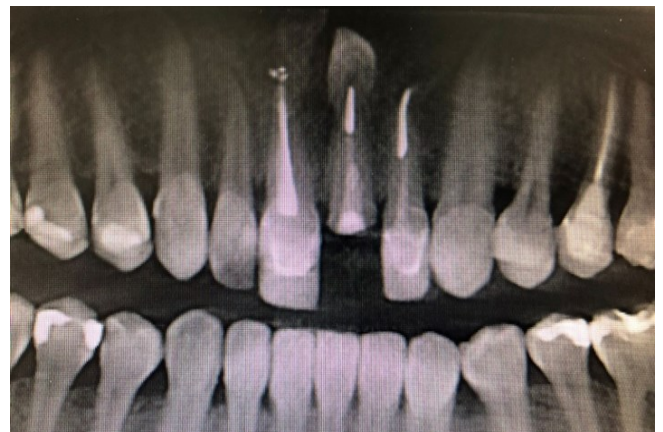A CBCT taken 6 months later, showed the gained amount of bone ready to receive the implant with the satisfactory aesthetic soft tissue architecture (Figure19,20).

Three months following implant placement, results showed stable mesial and distal papilla with enhanced buccal soft and hard tissues (Figure 21,22).

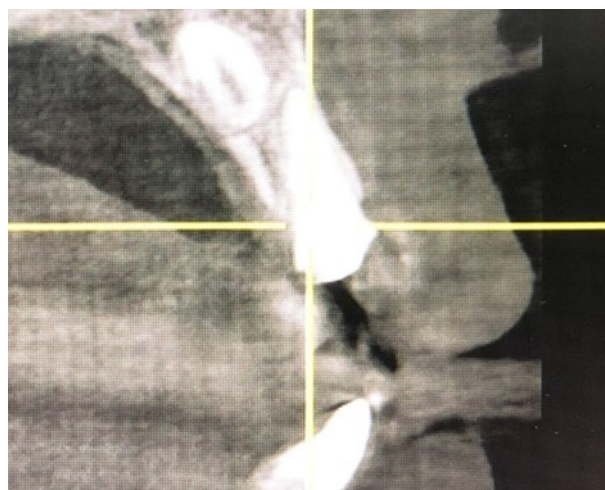
The final result was both aesthetically and functionally overwhelming for the patient (Figure 23).



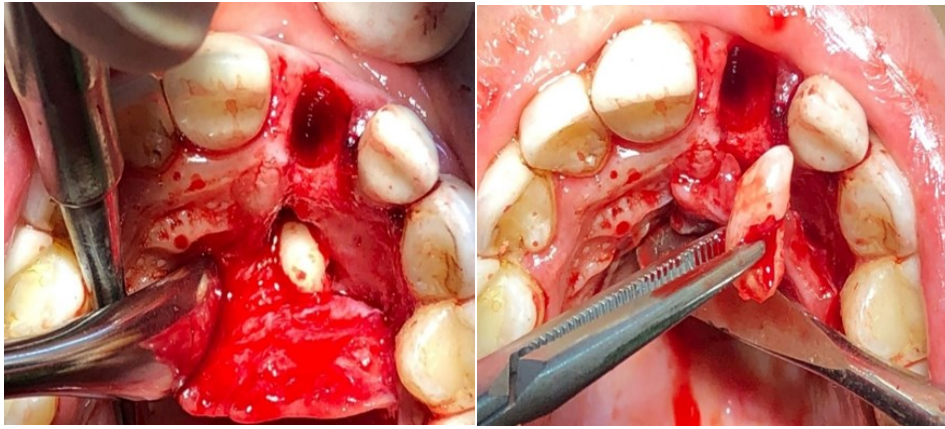
**Figure 12:** Clinical intraoral view of cracked tooth no 9.



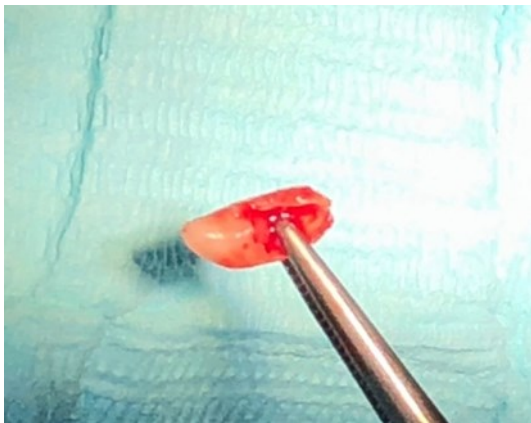
**Figure 13:** Frontal view showing the cracked tooth no 9 with supernumerary tooth present in palatal area.



**Figure 14:** Cone beam computed tomography (CBCT), showing the limited amount of buccal bone with the unfavorable root to crown ratio and palatal positioned supernumerary tooth.



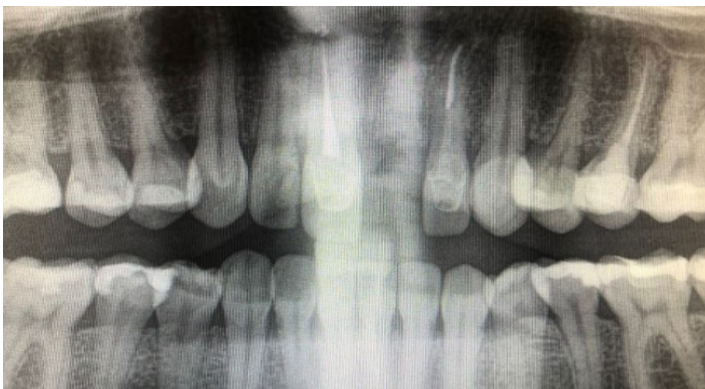**Figure 15:** Intraoral view of reflected muco-periosteal palatal flap following extraction of tooth no 9, and showing the supernumerary tooth located in palate neighboring no 9.




**Figure 16:** Supernumerary tooth removed.



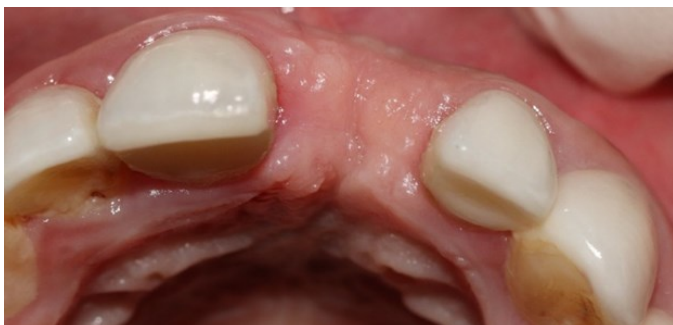**Figure 17:** Non-resorbable d-PTFE membrane, (CYTOPLAST TXT-200).



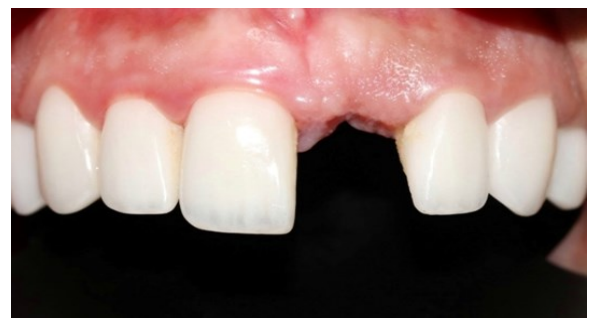**Figure 18:** 1-month post-operative OPG, showing satisfactory amount of bone in grafted area, following removal of d-PTFE (Cytoplast TXT-200).



**Figure 19:** 6 months post-operative CBCT showing the high amount of bone formed in grafted site.

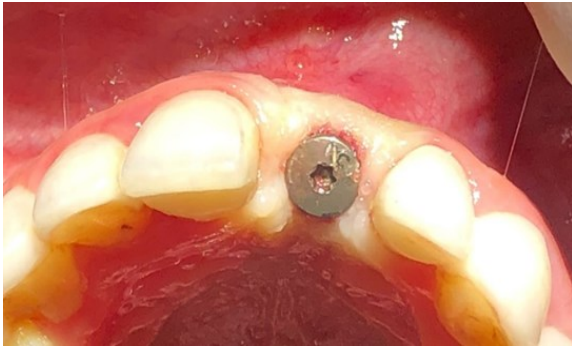


**Figure 20:** Clinical occlusal view showing the satisfactory amount of soft tissue gained in tooth no 9 area.

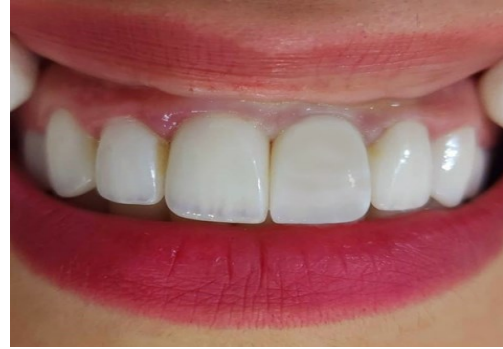

**Figure 21:** Intraoral view showing optimized aesthetic anatomy of soft and hard tissues, with well positioned mesial and distal papilla, following implant placement.





**Figure 22:** Occlusal view of implant no 9, placed 6 months following socket preservation technique using non resorbable d-PTFE membrane (Cytoplast TXT-200) and showing excellent bone and soft tissue anatomy.



**Figure 23:** Intraoral view of final crown in place, showing the aesthetic outcome of implant site no 9 with excellent amount of soft tissue surrounding area and optimizing the results.

## Discussion

The continually evolving field of guided bone regeneration strives to create results around implants similar to those on natural teeth.

Today, guided bone regeneration technique plays an important role in creating space to allow sufficient bone formation and maturation.<sup>2</sup>

Noticeably a new bone formation is obvious in the ridge preservation technique, making the conserved socket ideal for supporting the process of osseointegration of dental implant<sup>9</sup>.

In the following article extraction sockets that healed for 6 months using d-PTFE membranes produced high bone and soft tissue formation compared to the collagen membrane. As per Wen the period of 6 months is enough to produce the highest amount of vital bone<sup>8</sup>.

In clinical case two, the d-PTFE membrane was partially exposed following closure with Nylon 3(0) stitches, as part of the open technique resulting in preservation of soft tissue architecture and keratinized tissue width without any need for surgical removal of the membrane.

Most cases of socket preservation using d-PTFE are opened to the oral flora, yet as per Laurito et al., the exposed d-PTFE membranes showed a prevention of epithelium migration in post-extraction sockets<sup>6</sup>.

In the d-PTFE membrane clinical case 2, it is shown at 1 month post-operative examination, connective tissue ingrowth with stability of the grafted bone area ready to receive implants. The most significant advantage of the d-PTFE membrane and that was met in the following clinical case, as per Barber<sup>3</sup>, the absence of graft infection while enhancing and preserving the keratinized mucosa.

Another study by Mazzucchi et al, concluded that the use of d-PTFE can improve bone regeneration due to antimicrobial properties<sup>7</sup>. Although outstanding results were obtained in the resorbable collagen membrane case, still optimizing the soft tissue anatomy was a priority.

As per Hoffmann et al., the use of d-PTFE in extraction sockets led to preservation of soft and hard tissue<sup>5</sup>.

In the following article, both clinical cases showed bone maturation even though, keratinized, and soft tissue architecture were more enhanced in the high-density d-PTFE, ensuring a more predictable aesthetic result. Yet it is still difficult to demonstrate which membrane is superior to the other, the high-density d-PTFE showed more promising outcome.

## Conclusion

Tooth loss due to caries or trauma, results in soft and hard tissue collapse, therefore preservation of bone volume is imperative and can be done by placing bone graft material in the extraction socket covered by either non-cross linked collagen membrane or non-resorbable high density d-PTFE membrane, that showed many advantages on the soft and hard tissue regeneration level, compared to the collagen resorbable membrane. In both clinical cases patients were overwhelmed with the aesthetic results obtained.

In the light of the following technique of post-extraction socket preservation, both techniques showed reliable and predictable outcome.

We are invited today to accept the transition in using non resorbable d-PTFE membranes as part of prevention measures for bone resorption in extraction sites, due to its satisfactory aesthetic and functional results achieved in an ideal amount of time.

### Conflict of Interest

The authors declare there is no conflict of interest.

### References

1. M. Araujo, E. Linder. The influence of Bio-Oss collagen on healing of an extraction socket: an experimental study in dog. *Int J. of Periodontics and Res. Dentistry* 2008; 28(2): 123-135.
2. OhTJ, Meraw SJ. Comparative analysis of collagen membranes for the treatment of implant dehiscence defects. *Clin Oral Implants Res* 2003; 14: 80-90.
3. Barber D., Lignelli J. Using a dense PTFE Membrane without primary closure to achieve bone and tissue regeneration. *J of Oral and Maxillofac Surg* 2007; 65(4): 748-752.
4. Ghensi P. Management of the exposure of a dense PTFE (d-PTFE) membrane in guided bone regeneration (GBR): a case report. *J of Oral Implantology* 2017; 10(3): 335-342.
5. Hoffmann O., Bartee B. Alveolar bone preservation in extraction sockets using non- resorbable d-PTFE membranes: a retrospective non-randomized study. *J of Periodontology* 2008;79(8): 1355-1369.
6. Laurito D. Socket preservation with d-PTFE Membrane: Histologic analysis of the newly Formed matrix at membrane removal. *Inter J of Periodontics &Rest Den* 2016; 36(6): 111-119.
7. Mazzuchi G. Microbiological and FE-SEM assessment of d-PTFE membrane exposed to oral environment after alveolar socket preservation managed with granular nc-HA. *J of Contemporary Dental Practice* 2020; 21(4): 404-409.
8. Wen SC. Time analysis of alveolar ridge preservation using a combination of mineralized bone-plug and dense- poly-tetrafluoroethylene membrane: a histomorphometric study. *J of Periodontology* 2020; 91(2):215-222.
9. Wongpaironpanich J. Clinical efficacy of porous polyethylene membrane for alveolar ridge preservation: a pilot study. *Thammasat University,2020.*
10. Bedoya KA. Efficacy of alveolar ridge preservation with xenografts and resorbable socket sealing materials in the esthetic region: A systematic review with meta-analyses. *Clin Implant Dentistry and related research* 2023.

**Citation:** Tabarani C, Al Hijawi S. Socket Preservation Technique Using Resorbable Collagen Membrane v/s High Density d-PTFE Membrane: A must in Today's Implant Rehabilitations. A Literature Review and 2 Clinical Cases Report. *SVOA Dentistry* 2024, 5:1, 19-25.

**Copyright:** © 2024 All rights reserved by Tabarani C. This is an open access article distributed under the Creative Commons Attribution License, which permits unrestricted use, distribution, and reproduction in any medium, provided the original work is properly cited.