

Dental Forensics Due to Dental Error

Irineu Gregnanin Pedron*

Dental surgeon. Specialist in Periodontics and Implant Dentistry. Master in Dental Sciences, School of Dentistry, University of São Paulo. Undergraduate Law Student, Universidade São Judas Tadeu. Technical assistant in expertise, Brazil.

***Corresponding Author:** *Irineu Gregnanin Pedron, Dental surgeon, Specialist in Periodontics and Implant Dentistry, Master in Dental Sciences, School of Dentistry, University of São Paulo. Undergraduate Law Student, Universidade São Judas Tadeu. Technical assistant in expertise, Brazil.*

DOI: <https://doi.org/10.58624/SVOADE.2024.05.0171>

Received: March 22, 2024 **Published:** April 08, 2024

Forensic Dentistry is one of the forensic sciences and is considered part of Forensic Medicine. It is a specialized service that can assist the Judiciary in dental matters, with the purpose of elucidating legal facts (civil, criminal, administrative, labour, etc.)¹⁻⁴.

The work of the dental expert is widely publicized, thanks to the fame it has gained in the media or in the cinema, in solving *post-mortem* criminal cases¹⁻³. The main form of research in these cases is through the dental arch, which, like DNA and fingerprints, is unique to each human being. For these cases, professionals depend on the legislation in force in each country, determining the definitions of each crime¹⁻³.

However, Forensic Dentistry still works to identify iatrogenic injuries, whether caused or accidental, in living patients, producing expert reports that provide clarifying information in public and private, civil or criminal lawsuits¹⁻³.

Figure 1 illustrates the case of a Caucasian female patient, 26-year-olds, who underwent aesthetic restorative treatment with composite resin veneers. Visually, there are cervical excesses of the restorative material, which can be seen by the retention of dental floss and, mainly as a result of the latter, gingival bleeding (Figures 2 and 3, respectively).

Dental contact lenses are minimally invasive restorations with little or no preparation and a thickness of 0.2 mm. The dental surgeon can modify the shape, increase the size and reduce diastemas between teeth^{1,5,6-11}.

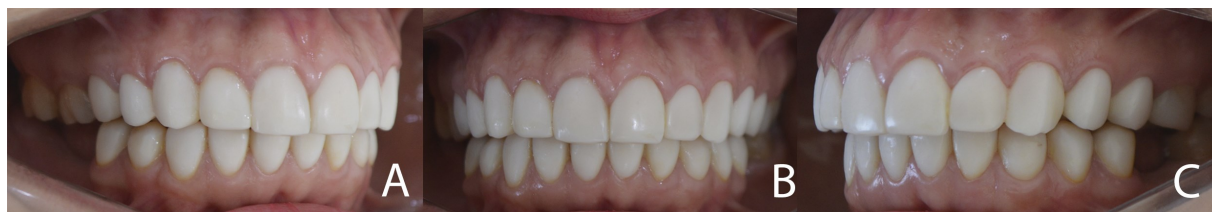

Figure 1: Clinical case showing contact lenses on upper and lower teeth, with excess in the cervical regions.

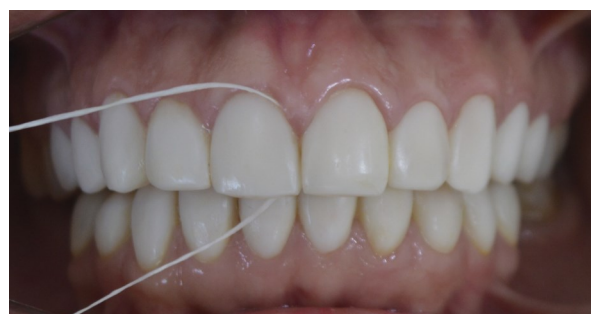

Figure 2: Retention of dental floss due to excess in the cervical region.

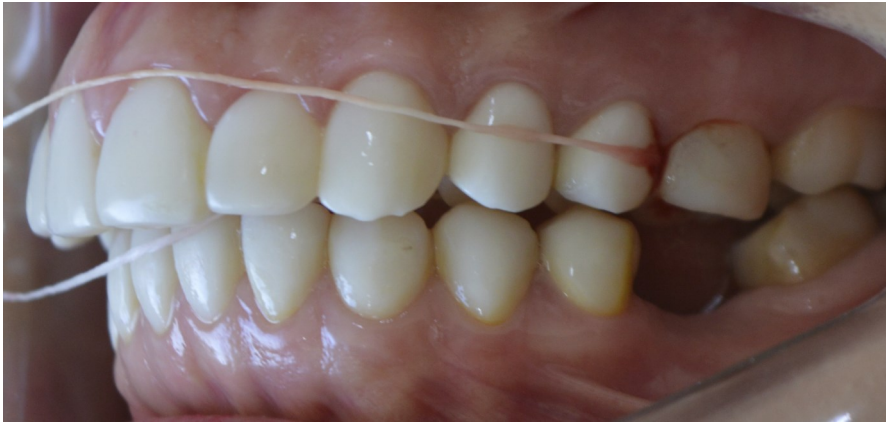

Figure 3: Gingival bleeding when flossing adjacent to cervical excess, indicating the presence of periodontal disease.

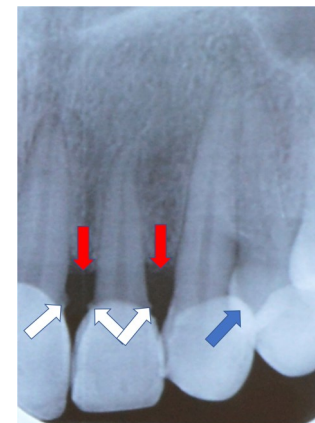


Figure 4: Periapical radiograph showing radiopaque images of dental calculus (white arrows), level of bone loss (red arrows), and cervical excesses of composite resin (blue arrow).

In this case, the presence of excess composite resin in the cervical region is a risk factor, associated with poor oral hygiene, for the onset and development of periodontal diseases. In addition, many dental surgeons do not provide oral hygiene guidance and instruction. Unfortunately, technical failures (excesses) in the execution of veneers or contact lenses, associated with the omission (negligence) of oral hygiene guidance can cause periodontal disease^{1,5}.

Radiographically, cervical excesses can be seen on periapical radiographs, panoramic radiographs (both 2D images) and computerized tomography (volumetric acquisition)^{1,5}. Figure 4 illustrates a periapical radiograph showing radiopaque images of dental calculus (white arrows), the level of bone loss (red arrows), indicating the presence of periodontal disease, probably caused by the cervical excesses of composite resin (blue arrow).

In addition, when cervical excesses of restorative material (composite resin or porcelain) are checked, contact lenses or dental veneers can cause other late complications^{1,5}.

Contact lenses or dental veneers can promote overbite, which is the vertical overlap of the upper incisors in relation to the lower incisors. When left untreated, overbites can lead to a traumatic relationship between the incisors, as well as an imbalance in the relationship between the maxilla and mandible. Secondly, patients can develop periodontal disease, interference in opening and closing the mouth, and alterations in the temporomandibular joint^{1,5,12,13}.

Altering the shape and especially the length of the teeth can cause occlusal interference, phonetic consequences, discomfort, incisal fractures or wear on the antagonist teeth^{5,14}. The lengthening of the anterior teeth, particularly the upper teeth, leads to difficulties in passive lip sealing. The absence of lip contact (even at rest) can trigger a neuromuscular imbalance that subsequently affects stomatognathic functions. In addition, the lack of passive lip sealing also contributes to mouth breathing, which in turn also increases the incidence of tooth caries and periodontal disease⁵.

Clinically, in the reported case, the treatment carried out by the dental surgeon was inappropriate and iatrogenic. The professional can be sued in various legal actions. In the civil sphere, they can be sued for civil liability, determined by material damages, moral damages and aesthetic damages. Once the unlawful act has been proven and the damage (periodontal disease with bone loss or tooth loss) and the causal link (excess veneers or contact lenses) have been established, a civil and consumer action can be brought. The unlawful act is also determined by recklessness, negligence or malpractice. In terms of criminal liability, the dental surgeon could be held responsible for bodily injury (bone loss and future loss of teeth), which could give rise to a criminal offence charge under the Penal Code^{1,2}. The professional may also face ethical and administrative proceedings.

Despite the high demand for these procedures by patients, the dental surgeon must advise them of the risks and possible complications, as well as all the precautions for carrying out the procedure (*Obligatio ad diligentiam*, from the Latin "obligation to be diligent") and post-treatment care, such as proper oral hygiene¹.

The concepts of human anthropometry seem to be totally ignored or unknown by dental surgeons, including dental, bone, facial and soft tissue measurements. This neglect favours bad practices, from case planning to execution^{1,2,15}.

Ideally, the dental surgeon should decline to carry out the treatment at the patient's request. Despite the high demand and requests from patients, the dental surgeon should explain forcefully why he or she should not carry out the treatment, since complications could develop that could lead to the patient's presentation. This preventative conduct can also provide a defence in the event of a legal problem with the patient¹.

References

1. Pedron IG, Cavalcanti RR. Forensic Dentistry and the identification of the iatrogenic lesion in the patient *in vivo*. *Scientific Archives of Dental Sciences* 2022;5(5):19-21.
2. Silva RF, Franco A, Oliveira RN, Daruge Jr E, Silva RHA. The history of forensic dentistry in Brazil. Part 1: the origin as technique and Science. *Rev Bras Odontol Leg RBOL* 2017;4(2): 87-103.
3. Ribas e Silva V, Terada ASSD, Silva RHA. The importance of the dentist's specialized knowledge into Brazilian forensic team. *Rev Bras Odontol Leg RBOL* 2015;2(1):68-90.
4. Bruce-Chwatt RM. A brief history of forensic odontology since 1775. *J Forensic Leg Med* 2010;17(3):127-130.
5. Lourenço D, Pedron IG. Orthodontic changes resulting from the application of dental contact lenses or laminate veneers". *Scientific Archives of Dental Sciences* 2023;6(2):01-04.
6. Heymann HO. The artistry of conservative esthetic dentistry. *J Am Dent Assoc.* 1987;Spec No:14E-23E.
7. Malcmacher L. No-preparation porcelain veneers. *Dent Today.* 2003;22(4):66-71.
8. Nash WR. A 6-year follow-up on cerinate porcelain veneers. *Compend Contin Educ Dent.* 1998;19(7):664-669.
9. Nash WR. The contact lens porcelain veneer. *Dent Today.* 2003;22(5):56-59.
10. Shuman I. Simplified restorative correction of the dentition using contact lens-thin porcelain veneers: a report of three cases. *Dent Today.* 2006;25(1):88-92.
11. Al-Zain A. No-preparation porcelain veneers. *Dissertação (School of Dentistry, Indiana University).* 2009:24f.
12. Nanda R, Kuhlberg A. *Tratamento da má oclusão de sobremordida: estratégias biomecânicas e estéticas na clínica ortodôntica.* São Paulo: Santos, 2007.
13. Brito HHA, Leite HR, Machado AW. Excessive overbite: diagnosis and treatment strategies. *R Dental Press Ortodon Ortop Facial.* 2009;14(3):128-157.
14. Cunha LF, Pedroche LO, Gonzaga CC, Furuse AY. Esthetic, occlusal, and periodontal rehabilitation of anterior teeth with minimum thickness porcelain laminate veneers. *J Prosthet Dent.* 2014;112(6):1315-1318.
15. Pedron IG. The proportions of the Human Figure (The Vitruvian Man) by Leonardo Da Vinci, the Anthropometry and the teeth. *Scientific Archives of Dental Sciences* 2020;3(3):10-11.

Citation: Pedron IG. Dental Forensics Due to Dental Error. *SVOA Dentistry* 2024, 5:2, 62-64.

Copyright: © 2024 All rights reserved by Pedron IG. This is an open access article distributed under the Creative Commons Attribution License, which permits unrestricted use, distribution, and reproduction in any medium, provided the original work is properly cited.