

Total Hip Replacement in Ochronosis: Case Report

Mohammed Abdul Mohammed Saied Hamad, MD, MRCSEd^{1*} and Ammar Babekir Ali Mohammed, MD¹

¹ Department of Orthopaedics & Traumatology, Sharg Alneel Hospital, Khartoum, Sudan.

***Corresponding Author:** Mohammed Abdul Mohammed Saied Hamad, MD, MRCSEd, Department of Orthopaedics & Traumatology, Sharg Alneel Hospital, Khartoum, Sudan.

DOI: <https://doi.org/10.58624/SVOAMR.2024.02.012>

Received: May 30, 2024 **Published:** June 28, 2024

Abstract

Ochronosis is not usual, it is the musculoskeletal manifestation of Alkaptonuria, a condition of abnormal metabolism of Sulphur containing amino acids which result in homogentisic acid accumulation in connective tissues due to homogentisic acid oxidase enzyme deficiency. The urine colour tends to turn into black due to oxidation in air. This is a middle-aged male in his fifties with left sided non traumatic hip pain, x-rays showed OA left hip. Intra op, we noticed the black deposits over the GT and immediately the diagnosis was clear. Urine sample was taken and left in vitro for 24 hours, the colour changed into black. Urinary homogentisic acid level is diagnostic in suspected cases, here no need to perform the test as the diagnosis was clear intra operatively. Ceramic on poly cementless THR was done. The head was preserved in formalin solution for study purposes.

Keywords: Total Hip Replacement; Ochronosis; Case Report

Introduction

Ochronosis is not usual, it is the musculoskeletal manifestation of Alkaptonuria, a condition of abnormal metabolism of sulphur containing amino acids which results in homogentisic acid accumulation in connective tissues due to homogentisic acid oxidase enzyme deficiency. (1)

The urine colour tends to turn into black due to oxidation in air. (2)

This condition is usually asymptomatic until later, when degenerative joint disease starts to develop.

Usually, patients suffer from bizarre generalized joint disease which could affect any joint, if symptomatic treatment relieved the symptoms the condition is not discovered and usually surgeons discover it intraoperatively during joint replacement when they see the blackish discoloration of the articular surfaces. (1)

Case Report

This is a middle-aged male in his fifties with left sided non traumatic hip pain, x-rays showed OA left hip. This gentleman tried all non-surgical modalities of treatment, on examination he had restricted range of motion of the left hip, especially the internal rotation and abduction with positive Trendelenburg's test and Thomas test at 20 degrees. X rays showed loss of left hip joint space and subchondral cyst (Figure 1). After counselling, the patient was prepared for total hip replacement surgery.

The spinal anaesthesia was smooth, we performed a modified lateral approach to the left hip, once the vastus lateralis sheath was opened, black pigmentation was obvious over the greater trochanter especially when the bursa was excised (Figure 2), then the abductor muscle and capsule were incised and the hip was dislocated, the femoral head was pigmented with black colour as well (Figure 3).

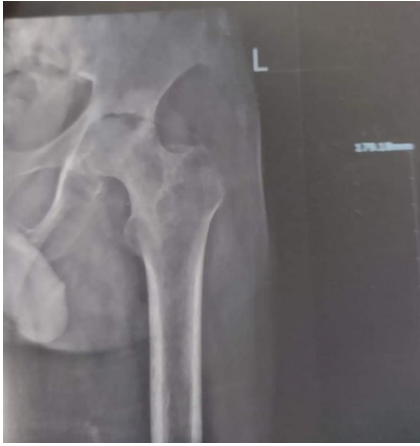

Figure 1: X-ray of the left hip, showing OA hip.

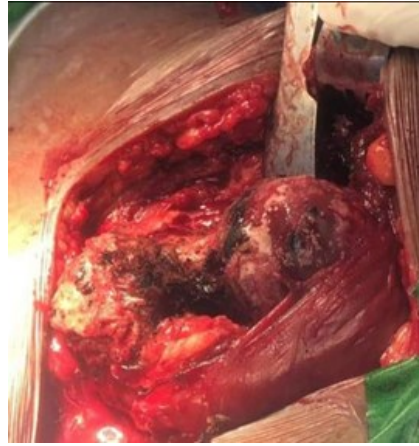

Figure 2: Black pigmentation over the greater trochanter and part of the articular surface of the hip.

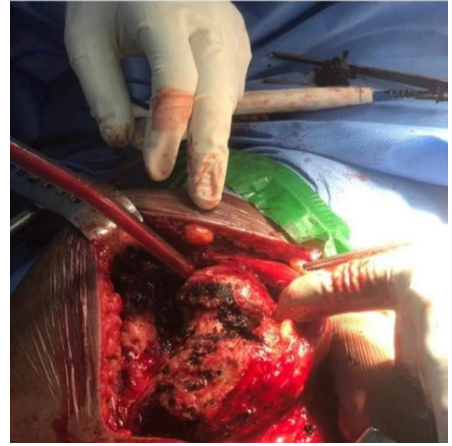


Figure 3: The left femoral head articular cartilage with black pigmentation.

The diagnosis was clear this is ochronosis, we proceeded with the surgery as there is no added risk for infection, we did a cementless ceramic on poly total hip replacement. (Figure 4)

The excised femoral head was not sent for histopathology, it was kept in formalin (Figure 5, 6), a urine sample was taken from the patient after his permission and kept for 24 hours, its colour changed from yellow to black and this confirmed the diagnosis (Figure 7,8)

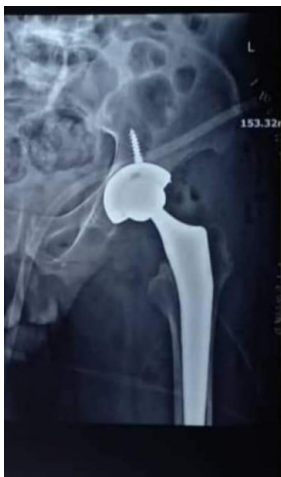

Figure 4: Left cementless ceramic on poly THR.

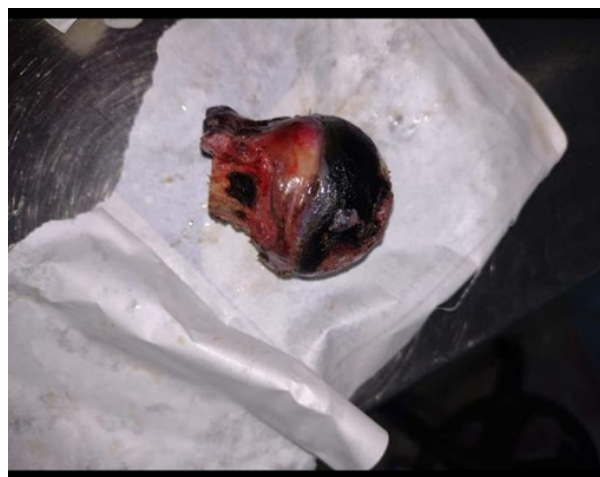

Figure 5: Excised left femoral head, note the black discoloration.

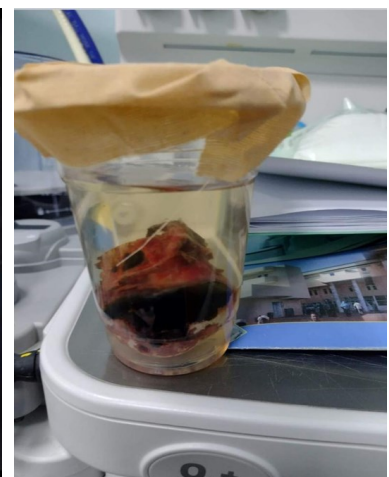


Figure 6: Excised femoral head in formalin.



Figure 7: Urine sample was collected from the patient.



Figure 8: Urine colour turned black after 24 hours.

Intra op, we noticed the black deposits over the GT and immediately the diagnosis was clear.

Urine sample was taken and left invitro for 24 hours, the colour changed into black.

Urinary homogentisic acid level is diagnostic in suspected cases, here no need to perform the test as the diagnosis was clear intra op.

Ceramic on poly cementless THR was done.

The head was preserved in formalin solution for study purposes.

Discussion

Alkaptonuria is a rare autosomal recessive inborn metabolic disorder of tyrosine metabolism due to deficiency of homogentisic oxidase enzyme. Alkaptonuria is characterized by excretion of homogentisic acid in urine, and deposition of oxidized homogeneous pigments in the connective tissues and articular cartilages (ochronosis). The gene for this pathological condition is present at locus 3q21–23 (3).

Most of those patients are asymptomatic, they are discovered later in the 4th or 5th decades (4).

Regarding the implant survival, spencer et al. concluded after follow-up of 11 joint replacements over 12 years that the joint survival rate in ochronosis is as same as in osteoarthritis, with no need for extra caution or modification (4).

Liu et al also found very good short term follow up in their case reports of hip and knees (5).

Our patient follow up was for 4 months, he was highly satisfied regarding range of motion and improvement in pain.

Pandey et al. Recommended general anaesthesia in patients with ochronosis and pre operative assessment (6), but in our case the patient spinal anaesthesia was smooth, we think if there is suspicion of ochronosis with widespread symmetrical hips, knees and spine arthritis we might consider this.

Total hip replacement has got a high success rate in ochronosis, but some surgeons would postpone the surgery and take tissues for histopathology to confirm the diagnosis (7), in our case we proceeded into the surgery and we confirmed the diagnosis with urine sample over air.

Surgical techniques are not different from the regular total hip replacement, some surgeons excise all black tissues including the capsules (8).

Conclusion

This condition is rare, some studies were done but as case reports, we still need more studies and long term follow-up. It is not always associated with skin manifestations. Diagnosis is clinical, if a middle age patient presents with multiple joint degenerative disease, suspect the condition, do clinical examination and request urine homogentisic acid level. No special precaution regarding THR, same as in OA, can be done in same session and the intraoperative clinical picture is diagnostic, histopathology will have no added information unless for study purposes. Urine sample collection is simple and cost effective and it can confirm the diagnosis and can be used as screening test for people with suspected ochronosis, before proceeding to urine homogentisic acid level.

Abbreviation

THR: Total Hip Replacement

OA: Osteoarthritis

Conflict of Interest

The author declare no conflict of interest.

References

1. Dom K, Pittevels T. Ochronotic arthropathy: The black hip. Case report and review of the literature. *Acta Orthop Belg.* 1997;63:122–5.
2. Collins EJ, Hand R. Alkaptonuric ochronosis: A case report. *AANA J.* 2005;73:41–6.
3. Janocha S, Wolz W, Srsen S, Srsnova K, Montagutelli X, Guenet JL, Grimm T, Kress W, Mueller CR. The human gene for alkaptonuria (AKU) maps to chromosome 3q. *Genomics.* 1994;19:5–8. doi: 10.1006/geno.1994.1003.
4. Spencer JM, Gibbons CL, Sharp RJ, Carr AJ, Athanasou NA. Arthroplasty for ochronotic arthritis: No failure of 11 replacements in 3 patients followed 6–12 years. *Acta Orthop Scand.* 2004;75:355–8.
5. Liu, Yikai & Li, Chenkai & Zhang, Zian & Lu, Xinzhe & Zhang, Haining. (2023). Ochronotic arthropathy effectively treated with total hip and total knee arthroplasty: a case report. *Frontiers in Medicine.* 10
6. Pandey R, Kumar A, Garg R, Khanna P, Darlong V. Perioperative management of patient with alkaptonuria and associated multiple comorbidities. *J Anaesthesiol Clin Pharmacol.* 2011;27:259–61.
7. Harun M, Hayrettin Y, Serhat M, Cuneyt M, Firat F, Ufuk O. A rare cause of arthropathy: An ochronotic patient with black joints. *Int J Surg Case Rep.* 2014;5:554–7. rare cause of arthropathy: An ochronotic patient with black joints. *Int J Surg Case Rep.* 2014;5:554–7.
8. Cebesoy O, Isik M, Subasi M, Kaya A, Bilgin F, Kaya O. Total hip replacement for an ochronotic patient: A technical trick. *Am J Case Rep.* 2014;15:27–30.

Citation: Hamad MAMS, Mohammed ABA. Total Hip Replacement in Ochronosis: Case Report. *SVOA Medical Research* 2024, 2:1, 19-22. doi: 10.58624/SVOAMR.2024.02.012

Copyright: © 2024 All rights reserved by Hamad MAMS. This is an open access article distributed under the Creative Commons Attribution License, which permits unrestricted use, distribution, and reproduction in any medium, provided the original work is properly cited.