

## Limbic Encephalitis Presenting with Faciobrachial Dystonic Seizures After History of Successfully Treated Thymoma Type B-3 with Excellent Neurocognitive Outcome with Early Immunotherapy

Usaamah M. Khan MD<sup>1\*</sup>, Matthew Anderson MD<sup>2</sup> and Victor H. Gonzalez Montoya<sup>3</sup>

### Affiliation:

<sup>1,2,3</sup> Virginia Commonwealth University Health System, USA

\*Corresponding Author: Usaamah M. Khan MD, Virginia Commonwealth University Health System, USA

Received: January 25, 2021 Published: March 01, 2021

### Abstract

Paraneoplastic Encephalitis syndromes are an inflammatory condition of the brain and central nervous system often associated with cancer diagnoses. In many cases, the paraneoplastic encephalitis is often the initial presentation for an underlying cancer. Limbic encephalitis, a form of paraneoplastic encephalitis, involves inflammatory changes specific to the limbic structures such as the hippocampi, hypothalamus, and limbic cortex. Numerous paraneoplastic and limbic encephalitides have been studied and associated with specific anti-body associated autoimmune processes. Anti-LGI1 encephalitis, is a form of limbic encephalitis associated with antibodies to the LGI1 protein and can present with stereotypical faciobrachial dystonic seizures (FBDS). We describe a case of FBDS in a patient with prior history of treated Thymoma Type B-3, who presented with faciobrachial dystonic seizures. Patient was found to have Anti-LGI1 antibodies on paraneoplastic work up and treated with intravenous immunoglobulin with remarkable response and continued improvement with seizure control and neurocognitive outcome with immunotherapy.

**Keywords:** Limbic Encephalitis, Thymoma Type B-3, FBDS, Immunotherapy

### Introduction

Encephalitis refers to the inflammatory state of the brain which can result from numerous etiologies but most commonly includes infectious such as viral meningitides, or autoimmune encephalitic processes. Patients typically present with impairment in mental status, consciousness and often associated with focal and/or generalized seizures. Autoimmune encephalitis results from antibody mediated inflammation of the brain due to antibodies that target neuronal cell surface proteins. Paraneoplastic encephalitis, a form of autoimmune encephalitis associated with various cancers, result from antibodies targeting intracellular neuronal proteins, also known as onconeuroproteins. In addition to the clinical spectrum of altered mentation, seizures, and supportive neuroimaging suggestive of encephalitis, cerebrospinal fluid and serum analysis for specific antibody markers can guide the diagnosis of paraneoplastic encephalitis and typically precedes the identification of an underlying cancer diagnosis.

Anti-LG1 encephalitis is a paraneoplastic encephalitis involving mostly the limbic structures of the brain and associated with faciobrachial dystonic seizure (FBDS). Faciobrachial dystonic seizures present with unilateral, intermittent dystonic posturing of the upper limb and face often preceding a course of limbic encephalitis and are associated with Anti-LGI1 antibodies. We present a case of limbic encephalitis in a patient with remote history of resected thymoma type B-3 who presented with convulsive seizures and FBDS raising clinical suspicion for limbic encephalitis. The early clinical suspicion of a paraneoplastic encephalitis diagnosis and timely treatment with immunotherapy resulted in resolution of not only the FBDS but significant objective improvement in long term neurocognitive outcomes. The case highlights the importance of a high index of suspicion for paraneoplastic encephalitis in patients with FBDS and the success with early initiation with immunotherapy.

### Case Description

A 44-year-old male with a remote history of confirmed resected thymoma type B-3 presented with generalized convulsive tonic-clonic status epilepticus. EEG demonstrated a right temporal focus with secondary generalization. CT head and extensive infectious, metabolic, and toxic workup were unrevealing. Patient was discharged on levetiracetam and phenytoin with unclear etiology of the seizures. A month later, he was admitted to the epilepsy monitoring unit with memory loss, cognitive changes, and jerking episodes of the left arm and face occurring up to sixty times daily. Patient was noted to have multiple independent bi-temporal seizure foci without any scalp EEG correlate to the dystonic movements (figure 1). MRI brain revealed generalized volume loss and CSF analysis showed a glucose of 75, protein of 27, WBC 11.8. The clinical suspicion for FBDS raised concern for limbic encephalitis and swift treatment with his dose steroids followed by intravenous immunoglobulin was initiated.

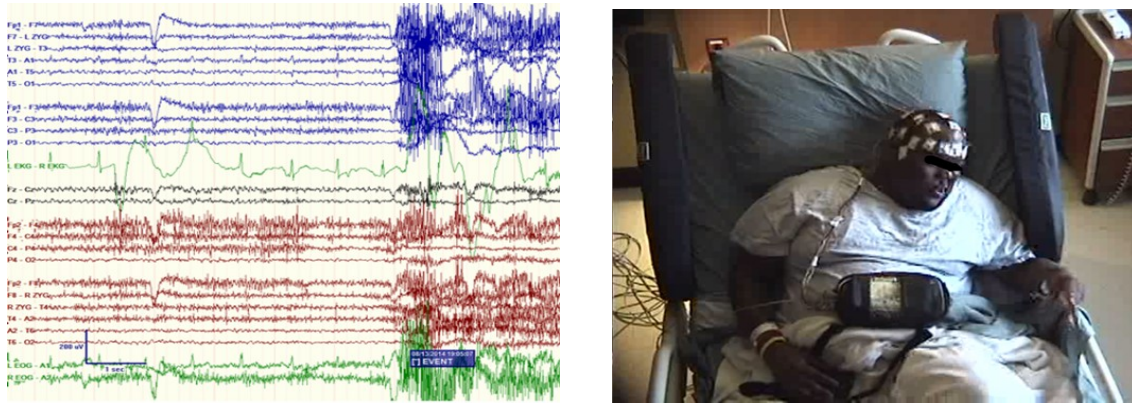


Figure 1. Dystonic Seizure involving face, arm and leg with no evidence of EEG Correlate.

### Results

Brain PET scan demonstrated hypermetabolic activity in the bilateral basal ganglia and other limbic structures, extensive autoimmune and paraneoplastic workup were otherwise negative. The patient had relatively rapid improvement of the seizures and the dystonic episodes with immunotherapy which consisted and a course of IV steroids followed by intravenous Immunoglobulins (IVIg). He was discharged on levetiracetam, topiramate, and clonazepam. Autoimmune antibody panel later returned positive for both Anti-LGI1 and Anti-GAD antibodies establishing the diagnosis of FBDS in the setting of limbic encephalitis. He was treated with monthly IVIg for a year with successful down titration to topiramate monotherapy. A repeat whole-body PET scan at one year was normal and the patient has remained tumor free for 7 years.

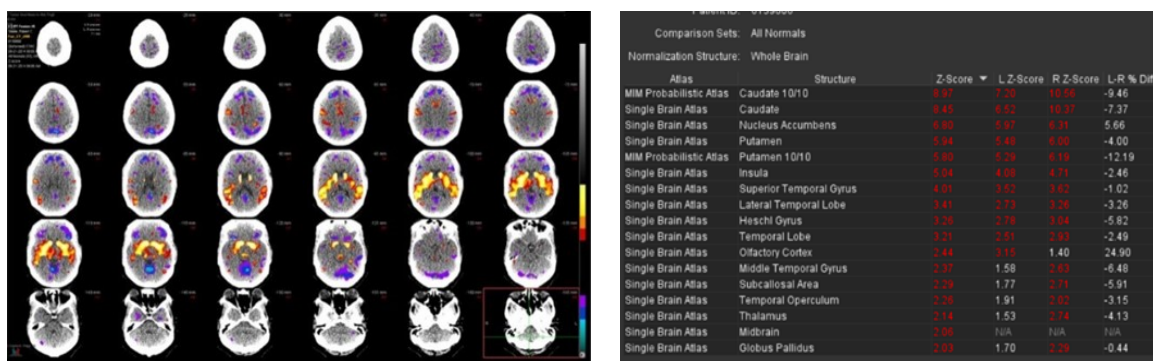


Figure 2: Brain Positron Emission Scan demonstrating hypermetabolic activity in the bilateral basal ganglia

Encephalopathy Panel (8/15/2014)		Encephalopathy panel (10/02/2014)	
• VGKC Ab CSF	(-)	• VGKC Ab serum	(+)
• ANNA type 1, 2, 3 CSF	(-)	• GAD Ab serum	(+)
• PCA 1, 2, Tr CSF	(-)	• GABA B Receptor Ab serum	(-)
• Amphiphysin Ab CSF	(-)	• AMPA Receptor Ab serum	(-)
• CRMP CSF	(-)	• ANN Ab type 1, 2, 3 serum	(-)
• NMDA Ab serum	(-)	• AGN Ab type 1 serum	(-)
• Anti Ma1 serum	(-)	• PCA 1, 2, Tr	(-)
• Anti Ma 2 serum	(-)	• CRMP serum	(-)

Figure 3: Autoimmune and Paraneoplastic Panel

## Discussion

Leucine-rich glioma inactivated-1 (LGI1) encephalitis is an autoimmune paraneoplastic encephalitic syndrome characterized by auto-antibodies against voltage-gated potassium channels (VGKC). Its primary affects adults older than 30 years old. Those affected may present with stereotypical faciobrachial dystonic seizures (FBDS). These are unique seizures described as frequent and brief dystonic movements of the face, neck and arm. Alternatively, patients may present with other non-specific symptoms such as seizures or confusion and only develop FBDS later in the disease course. If not recognized early, seizure frequency may increase and cause lasting cognitive deficits, severe amnesia, and hyponatremia.

Early clinical recognition of FBDS is crucial in preventing the long-term sequelae. Ancillary test such as EEG and MRI may not be diagnostic, though can be somewhat helpful. FBDS often do not correlate on EEG (Figure 1) and MRI is often normal. CSF encephalitis panels that test for LGI1 antibodies aid with diagnosis but require time to result. Fluorodeoxyglucose positron emission tomography (FDG-PET) may show altered glucose metabolism, but the location varies and is not specific to LGI-1 encephalitis. In our patient, the FDG-PET prior to treatment (Figure 2) did in fact demonstrate significant involvement of the limbic structures further confirming the paraneoplastic limbic encephalitis. A repeat PET scan at a year interval demonstrated resolution of these findings. As this is an autoimmune condition, response to anti-epileptic drugs is poor and without appropriate immunotherapy seizure can be refractory. Patients should therefore be treated early with immunotherapy. Of note, another important factor to highlight in this case, is the patient was diagnosed with paraneoplastic encephalitis years after a diagnosis and treatment of a prior thymoma without interval recurrence of the cancer. Paraneoplastic encephalitides are often times associated with new diagnosis of cancer however as this case suggests, prior treatment of cancer, which is in remission, should still raise suspicion for paraneoplastic syndromes in a patient presenting with autoimmune encephalitis.

## Conclusion

Autoimmune encephalitides present with a complex constellation of neurological symptoms, rendering diagnosis and management challenging. There can be lasting consequences including seizures and cognitive deficits if not recognized early. Though antibody markers allow confirmation of autoimmune encephalitis, early treatment with immunotherapy is paramount if Anti-LGI1 Limbic Encephalitis is suspected clinically. Our patient presented with FBDS and was rapidly treated with IVIG and has remained seizure free for 7 years with no residual cognitive deficits on repeat neuropsychiatric testing.

## References

1. Irani, Sarosh R, et al. "Faciobrachial Dystonic Seizures Precede Lgi1 Antibody Limbic Encephalitis." *Annals of Neurology*, vol. 69, no. 5, 2011, pp. 892–900.
2. Binks, Sophie N M, et al. "LGI1, CASPR2 And Related Antibodies: a Molecular Evolution of the Phenotypes." *Journal of Neurology, Neurosurgery and Psychiatry*, vol. 89, no. 5, 2018, pp. 526–534.
3. Iyer, Rajesh Shankar, et al. "Faciobrachial Dystonic Seizures Result from Fronto Temporo-Basalganglial Network Involvement." *Epilepsy & Behavior Case Reports*, vol. 8, no. C, 2017, pp. 47–50.

**Citation:** Usaamah M. Khan MD, Matthew Anderson MD and Victor H. Gonzalez Montoya "Limbic Encephalitis Presenting with Faciobrachial Dystonic Seizures After History of Successfully Treated Thymoma Type B-3 with Excellent Neurocognitive Outcome with Early Immunotherapy ". *SVOA Neurology* 2:2(2021) Pages 44-46.

**Copyright:** © 2021 All rights reserved by Usaamah M. Khan MD et al. This is an open access article distributed under the Creative Commons Attribution License, which permits unrestricted use, distribution, and reproduction in any medium, provided the original work is properly cited.