

# Colloid Cysts of The Third Ventricle: The Surgical Experience of a Single Institution

Chafik HANDIS<sup>1</sup>, Yacine FELISSI<sup>1\*</sup>, Salim MEZIANI<sup>1</sup> and Abdelhalim MORSLI<sup>1</sup>

<sup>1</sup> Algiers University/Faculty of Medicine, Department of Neurosurgery, Mohamed Lamine Debaghine University Hospital, Algiers, Algeria.

\*Corresponding Author: Dr. Yacine FELISSI, Algiers University/Faculty of Medicine, Department of Neurosurgery, Mohamed Lamine Debaghine University Hospital, Algiers, Algeria

Received: July 23, 2021 Published: August 13, 2021

## Abstract

Third ventricular Colloid cysts are benign cysts, located deeply in the diencephalic region. open microsurgical, endoscopic, stereotactic aspiration techniques are possible for achieving good outcomes with considering the right surgical indication. We report the results of 40 patients operated on during 22 years in a north African institution. our study group was composed of an adult subgroup of 33 patients and a pediatric subgroup of 7 patients. the age ranged from 13 to 56 years. The most encountered symptom was chronic headaches in 30 patients. All the patients received an open microsurgical technique for tumoral resection as an ultimate surgical step. 6 Patients were shunted in our department or elsewhere then referred for surgical removal. "The transcallosal transforaminal approach" was the most used in 30 patients. this was due to its flexibility, anatomical preservation of structures, and reduced postoperative risks. Several extensions through the choroidal fissure and the fornix were applied for specific cases. Total resection was achieved in 32 patients and was subtotal in the rest. Tumoral recurrence was noticed in 5 patients and only three symptomatic and available patients were reoperated and completing than a total resection. At the beginning of our experience, we had two cases with definitive recent memory loss. Microsurgical techniques through open approaches could achieve total resection without significant morbidity when it's conducted by an experienced surgeon. Maximal attention and preservation of the venous system and the fornices must be present to complete a perfect surgery without neurocognitive complications. The ability of growth and recurrence depending on the consistency of the cyst must be considered as another field for further research.

**Keywords:** Colloid cyst, transcallosal transforaminal, microsurgical.

## Introduction

Colloid cysts are benign lesions, having an endodermal origin(1) and most frequently encountered in the third ventricle. they account for only 0.5 to 1% of all brain tumors (2) and represent the most frequent neoplasm of the third ventricle. The first successful surgical removal of a colloid cyst was performed by Dandy in 1921, using a posterior transcallosal approach(2).

Although this cyst remains asymptomatic or slightly remarkable in patients during a long period, the expression is dramatically marked by coma or even sudden deaths in few cases (3, 4). This heterogeneous course of events is related to its anatomical features. Most of them are attached to the roof of the third ventricle, close to the foramen of Monroe, and may lead to chronic or acute hydrocephalus by the obstruction of the CSF (Cerebrospinal Fluid) flow at this level.

One of the treatment options for asymptomatic patients is observation and serial neuroimaging during follow up (5). Spontaneous resolution of an almost incidentally discovered colloid cyst was reported (6, 7).in the other hand, Several surgical modalities were used; bilateral shunting in the acute period, transcranial approaches, recently endoscopic cyst resection(8, 9), or even stereotactic cyst aspiration (10, 11) in few cases.

Both microsurgical techniques; "transcortical" or "transcallosal " combined to their different extensions through the choroidal fissure can be used to access this deep part within the diencephalic region without significant morbidity or mortality(12). Despite the success of these approaches, Anterograde amnesia was described as a postoperative sequela when the fornix was damaged during cyst dissection(13).

Our work is a retrospective study of patients operated on a colloid cyst in our department. we reevaluated clinical characteristics, neuroimaging features of the cyst, and surgical indications and techniques. Immediate complications and long-term sequela were also reported in this paper. Our secondary aim is to share the experience of our institution in the management and follow-up of a colloid cyst.

## Materials and Methods

Our work is a retrospective study of 40 patients harboring colloid cyst and operated in the department of Neurosurgery (Mohamed Lamine Debaghine University hospital Algiers- Algeria). The period of study is from 1998 till 2020. the Medical files and histological reports confirming the diagnosis of all patients were reviewed. the clinical status at presentation was assessed using the GCS (Glasgow Coma Scale). The memory troubles were classed into slight, moderate, and severe. All patients had “open microsurgical techniques” as a surgical modality. All details concerning the choice of the approach were reviewed. Immediate and long-term complications were analyzed and their origin was raised.

### Analysis of patient's group and results:

#### Age and sex

During 22 years,40 patients were operated on for a third ventricular colloid cyst, 12 of them were female. Most of the patients were males with a percentage of 70%. we had a pediatric population subgroup of 7 patients (4 patients are female). The age of patients ranges between 13 and 56 years.

#### Clinical presentation

The main clinical presentation for all patients was headaches in 38 patients. this symptom was included either in an increased intracranial pressure syndrome (8 patients) or in more a chronic form for several months (30 patients).in the chronic forms, other signs could be concomitant with headaches as seizures (1 patient), drop attacks in lower limbs (4 patients), vertigo (2 patients), blurry vision (3 patients), memory disorders (3 patients).in two cases, the diagnosis was incidental. (table1).

Clinical symptom	Number of patients
Headaches	<b>38</b>
Headaches in an <b>IICP Syndrome</b>	8
Headaches in a <b>chronic form</b>	30
Blurry vision	3
Seizures	1
Drop attacks in lower limbs	4
vertigo	2
memory disorder	3
Incidental (asymptomatic)	<b>2</b>

IICP: increased intracranial pressure.

**Table 1: Repartition of symptoms**

#### Radiological Evaluation

All of our patients had preoperative MRI imaging. in **one** case, data of imaging was not found. The intensity on both T1, T2 sequences and diameter were calculated.

In **39 patients**, The diameter of the cyst ranges between 7 and 33 mm. (table 2)

Diameter	Number of patients
5-10mm	3
11-15mm	<b>13</b>
16-20mm	<b>12</b>
21-25mm	6
26-30mm	3
31-35mm	2

**Table 2: Number of patients according to the cyst size.**

The main diameter of a cyst at diagnosis time ranges between 11-15mm (13 patients), and between 16-20 mm in 12 patients. only two patients had a cyst diameter greater than 31mm.

The intensity of the cyst was evaluated in 37 patients (in the 3 remaining patients, the radiological data were incomplete) on both T1 and T2 sequences. (Table 3).

Cyst signal (T1-T2)	Number of patients
<b>Hypointense- hyperintense</b>	<b>11</b>
Hypointense-isointense	2
<b>Hyperintense -hypointense</b>	<b>10</b>
Hyperintense -hyperintense	3
Hyperintense-isointense	3
Isointense -hyperintense	3
Isointense -hypointense	3
Isointense -isointense	2

**Table 3: Number of patients according to the intensity of the cyst.**

The consistency of the cyst was liquid in 11 patients and this aspect was confirmed in surgery. In 10 other patients, the content of the cyst was more solid because of the high concentration of proteins. The aspect of the cyst had an important impact on difficulties encountered in surgery especially of more solid forms of these cysts.

#### **Surgical procedures:**

##### **(a) Shunting in the first step of management**

6 patients were shunted at the initial stage (in our department or elsewhere) of their management and all of them presented to emergency complaining of severe headaches and vomiting (IICP Syndrome).

In the same group of patients, consciousness disorders were not significantly noticed and no patient was received in a comatose status. another patient had a puncture of the lateral ventricle through a frontal burr hole to relieve acute symptoms.

##### **(b) Tumor removal**

The main surgical technique that was used in our patients was the “transcallosal **purely** transforaminal approach” (**30 patients**). This approach is the most mastered and familiar in our department. In this technique, only one anatomic structure was partially sectioned. it was used in the patient that was shunted initially or didn’t present a ventricular dilation on the preoperative imaging. 5 patients of the shunted group had a transcallosal transforaminal approach.

“The transcallosal interforniceal” approach was the second technique that was adopted in (**03**) three patients. the progression was done between the anterior columns of the fornix. They were in normal or in a distorted position due to the tumor. This surgical procedure was used mainly in very rare situations where the cyst had more a superior growth direction between the two fornices, filling the space between the two layers of the septum pellucidum and bulging immediately under the corpus callosum.

In **02 patients**, a transcortical Transventricular route was used to gain the tumoral process. in both cases the ultimate steps of microdissection were done through the foramen of Monroe. in **02** other patients, the procedure necessitated a widening of the approach to the choroidal fissure in a “trans choroidal” way. Both of these approaches were mostly used in patients presenting hydrocephalus making then the progression through the cortex and ventricles easier.

In one patient, the approach was transcallosal sub-choroidal.

In one atypical case, the tumor had a truly posterior insertion in the roof of the third ventricle with an extension into the quadrigeminal cistern. A suboccipital transtentorial approach was performed in this case. the resection was subtotal and the patient was lost after 6 years of follow-up.

In one case, the medical file was incomplete concerning details of the surgery. (Table 4)

Surgical approach	Number of patients
Transcallosal transforaminal (purely)	30
Transcallosal interforaminal	3
Suboccipital transtentorial	1
Transfrontal transventricular (transforaminal)	2
Trans frontal transchoroidal	2
Transcallosal sub choroidal	1

**Table 4: Repartition of the surgical techniques used in the study.**

### **Quality of tumoral resection**

we had mainly two groups of patients:

- Patients with “total resection (TR)”: as defined by total removal of the contents and the cyst wall. this was confirmed intraoperatively (surgical field) and MRI imaging at three months of follow-up. this quality of resection was achieved in **32 patients**.
- Patients with “subtotal resection (SR)”: this resection was defined by total removal of the contents of the cyst and a partial resection of its wall. this was achieved in **8 patients**.

### **The Postoperative period**

#### **(a) Immediate and early status:**

This period extends from the early hours after surgery to the last day of admission.

A good early postoperative status is defined by an uneventful course after surgery, without usual complications of brain surgery as hematoma, seizures, meningitis, or early consciousness disorders. Even other functional notable complications were also included.

- **28 patients** had a good status, with an excellent clinical and functional evaluation, and they were discharged between 7 to 10 days after surgery.

We have noticed these complications in the studied group:

- **4 patients** had memory disorders. (2 at a slight degree and 2 at a severe degree).
- **1 patient** presented meningitis that was successfully treated medically
- **2 patients** had a postoperative fistula that was well managed.
- **1 patient** had an acute subdural hematoma that was reoperated.
- In **one** pediatric case with an unusual anatomic location of the cyst, the patient presented an epidural hematoma for which he was reoperated the same day. he had also vertical diplopia due probably to surgical dissection of the cyst at the level of the quadrigeminal plate.
- In **2 patients** we had a significant infarct in the prefrontal area with edema that was an origin of seizures and behavior disorders in one patient and hemiparesis in the other. both of the patients had a transcallosal surgery, where a parasagittal precorneal vein was sacrificed to allow further progression of dissection and cyst resection.
- The most severe complication in our series was death in **one patient**. in this case, all the surgical steps of a transcallosal transforaminal approach were conducted excellently and the cyst was removed. the hemostasis was obtained successfully. at the moment of lifting the retractor, a significant amount of blood came up at the lateral to the callosotomy and most probably from one pericallosal artery. despite the control of bleeding, the patient was maintained intubated and control CT showed edema and important ventricular blood. an external drainage was placed for him, but the further course was dramatically marked by death 3 days after.

#### **(C) Clinical status at 3 to 6 months after surgery:**

All of the patients were present at their control of 1,2,3,6 months after surgery. both radiological and clinical status were evaluated.

- Only 5 patients had residual deficit after surgery at this time of control.
- 2 of them had severe memory disorders that didn't resolve despite long-term follow-up.

- For the two other patients, we noticed that slight memory disorder resolved in 6 months for one patient and in two years for the other one.
- The vertical diplopia in one of the patients of the pediatric subgroup resolved 6 months after surgery.
- We don't have exact data about further controls of patients after 6 months, because of the heterogeneous criteria of inclusion. A significant number of patients (those with a good evolution) were not present at their programmed schedule. On the other hand, all patients with a recurrent cyst profile consulted even in not programmed dates.

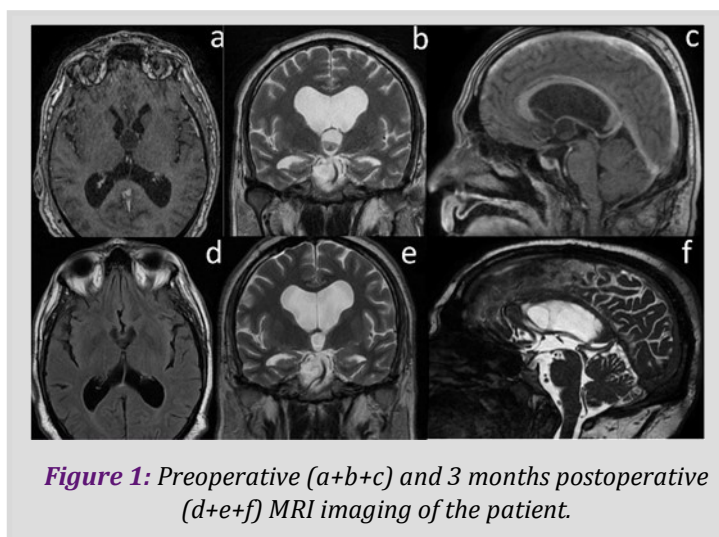
### Recurrence

We have noticed five patients that presented cyst recurrence in our studied group. most of them had initially a subtotal resection (04 patients). The last case had initially an apparent total resection. the delay recurrence varied from 1.5 years to 3 years. Only three patients were reoperated using a transcallosal approach and remained stable. for the two other cases, they were asymptomatic with a stable cyst remnant on serial imaging. we don't have precise data concerning the initial cyst consistency of these patients.

### Illustrative cases:

#### Case 1

A male aged 45 years, that presented 3 months before his consultation to our department an IIP syndrome for which he was investigated and operated for biventricular hydrocephalus. He had a VP shunt then referred to our department for further investigation and surgical management. He was awake and presenting a "Burns Syndrome" and slight memory disorders.



**Figure 1:** Preoperative (a+b+c) and 3 months postoperative (d+e+f) MRI imaging of the patient.

**a:** axial T1 sequence + contrast that shows isointense cyst with normal ventricular size. **b:** coronal T2 section; a heterogeneous cyst mainly with a hyperintense content and a minimal hypointense content. the insertion is at the level of interventricular foramina. **c:** sagittal T1 +contrast sequence shows a non-enhancement of the cyst wall. **d:** axial FLAIR sequence; a total resection of the cyst without any notable vascular events. **e:** coronal T2 sequence showing complete removal of the cyst. **f:** T2 sagittal sequence showing a total removal through a transcallosal approach (callosotomy at the anterior part of the corpus callosum).

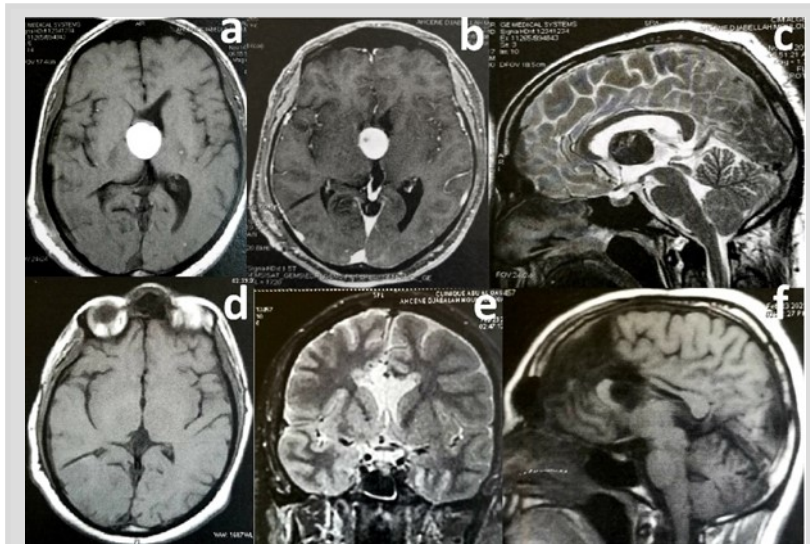
The patient was reoperated three months after the first surgery (VP shunting). He had a total resection of the cyst through a transcallosal purely transforaminal approach. we didn't notice specific events in this patient. the contents of the cyst were a mix, a liquid part (hyperintense on T2 sequence), and a second part in the depth of the cyst that was moderately viscous. both of them were aspirated and removed. the cyst wall was carefully dissected through the open foramen of Monroe. the two cerebral veins well-controlled and protected during dissection. The immediate and long-term status was excellent and no recurrence was noticed five years later radiological investigation (figure 1).

#### Case 2

A male of 27 years came up to emergency when he had an acute worsening of previous headaches. the MRI showed biventricular hydrocephalus and a cyst at the level of the third ventricle. he was admitted in a confused status to the OR and operated on successfully.

This patient is presenting a colloid cyst significantly large (a subgroup of two patients with a diameter of 31-35mm). the cyst appearance (hypointense on T 2, highly hyperintense on T1) is compatible with an elevated viscosity of the cyst. this data is an important parameter that could avert the surgeon and even influence the surgical strategy, especially when considering endoscopic or stereotactic procedures.

The transcallosal transforaminal approach was adopted for him. The notable difficulty that was encountered is the presence of a developed network of parasagittal veins making the surgical progression difficult. This prompted us to sacrifice one of them. Further steps were conducted, and the cyst was reached. the waxy content of the cyst was removed with microsurgical instruments and considering both the fornix and the internal cerebral veins. the dissection was through the foramen. Despite the gentle dissection, the columns of the fornix could be manipulated at some moment of surgery.



**Figure 2:** Preoperative (a+b+c) and postoperative (d+e+f) MRI of the patient

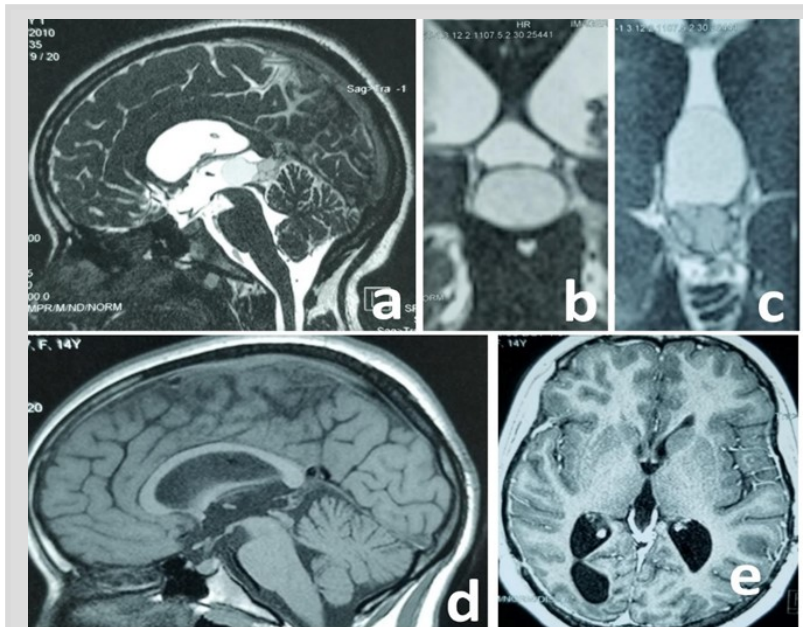
**a:** axial T1 MRI sequence that shows a spontaneously hyperintense third ventricular cyst without enhancement after gadolinium injection **b. c:** the cyst is hypointense on T2 sagittal sequence. An important part of the cyst is close to the foraminal space. **d:** axial T1 sequence showing a total resection of the cyst; this also was confirmed on coronal T (**e**) and sagittal T1 (**f**) sections. The location and size of the callosotomy are clear in the last image (**f**).

The immediate postoperative period was good. two days after, he presented behavioral troubles and urinary incontinence, which were included in a frontal syndrome. This is a consequence of a frontal venous infarct. he also complained of recent memory disorders that were related to surgical traumatism of the fornix.

We noticed an improvement in his behavior before we discharged him but the amnesia stayed till the 6<sup>th</sup> month of follow-up. At one year after surgery, the patient had total remission of these troubles. the size of the callosotomy looks slightly larger and posteriorly placed than usual and this is due to the need for visualization of blind spots of the large cyst during surgery.

### Case 3

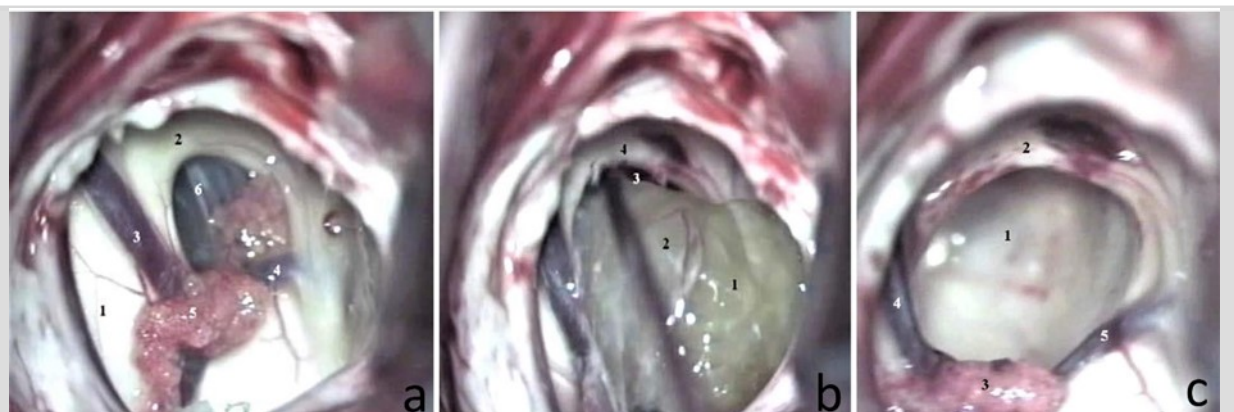
A child of 13 years, who complained of a worsening of headaches. and in a short period of one week. In addition to that, he had some ocular movement disorders. the first radiological investigation revealed biventricular hydrocephalus. The fundus examination revealed significant papillary edema. This patient had a primary relief of the triventricular hydrocephalus by a ventriculoperitoneal shunt that was placed in another institution. She complained of severe headaches a few hours after surgery. the CT showed an epidural hematoma that was operated on successfully.



**Figure 3:** Preoperative (a+b+c) and postoperative (d+e) MRI of the patient

**a:** sagittal T2 MRI sequence that shows a spontaneously hyperintense third ventricular cyst, located in the posterior part with an extension to the quadrigeminal cistern. **b:** coronal T2 sequence: the cyst is hyperintense with a posterior position at the level of the atrium. **b:** Axial T2 sequence shows a multicystic lesion with an apparent solid part at the posterior part. **d:** sagittal T1 sequence showing a subtotal resection of the cyst; notice the residual part at the quadrigeminal cistern, beneath the corpus callosum. **e:** axial T1 +gado sequence shows an acceptable tumoral resection. the postoperative MRI was performed one year after surgery.

After her admission to our department, the analysis of the MRI showed a tumoral process with more than one cystic compartment filling up mainly the posterior part of the third ventricle. the cyst had a clear extension to the quadrigeminal cistern under the corpus callosum. due to the anatomical location, the size, and the extension of the cyst, we have performed a suboccipital transtentorial approach for tumoral resection. the surgery achieved a subtotal resection of the cyst. The solid contents of the cyst were removed but the tumoral wall was adherent in some angles to critical structures at the level of this region. Despite our conservative attitude, she presented vertical diplopia and this was due to the dissection at the level of the quadrigeminal plate close to the colliculi. The histological analysis revealed a colloid cyst. The diplopia regressed at 6 months follow-up. the atypical radiological aspect of the cyst and the age of the patient was the specific parameters of this illustrative case. the flexibility of the surgeon's mind must be considered by using an atypical approach for an unusual colloid cyst.



**Figure 4:** a+b+c: Microsurgical preoperative views of the transcallosal transforaminal approach.

**a:** after the callosotomy, the foramen of Monroe is visualized after following the choroid plexus (5), the septum pellucidum (1), and the anterior column of the fornix (2) that forms the anterior border of the foramen are also exposed. the anterior septal vein (3) course along the septum (1). The thalamostriate vein (4) is having a lateral course in the right lateral ventricle. the colloid cyst (6) is projecting in the direction of the interventricular foramen. **b:** the phase of cyst removal through the foramen (3) using microdissector. We have noticed a mixed consistency of the cyst (1+2) viscous and slightly solid one. maximal preservation of critical structures is mandatory especially the fornix (4). **c:** the final view of the third ventricle through the foramen (1) and good preservation of the thalamostriate vein (5), the septal vein (4). Choroid plexus (3).

## Discussion

### ***Incidence and origin:***

Colloid cysts are benign lesions, encountered mostly in the third ventricle and located close to the foramen of Monroe. they account for only 0.5-1% of all intracranial tumors (14).

The pathologic formation of these cysts remains unclear. The paraphyseal origin was evoked firstly by Sjoval in 1909 (15). the paraphysis is a glandular tissue that appears at the seventy-fifth day of gestation and disappears shortly after (16).

In another valuable work(17), the authors reported immunohistochemical data on an already excised colloid cyst in several regions; the third ventricle, Cerebellopontine angle, and finally the Sella. the pathological tissue showed positive staining for epithelial membrane antigen (EMA), tissue polypeptide antigen (TPA), and epidermal keratin (EK). the only negative staining was the S-100 protein. All of these parameters are suggesting the endodermal origin of the cyst (17). in a study of the ultrastructure of the colloid cyst, it was found that they are composed of ciliated or non-ciliated and even columnar cells. These cells are interspersed with other cells that contain mucus (1). This formation secretes a proteinaceous material, grows, and be symptomatic when they block the interventricular foramen.

Colloid cysts are also called “Neuroepithelial cysts”, and this is by considering their origin. The neuroepithelium of the diencephalic region may undergo two types of the process; the first is an invagination into the third ventricle or and the second is an evagination into the roof of the third ventricle more precisely into the velum interposition(18). Despite that the subject of colloid cyst origin is controversial, the main idea that could be retained is the benignity of the tumor. good outcomes and quality of life are achievable if the surgery respects the anatomical structure and is conducted by an experienced team.

### ***Clinical presentation:***

In the present series, almost all patients were complaining of headaches (95% of the study population). Two semiological subgroups were identified; headaches were chronic with a significant preoperative evolution ranging from 2-48 months. the signs concomitant with headaches were; seizures (2.5%), drop attacks in lower limbs (4%), vertigo (5%), blurry vision (7.5%), memory disorders (7.5%). For the second subgroup (8 patients), the headaches were included within an increased intracranial pressure syndrome. We didn't have cases of a patient admitted in a comatose status, dead before surgery, or during the follow-up period.

The headaches were present in 56% of patients that were selected for transcranial approach in the barrow neurological institute study, and they had 5 cases of an incidental diagnosis of the cyst. the same symptom was more frequent in patients that had endoscopic cyst resection with a percentage of 75% in the same work (4). In another retrospective study, headaches were present in 74 % of patients. The clinical presentation was more detailed; the drop attacks and memory disturbances were present in 3.4%, 7% of patients respectively(19). Brostigan and colleagues reported that most of their patients (97%) had a previous history of headaches. In the same group; memory deficits were present in 13% of patients(20).

Most of the reported values in these works are almost similar to our series. The pathological mechanism of this symptom is the intermittent obstruction of the foramen of Monroe by the cyst in the so-called “ball-valve mechanism”. the interruption of the CSF flow in an abrupt way could produce acute hydrocephalus and even sudden death due to a brain herniation in other cases. The centers of the cardiovascular system close to the third ventricle may also be affected by the cyst and induce this fatal consequence (21, 22).

### ***Radiological parameters:***

Both CT and MRI are valuable tools in the diagnosis of colloid cysts, and the availability of these imaging modalities is increasing the discovery rate of these cysts in asymptomatic patients.

In CT, most colloid cysts are rounded or oval and appear hyperdense compared to the brain tissue, but the other densities; hypo and isodense are also encountered. the peripheric annular enhancement in the cyst is considered to be the capsule. the secondary information that could be retained is the presence or absence of hydrocephalus which is an important factor in the management of patients(23). The data of CT imaging of our patients were not considered in the present work.

In a wide radiological study of the intracranial cyst intensity, the authors correlated the signal intensity of the cyst in MRI sequences with the chemical composition and their viscosity (24). major details were reported regarding the accurate concentration of several elements for each specific radiological intensity(24). the principal information evoked by this work is that the intensity and MRI appearance of cysts are correlated to their chemical composition. the secondary data that could be retained is that parameter is a key factor in the process of decision making for choosing the modality of treatment.



The liquid aspect of the cyst is hypointense in the T1 sequence and hyperintense in T2. this form of cyst is rather desirable for a procedure of aspiration; stereotactic or endoscopic. We have observed also according to our experience without precise data in this paper, that this form of cyst has a higher speed of growth compared to other forms. This parameter has a significant impact on follow up or postoperative evaluation of patients.

All the pre and postoperative MRI studies of patients were reviewed and analyzed. Data concerning the consistency found during surgery of the cyst were not complete, the reason for which was not discussed in the present work.

We had two significant subgroups of patients' cyst signal; the first subgroup was made of 11 patients with a hypo and hyperintense intensity in T1 and T2 respectively. During surgery, the liquid aspect of the contents was confirmed in all of them. The surgery followed the standard plan of an aspiration than a careful microsurgical dissection of the cyst wall. The second subgroup was composed of 10 patients where the cysts were hyper and hypointense in T1, T2 respectively. most of them (8) were solid during surgery. the exact concentration of different components was not considered and reported in our research.

### ***The process of decision making:***

One of the most crucial steps in managing patients harboring colloid cyst is the kind of modality that must be applied for every patient. the parameters that must be considered are factors related to the cyst, the patient, and the surgeon.

A perfect radiological analysis of the cyst aspect on MRI is mandatory. The size and the intensity in all sequences are substantial for predicting the cyst viscosity and even surgical modality; stereotactic or endoscopy or open surgery. the insertion of the cyst is appreciated on sagittal T2 sequences. the main landmark is the interventricular foramen and the more posterior the cyst is, the more the probability of adding choroidal fissure extensions is mandatory to achieve safe microsurgical resection. The quality and the shape of the foramen of Monroe on coronal T2 sequences must also be considered in the case of endoscopic procedures. The importance of the parasagittal veins network on vascular sequences is key data for planning craniotomy. The presence and severity of hydrocephalus is another key factor in selecting the kind of surgery that must be followed.

The second parameter that must be evaluated is the patient's clinical status at admission. The acute presentation of colloid cyst is a consequence of hydrocephalus. we have noticed 10 patients with an increased intracranial pressure syndrome, only two of them were shunted initially in another institution and this is due to the severity of the symptoms. these two patients were reoperated for the cyst 2 and 5 months later. The rest of the patients from this same subgroup tolerated the symptoms still removing the cyst through an open approach mainly one to two days after. Microsurgical cyst removal was decided after radiological evidence of growth on serial imaging despite that he was free from symptoms.

Some authors(25, 26) advocated a conservative attitude to old and asymptomatic patients. we didn't notice this population in our study group. there were two patients whose age is greater than 50 years, one of them was asymptomatic but had proof of cyst enlargement on follow-up and the other complained of chronic headaches. This conservative attitude remains controversial, because of the significant reports of sudden deaths during observation of patients harboring colloid cyst(26-29). we didn't notice any case of sudden death or received patients in comatose status in our patients. The preferences of the patients for the modality of management are crucial and must be respected. all patients were informed about the type and possible risks of surgery and accepted the strategy.

The surgeon and his surgical preferences and experience are another important key parameter that must be considered in this process. in our work, all the procedures were open transcranial approaches. Further experience in endoscopic and aspiration techniques must be gained for ideal management for patients harboring these cysts.

### ***Surgical approaches:***

#### ***(1) The transcallosal transforaminal approach:***

The third ventricle is deeply located in the diencephalic midline region, and the interhemispheric transforaminal route is one of the microsurgical approaches to gain access to this part of the brain. The first description of the transcallosal approach for colloid cyst was described by Greenwood in 1949(30). The main limit that was described in the same work (30) , is that the author has clarified that once he gains the lateral ventricle, the progression toward the third ventricle was achieved after performing incisions on the anterior and posterior borders of the foramen of Monroe and widening it.

All of our surgeries were performed in a supine position with a flexed and neutral position of the head. the modern aspect that could be added to this position; is keeping the supine position and turning the head to the horizontal plane as it was described for reaching deep-seated cavernous malformation (31). this position allows; the frontal lobe to fall by gravity and better ergonomic microsurgical dissection for the surgeon (31).

The craniotomy for the anterior transcallosal approach is a frontal parasagittal right-sided bone flap. At the beginning of our experience, the craniotomy was more centered on the coronal suture. We have noticed some cases of postoperative deficit due to the extension of the edema to the Rolandic area. The origin was few sacrifices of parasagittal draining veins to allow further progression of dissection. After we have gained more learning, the position of the flap respected mainly two rules; the density of the frontal parasagittal veins on the right side: the craniotomy must avoid it or the most important part of it. The second rule is that the flap is preferably placed completely anterior to the coronal suture. Interesting results have been issued by Apuzzo and colleagues(32) in one of their works about the density of parasagittal veins by considering the coronal suture. They concluded that 70% of these veins joined the superior sagittal sinus within the space of 2 cm posterior to the coronal suture and the rest (30%) were in the anterior 2 cm region (32). Further interhemispheric dissection allows exposing the pericallosal arteries. In one patient, we had an anatomical variation of the anterior cerebral arteries. He had a single trunk pericallosal artery or also named an "azygos pericallosal artery". This finding remains rare and only a few cases are reported in the literature (33),(34). One author described that this anatomical variation was associated with some malformations; agenesis of the corpus callosum and porencephalic cysts (35). In another radiological analysis, conducted on more than 7000 unselected patients, the author revealed 17 cases of a large azygos trunk which represents 0.2%(36). This kind of anatomy must be kept in mind during this step of surgery. The plan of dissection is always directed between the pericallosal arteries and lateral branches of the brain tissue must be preserved. The size of callosotomy ranged between 1.5 to 2.5 cm and was located in the anterior part of the corpus callosum. The landmarks of the floor of the lateral ventricle will define which side we have entered after this step. The rest of the work is performed through the interventricular foramen with great precautions to the internal cerebral veins and the fornices. This approach was used successfully in 30 patients (75 %). In most cases, a total resection was completed with this approach. This surgical technique alone or in comparison with endoscopic procedures, was described by several authors for colloid cysts and other lesions of the third ventricle (37, 38). (14, 39, 40).

The anterior transcallosal approach is done through a midline plan and offers an anatomical route to the third ventricle without a transgression of the brain cortex. This technique allows the access of both lateral ventricles when a septostomy is added and could also be applied even if the patient doesn't present a ventriculomegaly(41). When the interventricular foramen is closed, the choroidal extensions for posterior positioned lesions in the third ventricle are feasible. The transcallosal approach offers a wide view of the third ventricle and its lateral wall.

Several limits or disadvantages of the transcallosal approach were also described for this surgical technique. Venous infarct after parasagittal veins sacrifices is most reported. (42)but this complication remains absent for other authors (43). We have sacrificed, when necessary, veins of a small diameter and located anterior to the coronal suture. We have noticed one case of radiologically and clinically expressed venous infarct. One day after surgery, the patient presented seizures and behavior disorders, the CT showed a frontal hematoma. He was managed conservatively and discharged 13 days after surgery. One author described a strategy for sparing parasagittal draining vein by a technique of a so-called "technique for Rerouting" vein into another posterior located bridging vein(44).

The transforaminal step is performed when the interventricular foramen is enlarged by the cyst. The best indication is the ones that are projecting anteriorly at the roof of the third ventricle. One author(30), noted that his patients didn't describe postoperative evident disorders after enlarging the interventricular foramen using incisions on the anterior and posterior columns of the fornix. The limit that could be attributed to this study is the lack of precision about the cognitive disorders after surgery because he mentioned only if patients returned to work in their daily life (30). Hirsh and colleagues(45) described another way to enlarge the foramen of Monroe by the interruption of the thalamostriate vein. This technique was performed in 10 patients and remained harmless in all of them. This population was mainly pediatric and only one colloid cyst was reported in this work(45). We didn't interrupt the striothalamic vein in colloid cyst surgery.

## **(2) The trans frontal transforaminal approach:**

This surgical technique is a paramedian approach to the third ventricle. Although it remains indicated in few cases, it has less vision flexibility of the cyst compared to the transcallosal approach. We perform this approach through a corticectomy at the middle part of F2. This approach offers an oblique attack angle on the foramen of Monroe and the third ventricle. It remains a good indication for dilated ventricle making more space work around the interventricular foramen and less brain transgression because of the important size of the frontal horn. The transcortical route is a generator of several troubles due to the disruption of eloquent fibers; a hemiparesis due to interruption of centrum semiovale (46-48), memory deficit after the violation of the nucleus caudatus or thalamocortical fibers (46, 49), alexia or agraphia after the damage of the superior longitudinal fasciculus. (46, 50)

One study(46) proved that an approach through the superior frontal gyrus is less disruptive on projection and association fibers. This retrospective study is based on volumetric considerations on DTI imaging. The author didn't consider the asymmetry between the two hemispheres and the notion of dominance in their study. These additional facts could be limiting for their final results (46).

The transfrontal transventricular approach was used in 4 patients in our study group. two of them, the resection was through the interventricular foramen, and for the rest, the transchoroidal progression was adapted.

The most common complication of this approach is seizures (37, 47, 51). This complication was observed in 3 patients of our series. The first case was in a patient who had a tragic evolution after a vascular tear on the pericallosal artery complicated by a postoperative hematoma and seizures. the two others reported after transcortical approaches and well -controlled after adapted treatment. We have noticed one case of hemiparesis in a transcallosal approach that was included in venous infarct after sacrificing a parasagittal vein. this deficit was resolved completely at three months of follow-up. Interestingly, seizures are more reported after the transcallosal approach than in the transventricular approach in one study(52).

### ***(3) The choroidal extensions:***

The true understanding of the microsurgical anatomy of the choroidal fissure, is the key factor in approaching lesions or colloid cysts inserted posteriorly in the roof of the third ventricle. Rhoton and colleagues(53) divided the choroidal fissure into three parts; a body part; located between the body of the fornix and the thalamus, an atrial part between the crus of the fornix and the pulvinar, and a temporal part situated between the fimbria and the inferior surface of the thalamus. the choroidal extensions to colloid cyst posteriorly inserted are the ideal route for safe maximal resection and are directed through the body portion of the fissure. The first part of the fissure is related in the medial side to the velum interpositum and the cerebral veins. these two structures form the roof of the third ventricle(53).

#### ***(3.1) The transchoroidal extension:***

The transchoroidal progression to the third ventricle is achieved after the opening of the tela choroidea at the level of the body part of the choroidal fissure. this incision is placed between the fornix and the choroid plexus and allows the exposure of the roof of the third ventricle and work close to the cerebral veins. (53) this surgical route avoids the postero-lateral choroidal arteries and the thalamostriate vein(54). In one interesting anatomical study (55)analyzing the limitations of the transchoroidal variation of the transcallosal approach, the authors reported these major limitations; the opening of the choroidal fissure behind the foramen of Monroe is limited to 1.5 cm and this is due to the expanding width of the forniceal columns. The second limit is that the anterior columns of the fornix block the view to the anterior part of the third ventricle. the last limit is that the dense network of parasagittal veins limits the approach of the anterior third ventricle from a posteroanterior trajectory. The last two limitations could not be significantly considered in our work because, for anteriorly located colloid cysts, the transforaminal route was adapted. The transchoroidal variation was used in two patients. in both cases, total resection was achieved.

#### ***(3.2) The subchoroidal extension:***

This variation is completed by incising the taenia thalami between the choroid plexus and the thalamus. the major main of this surgical variation is the management of the thalamostriate vein during the extension. this vascular interruption is performed to have a wider view and better manipulation of third ventricular tumors. this maneuver didn't induce any postoperative sequelae for patients in one work (56, 57). The physiological explanation reported by the same author is the existence of a vascular network between the cortical and basal veins that allows transcerebral and subependymal connections. (56, 57). another work about the surgical resection of colloid cyst, 57 patients presenting colloid cyst were operated on using the so-called « the interhemispheric, transcallosal approach subchoroidal fornix-sparing technique »(58).in their technical note, they precised that the opening of the roof of the third ventricle is made lateral and caudal to the thalamostriate vein. in this way, this vein was always respected in their work(58). the subchoroidal extension was used in only one case of our patients and the resection was subtotal. the thalamostriate vein was not interrupted in the same patients.

#### ***(4). The interforniceal extension:***

Bush and colleagues reported firstly this approach for tumors of the third ventricle (59). the same author(59) used the right transfrontal transventricular route . the interforniceal approach was used by another other for surgical lesions of the middle and posterior parts of the third ventricle(60, 61). the same author clarified that this approach is a midline natural route between the forniceal columns to the surgical target located posteriorly in the third ventricle(38) (60, 61).in two works(62) (63), the memory disorders were reported in some patients after the application of the same surgical approach. the interforniceal extension was adopted in three patients. two of them had troubles of the recent memory that resolved at follow-up; for one of them at three months and the other at almost one year after surgery.

### ***Quality of resection and outcomes:***

As it was mentioned early in the paper, total resection of the cyst was completed in 32 patients (80%). This resection was almost achieved using a "purely transcallosal transforaminal approach" in 28 patients. for the remaining patients with total resection, three of them had a "transcallosal interforniceal approach".

The three patients had a large colloid cyst, extending to the middle part of the ventricular roof. another patient had a trans frontal trans choroidal technique. it's important to notice that the interforniceal approach was used at the beginning of our experience with ventricular surgery. The transchoroidal extension for appropriate cases is the one that is mostly used. Desai KI and colleagues (51), reported that among 93 patients operated for colloid cyst, the total removal was achieved in 90 patients. among these techniques, the transforaminal route was adapted in 87 cases; 29 and 58 after transcortical and transcallosal techniques respectively (51).

In Nair S's work (12), the transcallosal approach was used in more than 90% of patients for cyst resection. in 7.4% of patients, the transcortical approach was adapted for resection. the interforniceal was completed in 10% of patients. the idea that could be retained is the use of the transcallosal approach is the widely applied technique with its several extensions. the interforniceal technique is the least used one.

In our study, a subtotal resection was achieved in 8 patients. the main difficulties that were encountered are the adhesions of the cyst wall to neurovascular structure especially of internal cerebral veins, the solid contents of the cyst, and important volume inducing poor visualization of the cyst in the third ventricle. half of them stayed stable without significant symptoms disturbing the patient and the rest had proof of recurrence in imaging.

The fifth case of recurrence was in a patient where a total resection was realized. The recurrence occurred within a period of 2 to 5 years follow up. we have reoperated three patients for recurrence and the surgery was through a transcallosal approach in all of them and a total removal was achieved.

In addition to the usual complication related to brain surgery, we had 4 patients with disorders of recent memory. 3 of them were at a slight degree and resolved at 6 months of follow up and the last was severe and remained definitive. The origin of this disability is mainly reported to the fornix damage(14). The role of the fornix was debated by authors in several reports(14, 64, 65) . one way of enlarging the interventricular foramen was sectioning the fornix to get access to the third ventricle and resect surrounding lesions (40) and without having a significant postoperative memory deficit. On the other hand, serious neurological deficits were induced after interrupting the fornix such; verbal and non-memory deficit (66, 67).

We have also noticed 2 patients that presented complications related to venous infarct in the frontal area. In the first case, it was a frontal syndrome that improved at 6 months of follow-up. the second patient had postoperative seizures and was well controlled by medication. Both of the cases of the infarct were reported at the beginning of our cases. we have switched to place the bone flap completely anterior to the coronal suture and preserve all veins with large-caliber even if it's located anteriorly.

## Conclusion

The surgical management of colloid cyst is a safe procedure without significant morbidity when it's conducted by an experienced team. The surgical option is indicated for symptomatic patients or asymptomatic with proof of cyst's growth on serial imaging. the transcallosal transforaminal approach is the most appropriate technique for these deep midline lesions. the choroidal extensions and especially the trans choroidal one is the safest route to resect these lesions without significant consideration to their size and their location at the level of the ventricular roof. Preserving veins and the fornix is the key strategy that the surgeon must keep in mind to have less deterioration of functions related to these eloquent structures. The endoscopic procedure is an alternative modality to open microsurgical techniques that must be mastered by surgeons of the colloid cyst. Several research works must be conducted about the recurrence and the re-growth ability in each cyst consistence. The neuropsychological consequences related to specific size and location of callosotomy is another interesting field of further research, this could be completed by postoperative evaluation according to precise scales and experienced team of the same field.

## References

1. Ho KL, Garcia JH. Colloid cysts of the third ventricle: ultrastructural features are compatible with endodermal derivation. *Acta neuropathologica*. 1992;83(6):605-12.
2. WE: D. *Benign Tumors of the Third Ventricle of the Brain: Diagnosis and Treatment*: Springfield, Ill: 1933.
3. Eshra MA. Endoscopic management of third ventricular colloid cysts in mildly dilated lateral ventricles. *Neurosurg Rev*. 2019;42(1):127-32.
4. Horn EM, Feiz-Erfan I, Bristol RE, Lekovic GP, Goslar PW, Smith KA, et al. Treatment options for third ventricular colloid cysts: comparison of open microsurgical versus endoscopic resection. *Neurosurgery*. 2007;60(4):613-8; discussion 8-20.
5. Pollock BE, Huston J, 3rd. Natural history of asymptomatic colloid cysts of the third ventricle. *Journal of neurosurgery*. 1999;91(3):364-9.

6. Turel MK, Kucharczyk W, Gentili F. Spontaneous resolution of colloid cyst of the third ventricle: Implications for management. *Asian journal of neurosurgery*. 2017;12(2):203-6.
7. Peeters SM, Daou B, Jabbour P, Ladoux A, Abi Lahoud G. Spontaneous Regression of a Third Ventricle Colloid Cyst. *World neurosurgery*. 2016;90:704.e19-.e22.
8. Deinsberger W, Böker DK, Samii M. Flexible endoscopes in treatment of colloid cysts of the third ventricle. *Minimally invasive neurosurgery : MIN*. 1994;37(1):12-6.
9. Deinsberger W, Böker DK, Bothe HW, Samii M. Stereotactic endoscopic treatment of colloid cysts of the third ventricle. *Acta neurochirurgica*. 1994;131(3-4):260-4.
10. Mathiesen T, Grane P, Lindquist C, von Holst H. High recurrence rate following aspiration of colloid cysts in the third ventricle. *Journal of neurosurgery*. 1993;78(5):748-52.
11. Kondziolka D, Lunsford LD. Stereotactic management of colloid cysts: factors predicting success. *Journal of neurosurgery*. 1991;75(1):45-51.
12. Nair S, Gopalakrishnan CV, Menon G, Easwer HV, Abraham M. Interhemispheric transcallosal transforaminal approach and its variants to colloid cyst of third ventricle: Technical issues based on a single institutional experience of 297 cases. *Asian J Neurosurg*. 2016;11(3):292-7.
13. Hodges JR, Carpenter K. Anterograde amnesia with fornix damage following removal of IIIrd ventricle colloid cyst. *Journal of neurology, neurosurgery, and psychiatry*. 1991;54(7):633-8.
14. Mathiesen T, Grane P, Lindgren L, Lindquist C. Third ventricle colloid cysts: a consecutive 12-year series. *J Neurosurg*. 1997;86(1):5-12.
15. SJOVALL E. tiber eine Ependymcyste embryonalenbCharakters (Paraphyse?) im dritten Hirnventrike! mit todlichem Ausgang. *Beitr z path Anat u z allg Path*. 1909;47:24.
16. Slade HW, Glazer NM, Hauser H. Paraphyseal or Colloid Cysts of the Third Ventricle. 1956;67(3):351-8.
17. Shibata T, Burger PC, Kleihues P. [Origin of colloid cyst: immunoperoxidase study]. *No to shinkei = Brain and nerve*. 1987;39(10):953-8.
18. Ciric I, Zivin I. Neuroepithelial (colloid) cysts of the septum pellucidum. *J Neurosurg*. 1975;43(1):69-73.
19. Suresh Nair CVG, Girish Menon, H. V. Easwer, Mathew Abraham. Interhemispheric transcallosal transforaminal approach and its variants to colloid cyst of third ventricle: Technical issues based on a single institutional experience of 297 cases. *Asian Journal of Neurosurgery*. 2016;11(3).
20. Brostigen CS, Meling TR, Marthinsen PB, Scheie D, Aarhus M, Helseth E. Surgical management of colloid cyst of the third ventricle. *Acta Neurol Scand*. 2017;135(4):484-7.
21. Buttner A, Winkler PA, Eisenmenger W, Weis S. Colloid cysts of the third ventricle with fatal outcome: a report of two cases and review of the literature. *Int J Legal Med*. 1997;110(5):260-6.
22. Ryder JW, Kleinschmidt-DeMasters BK, Keller TS. Sudden deterioration and death in patients with benign tumors of the third ventricle area. *J Neurosurg*. 1986;64(2):216-23.
23. Algin O, Ozmen E, Arslan H. Radiologic manifestations of colloid cysts: a pictorial essay. *Can Assoc Radiol J*. 2013;64(1):56-60.
24. Ahmadi J, M.D.;Savabi, Fatemeh, Ph.D.; Apuzzo, Michael L.J., M.D.; Segall, Hervey D., M.D.; Hinton, David, M.D. Magnetic Resonance Imaging and Quantitative Analysis of Intracranial Cystic Lesions: Surgical Implication. *Neurosurgery* 1992-98. 1994;35:8.
25. Pollock BE, Schreiner SA, Huston J, 3rd. A theory on the natural history of colloid cysts of the third ventricle. *Neurosurgery*. 2000;46(5):1077-81; discussion 81-3.
26. Büttner A, Winkler PA, Eisenmenger W, Weis S. Colloid cysts of the third ventricle with fatal outcome: a report of two cases and review of the literature. *Int J Legal Med*. 1997;110(5):260-6.

27. Aronica PA, Ahdab-Barmada M, Rozin L, Wecht CH. Sudden death in an adolescent boy due to a colloid cyst of the third ventricle. *The American journal of forensic medicine and pathology*. 1998;19(2):119-22.
28. de Witt Hamer PC, Verstegen MJ, De Haan RJ, Vandertop WP, Thomeer RT, Mooij JJ, et al. High risk of acute deterioration in patients harboring symptomatic colloid cysts of the third ventricle. *J Neurosurg*. 2002;96(6):1041-5.
29. Chan RC, Thompson GB. Third ventricular colloid cysts presenting with acute neurological deterioration. *Surgical neurology*. 1983;19(4):358-62.
30. Greenwood J, Jr. Paraphysial cysts of the third ventricle; with report of eight cases. *J Neurosurg*. 1949;6(2):153-9.
31. Hendricks BK, Spetzler RF. Anterior Interhemispheric Transcallosal Approach for Thalamic Cavernous Malformation: 2-Dimensional Operative Video. *Operative Neurosurgery*. 2019;17(6):E240-E1.
32. Apuzzo MLJ, Chikovani OK, Gott PS, Teng EL, Zee C-S, Giannotta SL, et al. Transcallosal, Interfornicial Approaches for Lesions Affecting the Third Ventricle: Surgical Considerations and Consequences. *Neurosurgery*. 1982;10(5):547-54.
33. RM. B. Structural variants of the brain base arteries. *Vopr neurokhir*. 1974;5:6.
34. Dunker R, Harris AJJ. Surgical anatomy of the proximal anterior cerebral artery. 1976;44 3:359-67.
35. Szdzyu D, Lehmann R, Nickel B. Common trunk of the anterior cerebral arteries. *Neuroradiology*. 1972;4(1):51-6.
36. Huber P, Braun J, Hirschmann D, Agyeman JF. Incidence of berry aneurysms of the unpaired pericallosal artery: angiographic study. *Neuroradiology*. 1980;19(3):143-7.
37. Camacho A, Abernathy CD, Kelly PJ, Laws ER, Jr. Colloid cysts: experience with the management of 84 cases since the introduction of computed tomography. *Neurosurgery*. 1989;24(5):693-700.
38. Apuzzo ML, Chikovani OK, Gott PS, Teng EL, Zee CS, Giannotta SL, et al. Transcallosal, interfornicial approaches for lesions affecting the third ventricle: surgical considerations and consequences. *Neurosurgery*. 1982;10(5):547-54.
39. Konovalov AN, Gorelyshev SK, Ozerova VI. [Colloid cysts of the third ventricle]. *Zhurnal voprosy neurokhirurgii imeni N N Burdenko*. 1997(3):3-8.
40. Lewis AI, Crone KR, Taha J, van Loveren HR, Yeh HS, Tew JM, Jr. Surgical resection of third ventricle colloid cysts. Preliminary results comparing transcallosal microsurgery with endoscopy. *J Neurosurg*. 1994;81(2):174-8.
41. Benes V. Advantages and disadvantages of the transcallosal approach to the III ventricle. *Childs Nerv Syst*. 1990;6(8):437-9.
42. Chen TC KM, Thinton DR, Apuzzo MLJ. The colloid cyst in Apuzzo surgery of the third ventricle. 1998;2nd edition:61.
43. McNatt SA, Sosa IJ, Krieger MD, McComb JG. Incidence of venous infarction after sacrificing middle-third superior sagittal sinus cortical bridging veins in a pediatric population. *Journal of neurosurgery Pediatrics*. 2011;7(3):224-8.
44. Ohara K, Inoue T, Ono H, Kiyofuji S, Tamura A, Saito I. Technique for rerouting a bridging vein that hinders the anterior interhemispheric approach: a technical note. *Acta neurochirurgica*. 2017;159(10):1913-8.
45. Hirsch JF, Zouaoui A, Renier D, Pierre-Kahn A. A new surgical approach to the third ventricle with interruption of the striothalamic vein. *Acta neurochirurgica*. 1979;47(3-4):135-47.
46. Szmuda T, Słoniewski P, Szmuda M, Waszak PM, Starzyńska A. Quantification of white matter fibre pathways disruption in frontal transcortical approach to the lateral ventricle or the interventricular foramen in diffusion tensor tractography. *Folia morphologica*. 2014;73(2):129-38.
47. Antunes JL, Louis KM, Ganti SR. Colloid cysts of the third ventricle. *Neurosurgery*. 1980;7(5):450-5.
48. Park ES, Cho YH, Kim JH, Kim SJ, Khang SK, Kim CJ. Frontal transcortical approach in 12 central neurocytomas. *Acta neurochirurgica*. 2012;154(11):1961-71; discussion 72.
49. Fuh JL, Wang SJ. Caudate hemorrhage: clinical features, neuropsychological assessments and radiological findings. *Clinical neurology and neurosurgery*. 1995;97(4):296-9.

50. Shinoura N, Onodera T, Kurokawa K, Tsukada M, Yamada R, Tabei Y, et al. Damage to the upper portion of area 19 and the deep white matter in the left inferior parietal lobe, including the superior longitudinal fasciculus, results in alexia with agraphia. *European neurology*. 2010;64(4):224-9.
51. Desai KI, Nadkarni TD, Muzumdar DP, Goel AH. Surgical management of colloid cyst of the third ventricle--a study of 105 cases. *Surgical neurology*. 2002;57(5):295-302; discussion -4.
52. Milligan BD, Meyer FB. Morbidity of Transcallosal and Transcortical Approaches to Lesions in and Around the Lateral and Third Ventricles: A Single-Institution Experience. *Neurosurgery*. 2010;67(6):1483-96.
53. Nagata S, Rhoton AL, Jr., Barry M. Microsurgical anatomy of the choroidal fissure. *Surgical neurology*. 1988;30(1):3-59.
54. Wen HT, Rhoton AL, Jr., de Oliveira E. Transchoroidal approach to the third ventricle: an anatomic study of the choroidal fissure and its clinical application. *Neurosurgery*. 1998;42(6):1205-17; discussion 17-9.
55. Ulm AJ, Russo A, Albanese E, Tanriover N, Martins C, Mericle RM, et al. Limitations of the transcallosal transchoroidal approach to the third ventricle: Technical note %J *Journal of Neurosurgery JNS*. 2009;111(3):600-9.
56. Hirsch J, Zouaoui A, Rénier D, Pierre-Kahn AJAN. A new surgical approach to the third ventricle with interruption of the striothalamic vein. 2005;47:135-47.
57. Cossu M, Lubinu F, Orunesu G, Pau A, Sehrbunt Viale E, Sini MG, et al. Subchoroidal approach to the third ventricle. *Microsurgical anatomy*. *Surgical neurology*. 1984;21(4):325-31.
58. Shapiro S, Rodgers R, Shah M, Fulkerson D, Campbell RL. Interhemispheric transcallosal subchoroidal fornix-sparing craniotomy for total resection of colloid cysts of the third ventricle. *J Neurosurg*. 2009;110(1):112-5.
59. BUSCH E. A NEW APPROACH FOR THE REMOVAL OF TUMORS OF THE THIRD VENTRICLE. 1944;19(1-2):57-60.
60. Apuzzo MLJ AA. Transcallosal interforniceal approach. Baltimore, Williams & Wilkins ed1998.
61. Siwanuwatn R, Deshmukh P, Feiz-Erfan I, Rekate HL, Zabramski JM, Spetzler RF, et al. Microsurgical anatomy of the transcallosal anterior interforniceal approach to the third ventricle. *Neurosurgery*. 2005;56(2 Suppl):390-6; discussion -6.
62. Jin BZ, Yuan GY, Yue SZ, Zhou X, Guan QK, Xu DW, et al. The use of transcallosal-interforniceal approach for microsurgical removal of the third ventricle tumors. *Journal of neurosurgical sciences*. 2015;59(1):19-24.
63. Zhang HW, Zhang MS, Xia L, Qu YM, Li JH, Ren M, et al. [Experiences of transcallosal-interforniceal approach for resection of the third ventricle and the pineal region tumors: report of 24 cases]. *Zhonghua wai ke za zhi [Chinese journal of surgery]*. 2012;50(2):139-43.
64. Jeeves MA, Simpson DA, Geffen G. Functional consequences of the transcallosal removal of intraventricular tumours. *Journal of neurology, neurosurgery, and psychiatry*. 1979;42(2):134-42.
65. Sweet WH, Talland GA, Ervin FR. Loss of recent memory following section of fornix. *Transactions of the American Neurological Association*. 1959;84:76-82.
66. McMackin D, Cockburn J, Anslow P, Gaffan D. Correlation of fornix damage with memory impairment in six cases of colloid cyst removal. *Acta neurochirurgica*. 1995;135(1):12-8.
67. Cameron AS AY. Verbal memory deficit after left fornix removal. *Int J Neurosci* 12. 1981.

**Citation:** HANDIS C, FELISSI Y, MEZIANI S, MORSLI A. "Colloid Cysts of The Third Ventricle: The Surgical Experience of a Single Institution". *SVOA Neurology* 2:4 (2021) Pages 125-139.

**Copyright:** © 2021 All rights reserved by FELISSI Y., et al. This is an open access article distributed under the Creative Commons Attribution License, which permits unrestricted use, distribution, and reproduction in any medium, provided the original work is properly cited.