

A Teenager with an Anti-Glutamic Acid Positive, GQ1b Negative Miller Fisher Syndrome: An Atypical Presentation of Intracranial Hypertension with Incidental Chiari 1.5

Franklyn Rocha-Cabrero, MD^{1,*}, Anna Shah, MD², Mario Zamora, MD³ and Lindsay Dudeck, MD⁴

¹ Department of Neurology and Epilepsy, University of California-Irvine and Department of Neurology, University of Miami, USA.

² Internal Medicine Department at Bayview Medical Center in Johns Hopkins University, USA.

^{3,4} Department of Pediatrics, Division of Pediatric Neurology, University of Miami School of Medicine, USA.

***Corresponding Author:** Franklyn Rocha-Cabrero, MD, University of California-Irvine 200 S. Manchester Avenue Ste. 206, Orange, CA 92868, USA, Phone (714)-456-6808. Fax (714)-456-8805.

Received: October 19, 2021 **Published:** November 30, 2021

Abstract

Miller Fisher syndrome (MFS), considered a subtype of Guillain Barre Syndrome (GBS), is an acute, often post-infectious inflammatory demyelinating disorder usually presenting with a triad of ophthalmoplegia, ataxia, and areflexia. Intracranial hypertension (IH) rarely occurs with MFS, < 5% of cases, and few reported cases exist. We report a pediatric patient with a history of chronic tetracycline use presenting with severe headache, blurry vision, and diplopia with grade V papilledema that preceded the typical course of MFS; additional symptoms progressively included neck stiffness, multiple cranial nerve neuropathies, tinnitus, quadriparesis, dysmetria, gait ataxia, and areflexia. MRI imaging at presentation showed an incidental Chiari 1.5 malformation, bulging of the perioptic nerve sheath, flattening of the posterior sclera, and partially empty sella, consistent with IH. CSF studies showed albuminocytological dissociation with high CSF protein, serum negative GQ1b antibody, and positive GAD antibody. A 5-day course of IVIG, acetazolamide, and pulse dose steroids resulted in gradual improvement leading to full neurological recovery. Nerve conduction studies 3-4 weeks post-IVIG were consistent with MFS. We hypothesize that the combination of low CSF flow from the anatomical anomaly (Chiari 1.5) and chronic tetracycline use, with poor CSF arachnoid granulation reabsorption due to abnormal CSF protein levels may have precipitated the initial development of communicating hydrocephalus. The clinical improvement from pulse dose steroids and acetazolamide suggests that the pathophysiology was related to CSF flow and not exclusively driven by the antibody-mediated attack within myelin sheaths, as is typical of MFS. A major limitation of this case was the lack of opening pressure, CSF fluid analysis, and the absence of comprehensive CSF antibody studies given a low-volume tap due to safety concerns, including tonsillar herniation. More research is needed to further assess the pathophysiology relationship between Chiari 1.5 and different variants of acute demyelinating disorders, including MFS.

Keywords: Miller Fisher syndrome, intracranial hypertension, Chiari 1.5, anti-glutamic acid, decarboxylase antibodies

Introduction

Miller Fisher syndrome (MFS), a Guillain Barre Syndrome (GBS) variant, is an acute, post-infectious inflammatory demyelinating disorder that classically presents as a triad of ophthalmoplegia, ataxia, and areflexia.¹ GQ1B, a serological marker of MFS, can be absent in some patients and still manifest with typical symptoms, likely due to the existence of uncharacterized or less commonly described ganglioside antibodies including GD1A, GM1/GTA1A, and GM1/GQ1B.²

Intracranial hypertension (IH) rarely occurs with MFS, < 5% of cases, and few reported cases exist.³⁻⁴ Glutamic acid decarboxylase (GAD) is an intracellular enzyme involved in γ -aminobutyric acid (GABA), production in the central nervous system (CNS). Neurological disorders associated with anti-GAD antibodies (GAD-Ab) include limbic encephalitis, autoimmune temporal lobe epilepsy, stiff-person syndrome, and cerebellar ataxia. Clinical findings associated with the latter include gait ataxia, nystagmus, and rarely, cranial nerve neuropathies. GAD-Ab mediated disorders respond to acute immunomodulatory therapy, including high dose steroids.⁵

Case Report

A 14-year-old teenager with atopy and recent tetracycline use presented with subacute, progressive headache, blurry vision, diplopia, and grade V papilledema. Days later, she exhibited neck stiffness, multiple cranial nerve neuropathies (III, IV, and VI), tinnitus, quadriparesis, dysmetria, gait ataxia, and areflexia. MRI showed a Chiari 1.5 malformation, bulging perioptic nerve sheaths, flattened posterior sclera, and partially empty sella, consistent with IH. (Figure 1) CSF and serum studies showed albuminocytological dissociation, negative GQ1b antibody, and positive GAD-ab, plus various other antibody elevations. The patient was treated with IVIG, high dose acetazolamide, and IV methylprednisolone, with gradual improvement leading to full recovery. The clinical impression was that steroid use, in particular, led to a noticeable improvement in ataxia symptoms. Nerve conduction post-IVIG showed axonal demyelination with nerve root involvement, consistent with MFS.

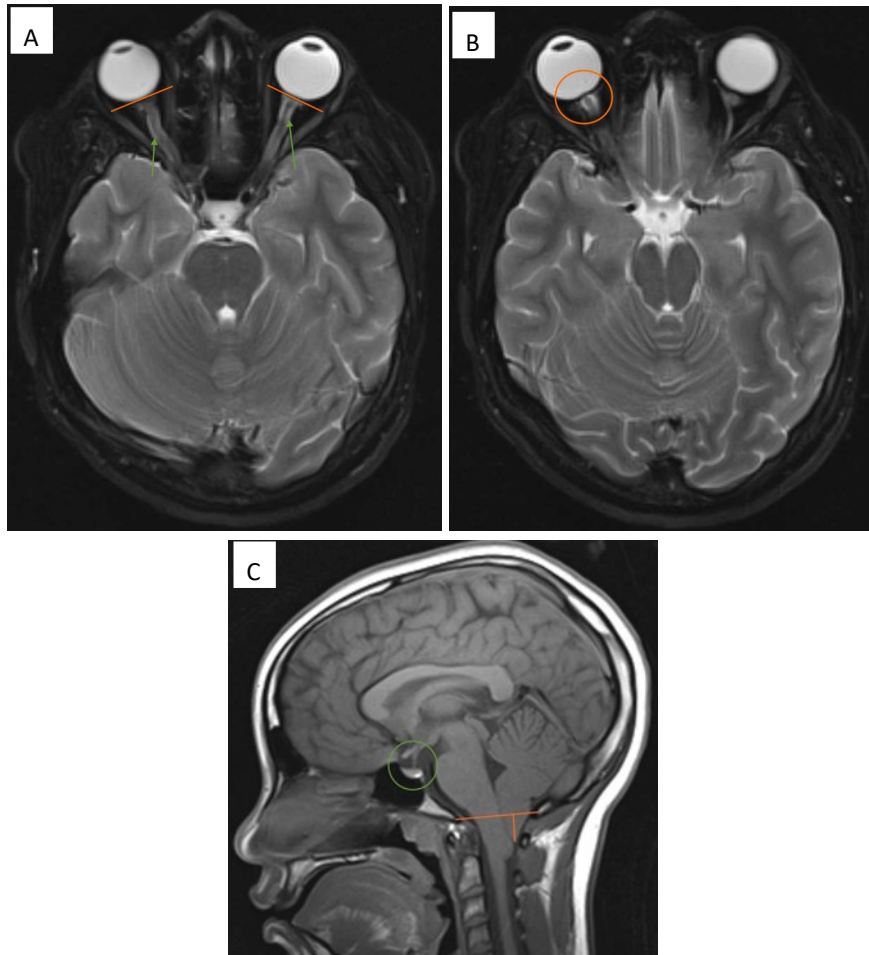


Figure:1 Initial MRI showed a peg-like 1.9 cm Chiari 1.5 malformation (**Image A**, sagittal T1 non-contrasted image, orange markings); partially empty sella (**Image A**, green circle); bulging of the perioptic nerve sheath (**Image B**, axial T2 with fat suppression, green arrows); and flattening of the posterior sclera (**Image B**, orange markings) with bulging of the optic disc (**Image C**, axial T2 with fat suppression, orange circle) were seen; these findings, in conjunction with grade V papilledema on fundoscopy led to a diagnosis of severe intracranial hypertension (IH).

Table 1. Cerebrospinal Fluid (CSF) Findings

CSF Laboratory Value	Result (Unit)
CSF White Blood Cells (WBC)	6 (cells/mm ³)
CSF Neutrophils	1 (cells/mm ³)
CSF Lymphocytes	79 (cells/mm ³)
CSF Monocytes	20 (cells/mm ³)
CSF Red Blood Cells (RBC)	13 (cells/mm ³)
CSF Glucose	74 (mg/dL)
CSF Protein	73 (mg/dL)

Table 2. Serum Antibody Findings

Serum Antibodies/Value	Result (Unit)
Serum ACE	21 (unit/L)
Anti-GQ1b Antibody (IgG)	Negative < 1:100
Anti-GAD-65 Antibody (IgG)	Positive > 250 (unit/mL)
Borrelia burgdorferi Antibody (IgG)	Negative
Anti-SSA Antibody	Positive
Anti-SSB Antibody	Negative
Anti-Smith Antibody	Negative
Anti-SMRNP Antibody	Negative
Anti-RNP Antibody	Positive
Anti-Ribosomal P Antibody	Negative
Anti-Scleroderma 70 Antibody	Negative
Lupus panel	Negative
Erythrocyte Sedimentation Rate	26 (mm/hr.)
C-Reactive Protein	0.5 (mg/dL)

Discussion

This case highlights an atypical clinical presentation of MFS, with atypical serological markers and management. Presenting symptoms of vision loss, papilledema, and signs of IH *preceded* the classical MFS triad. To date, there has been no reported association between papilledema, IH, and GAD-Ab however, there is a clinical report of cerebellar ataxia improving with IVIG treatment and IV steroids.⁵ Several clinical findings dispute a GAD-ab mediated cerebellar ataxia mimicking MFS, including areflexia, albuminocytological dissociation, and absence of vertigo.⁵ Additionally, subsequent titers for GAD-ab were negative, leading to uncertainty of its clinical significance.

The patient's history of atopy, various atypical antibody elevations, and clinical response to high dose steroids, suggests the disease process has a mixed etiology, with both a neuroinflammatory and antibody-mediated attack to the myelin sheaths, the latter more typical of classic MFS. The Chiari 1.5 likely contributed to IH due to disrupted CSF flow and less compensation for an increased osmotic gradient. Finally, tetracycline use may have further decreased CSF absorption. A limitation of this case was the lack of opening pressure and CSF analysis due to a small volume tap pursued given patient safety issues (concern for herniating Chiari). In summary, we reveal a rare association between IH and MFS, responsive to steroids and diuretics; the latter can be strongly considered for the treatment of patients with IH and MFS symptoms to prevent vision loss or hydrocephalus. Further research may elucidate the pathophysiological relationship between Chiari malformations and neuroinflammatory disease processes.

Acknowledgments: None

Funding: None

Author Contributions

Franklyn Rocha-Cabrero, MD: Conception and design of the report, drafting the article, literature review, data interpretation, review, and final approval of the manuscript.

Anna Shah, MD: Creation of a figure, data interpretation, review, and final approval of the manuscript.

Mario Zamora, MD: Creation of a figure, data interpretation, review, and final approval of the manuscript.

Lindsay Dudeck, MD: Manuscript intellectual contribution, data interpretation, review, and final approval of the manuscript.

References

1. Rocha-Cabrero F, Morrison EH. Miller Fisher Syndrome. [Updated 2020 Jun 29]. In: StatPearls [Internet]. Treasure Island (FL): StatPearls Publishing; Last Updated 2020Jan-.
2. Lee KY. Anti-GQ1b-negative Miller Fisher syndrome after *Campylobacter jejuni* enteritis. *Pediatr Neurol.* 2012;47(3):213-215. doi:10.1016/j.pediatrneurol.2012.04.024
3. Liu YM, Chen YL, Deng YH, Liang YL, Li W, Chen J. Miller Fisher syndrome with early intracranial hypertension and delayed bilateral simultaneous facial nerve palsy: a case report [published online ahead of print, 2019 Nov 10]. *J Int Med Res.* 2019;300060519867490. doi:10.1177/0300060519867490
4. Moreno-Ajona D, Irimia P, Fernández-Matarrubia M. Headache and Ophthalmoparesis: Case Report of an "Atypical" Incomplete Miller-Fisher Syndrome. *Headache.* 2018;58(5):746-749. doi:10.1111/head.13320

5. Nakamura Y, Nakajima H, Hosokawa T, Yamane K, Ishida S, Kimura F. Acute Cerebellar Ataxia Associated with Anti-glutamic Acid Decarboxylase Antibodies Mimicking Miller Fisher Syndrome. *Intern Med.* 2018 Jan 15;57(2):269-271. DOI: 10.2169/internalmedicine.9190-17. Epub 2017 Nov 1. PMID: 29093402; PMCID: PMC5820049.

Citation: Rocha-Cabrero F, Shah A, Zamora M, Dudeck L. "A Teenager with an Anti-Glutamic Acid Positive, GQ1b Negative Miller Fisher Syndrome: An Atypical Presentation of Intracranial Hypertension with Incidental Chiari 1.5". *SVOA Neurology* 2:6 (2021) Pages 191-194.

Copyright: © 2021 All rights reserved by Rocha-Cabrero F., et al. This is an open access article distributed under the Creative Commons Attribution License, which permits unrestricted use, distribution, and reproduction in any medium, provided the original work is properly cited.