

Nodo-Paranodopathy: Beyond the Demyelinating and Axonal Antibody-Mediated Neuropathies

Partha S Ray*

Indian Medical Association (IMA), National Professor in Neurology, India

*Corresponding Author: Prof. Dr. Partha Ray, Indian Medical Association (IMA), National Professor in Neurology, India

Received: February 14, 2022 Published: March 24, 2022

Abstract

In the last decade, antibodies targeting the node and paranode of myelinated peripheral nerves have been increasingly identified in patients with acquired immune-mediated neuropathies, commonly termed 'nodo paranodopathies'. These patients present with clinical features not usually seen with the most common immune mediated neuropathies, Guillain-Barré syndrome and chronic inflammatory demyelinating polyneuropathy. They respond poorly to conventionally used immunomodulatory therapies. Emerging evidence that these are pathologically distinct diseases has further prompted the use of more targeted treatment, such as the B cell depleting monoclonal antibody rituximab, which has been reported to significantly improve functional outcomes in this subset of patients. It is now apparent that antibodies directed against several region-specific cell adhesion molecules, including neurofascin, contactin and contactin-associated protein, can be linked to phenotypically distinct peripheral neuropathies. Importantly, the immunological characteristics of these antibodies facilitate the prediction of treatment. Electro-clinico-pathological diagnostic criteria of these acquired immune mediated neuropathies thus need to be reclassified in the light of this disease entity of 'nodo-paranodopathies'. In this review the readership is directed to explore the presence of these specific antibodies that cause this "nodo-paranodopathy" immune phenotype that has a different therapy paradigm and prognosis compared to the conventional acute and chronic neuropathy syndromes that we know of so very well.

Keywords: Guillain-barre syndrome, paranode node, CIDP; Node of Ranvier, Neurofascin, Contactin contactin-associated protein 1

Introduction

Traditionally inflammatory polyneuropathies, be it acute -like Guillain-Barre syndrome or chronic like CIDP have been diagnosed based on clinical, electrophysiological and pathological criteria¹. However, clinical experience indicates that some of these neuropathies have responded differentially to immunotherapy and the temporal profile was different in a small subsection of both acute and chronic neuropathies of inflammatory background². The pathogenesis of the immune neuropathies was explained by a combination of the cell-mediated, autoantibody induced and complement mediated immune injury mechanisms as well as disruption of the blood nerve barrier³. This then led to the identification of ganglioside autoantibodies in both the acute and chronic immune inflammatory neuropathies and their specific attachment to nerve proteins⁴. In specific situations autoantibodies against paranodal proteins have led to the identification of paranodopathies that are being increasingly recognised in the last few years. It is now apparent that antibodies directed against several region-specific cell adhesion molecules including neurofascin, contactin and contactin associated protein can be linked to phenotypically distinct peripheral neuropathies⁵. The immunological characteristics of these antibodies facilitate the production of treatment responsiveness. In what was initially identified to be refractory CIDP patients who responded to Rituximab we now have this specific diagnosis of "nodo-paranodopathy" to explain the disorder.

History

The node of Ranvier was originally described in 1871 to demonstrate that the nodes were places where ionic currents generated action potentials for saltatory conduction. Only in the last two decades this same nodal region has been recognised as a possible site of specific autoimmune attack in peripheral neuropathies⁶. Further delineation of the nodal region has led to the identification of the node, the paranode, the juxtaparanode and the internode regions with specific and characteristic distribution of the ion channels (predominantly sodium and potassium channels) and various proteins that are densely arranged to facilitate adhesion of myelin to axon and help maintain the correct localisation of these voltage-gated sodium and potassium channels facilitating effective saltatory conduction.

Of the spectrum of antibodies, immunoglobulin G4 (IgG 4) specifically targeting nodal neurofascin 186 (NF186), the para nodal neurofascin 155 (NF155), contactin-1 (CNTN1) and contactin – associated protein – 1 (Caspr1) have been identified in phenotyping distinct groups of patients among the paranodopathies⁷.

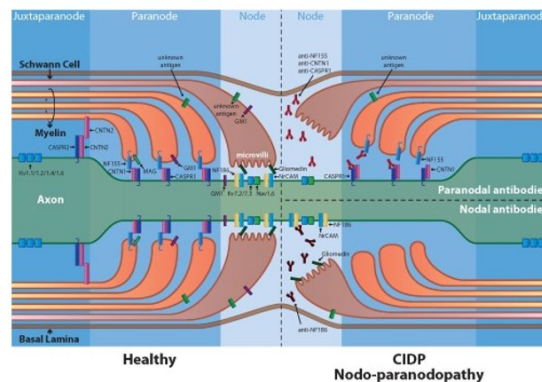
Pathogenesis

The clues to the currently identified paranodopathies goes back to the early 1990s when the connection between acute motor primarily axonal subtype of the Guillain-Barre syndrome⁸ with antecedent *Campylobacter jejuni* infection and antiganglioside antibodies was established. Pathology studies of patients with this acute motor axonal neuropathy (AMAN) showing Wallerian degeneration with no demyelination and inflammation and with the earliest changes showing as lengthening of the node of Ranvier. IgG and complement deposition at the nodes of Ranvier preceded the development of Wallerian like degeneration. This led to the hypothesis of antibody binding resulting in paralysis with little structural changes and with the potential for rapid recovery. Despite this evidence, the simple explanation of axonal degeneration and the electrodiagnostic features lacking in demyelination overlooked the role of the para nodal protein dysfunction through antibody mediated conduction failure⁹. Further identification of anti-GM1 and GD1a antibodies showing conduction block and or conduction slowing that then promptly resolved without the development of excessive temporal dispersion of the compound muscle action potentials characteristic of demyelination were reported. This was termed reversible conduction failure (RCF) due to temporary failure of conduction at the nodes of Ranvier due to loss of sodium voltage-gated channels. Next came the demonstration of nerve conduction velocity decreasing by blockage of these voltage-gated sodium channels by intravenous infusion of lignocaine or tetrodotoxin. These observations and revolution of understanding of the nerve conduction and the role of the nodes of Ranvier led to the concept of autoimmune nodo-paranodopathy. The reversible conduction failure (RCF) phenomena¹⁰ were not only detected in motor fibres but also in sensory nerves with lengthening of the nodes in the dorsal root fibres and in patients with the pharyngeal – cervical - brachial subtypes of Guillain-Barre syndrome. Pure involvement of the sensory fibres by RCF is seen in acute sensory ataxia neuropathy and in the Miller Fisher syndrome (MFS). Subsequently anti GQ1b antibodies revealed elongated nodes, myelin splitting at the para node and macrophage invasion of the internodal axon without any features of segmental demyelination quite similar to the pathology in acute motor axonal neuropathy (AMAN).

Likewise, in CIDP research in 2012 demonstrated that CIDP patients carried IgG to CNTN1 or CNTN1 and Caspr1¹¹. These Spanish patients had a common phenotype of advanced age, aggressive onset, severe axonal damage, motor predominance and poor response to intravenous immunoglobulin. The Spanish group also had patients with antibodies to NF155 with disabling tremors, a severe distal sensorimotor neuropathy and poor response to intravenous immunoglobulin. A further patient was identified as having Caspr1 antibodies with CIDP and prominent neuropathic pain. Thus 10% of all patients classified as CIDP had antibodies against proteins of para nodal junctions. This further sub classification among the AIDP and CIDP led to the paranodopathy diagnosis.

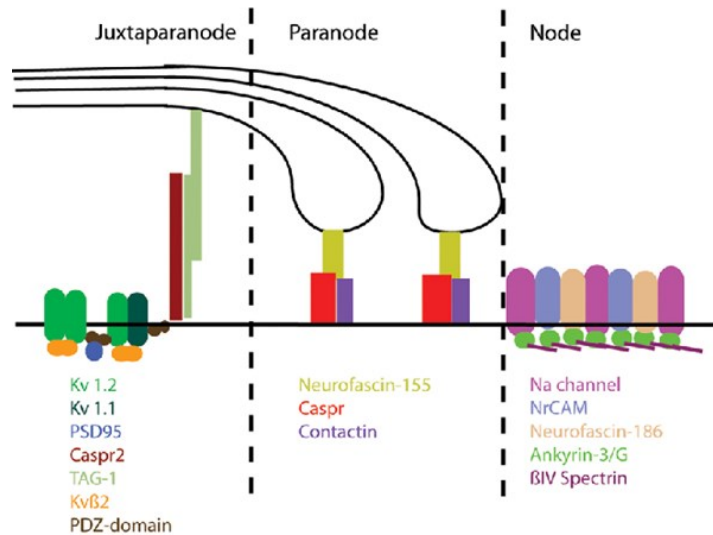
Pathology: (FIGURE ONE and TWO) the axonal cell adhesion molecules CNTN1 and Caspr1, and the glial NF155 represent an essential complex in the formation and stability of the para nodal junction and responsible through the transverse bands of addition of terminal myelin loops to axolemma¹². The paranodal junctions also act as a fence for the juxta para nodal segregation of voltage-gated potassium channels and overall contribution to the saltatory conduction of myelinated fibres.

Pathogenic mechanisms in autoimmune nodopathies . The figure shows the structure and key molecular components ...



Brain, Volume 144, Issue 4, April 2021, Pages 1043 –1045, <https://doi.org/10.1093/brain/awab116>
With thanks to Proffeter vanDoorn

Again, antibodies to axo-glial proteins are predominantly of the IgG 4 isotype. Of the five antibody isotypes IgG is the most abundant and is further subdivided into subclasses 1 to 4. The subclasses have different constant regions and vary in their ability to induce specific humoral or cellular effector functions. IgG1 and IgG3 are more potent activators of complement than IgG2 and IgG4. IgG4 antibodies are most frequently detected in paranodal antibody positive (PNAb+) patients and appeared to be highly specific for the presence of an immune mediated neuropathy phenotypically distinct to seronegative CIDP¹³. Patients with only non-IgG4 subclass PNABs have been reported to be clinically indistinguishable from seronegative patients and may have a more favourable response to IVIG. The interested readership is advised to refer to the references on this intricate and emerging interesting immuno phenotyping and immune pathogenesis of the paranodal neuropathies.



Clinical feature: (TABLE ONE)

Various findings do increase the likelihood of detecting a paranodal/nodal antibody. These are mostly adult patients presenting with a severe and symmetrical motor predominant and distal predominant polyneuropathy with a more rapidly progressive disease than those with seronegative CIDP and the peak clinical severity was also significantly greater. Hence the initial impression of Guillain-Barre syndrome was significantly more frequent in this group. In the subsequently chronically progressive or relapsing remitting disease with characteristic electrophysiology, patients met the criteria for definitive CIDP. However, patients had additional features of sensory ataxia and tremor¹⁴. This tremor and cerebellar/sensory ataxia commonly occurred in anti NF155 seropositive patients while an aggressive onset neuropathy associated with cranial neuropathies, autonomic dysfunction and respiratory insufficiency occurred in patients with antibodies cross reacting with both neurofascin isoforms (NF155 and NF186 – pan NF). Nephrotic syndrome was associated in those with CNTN1 antibodies. Underlying haematological disorders (Hodgkin’s lymphoma, chronic lymphocytic leukaemia and myeloma) was found in pan NF patients characterised by the presence of an IgG Lambda para protein¹⁵. This group was characteristically incompletely responsive to first-line therapies in particular IVIG and had a more sustained improvement from alternative immunomodulatory therapy such as Rituximab.

1. *Diagnosis: Electrophysiology:* (TABLE TWO) no definitive electrophysiology features unequivocally diagnostic of PNAB seropositivity is present. Axonal conduction block without temporal dispersion of compound muscle action potentials characteristic of paranodal/nodal pathology can also develop; this may either rapidly resolve (reversible conduction failure) or progress to axonal degeneration¹⁶. Even in such serious cases clinical recovery can be complete contrary to the general perception of an axonopathy. With the emergence of the nodo-paranodopathies conventional electrophysiological criteria for demyelinating and axonal neuropathies would be in need for revision.

2. *Testing for antibodies:* (TABLE THREE) Venous blood taken before treatment to avoid contamination with an external source of IgG (from intravenous immunoglobulin) or dilution /removal or suppression of the antibody by plasma exchange or immunosuppression is the source of antibodies. Recommendations are to test for antibodies against CNTN1, Caspr1, NF155 and NF186 in parallel. The value of CSF examination is not determined. In the testing laboratories a live cell-based assay is used for initial screening. Some laboratories use Western blot or fluorescence activated cell sorting.

TABLE: 1

Conditions encompassed by 'nodo-paranodopathies,' their associated clinical features and antigen targets (strongest associations emboldened)			
Localisation	Antigen	Associated neuropathy	Notable phenotypic features
Node	Gangliosides	AMAN (GM1a/b, GD1a, GalNac-GD1a) AMSAN (GM1, GM1b, GD1a) MNAN (IgM, GM1) CANOMAD/sensory ataxic (GD1b and/or other distal sialosyl gangliosides)	Anti-GM1 Abs are linked with: • RCF • AMAN (IgG) and MNAN (IgM)
	Gliomedin NF186	EAN (AIDP), MNAN AMAN, AIDP, CIDP, CCPD	NF186 and gliomedin Abs are associated with an animal model of AIDP, and are found in patients with MNAN
Paranode	Gangliosides	NFS (GQ1b, GT1a) PCB (GT1a, GQ1b) CCPD, AIDP, CIDP	Anti-GQ1b Abs suggest good treatment response/prognosis • Younger onset CIDP • Particularly raised CSF protein levels • Distal, motor predominant • Ataxia and tremor • Good response to rituximab but not IVIg
	CNTN1	AIDP, CIDP	• Older age • Aggressive disease onset • Motor predominant • Early axonal loss • Poor IVIg responsiveness
	Caspr	CIDP	Caspr Abs share similar features to NF155/CNTN1 Ab cohort, and associated specifically with neuropathic pain
Juxtaparanode	CNTN2/TAG1	None specific	SNPs in TAG-1 gene may favour IVIg responsiveness in CIDP
	Caspr2	None specific, but clear association with acquired neuromyotonia	Case studies link Caspr2 Abs to: • neuropathic pain • favourable response to IVIg in GBs

Credits: Fehmi J, Scherer SS, Willison HJ, et al. *J Neurol Neurosurg Psychiatry* 2018;89:61–71.

TABLE: 2

Characteristics suggesting a paranodal/nodal antibody-positive (PNAb+) neuropathy	
Clinical	Electrophysiological ^{38 39}
Symptoms/signs	
Acute/subacute onset Severe nadir disability Predominant distal motor weakness Severe sensory ataxia Tremor Neuropathic pain Cranial neuropathies Autonomic dysfunction Respiratory insufficiency	Reversible conduction failure Reduced motor conduction velocity Prolonged distal motor latencies Prolonged F-wave latencies Conduction blocks Decreased CMAP amplitudes Early axonal loss
Associated disorders	
Concurrent nephrotic syndrome ¹¹	
IgG-paraprotein lymphoproliferative disorders	
Treatment response	
No/transient response to intravenous immunoglobulin and/or plasma exchange Good response to rituximab and/or corticosteroids	
Radiological	Histological ¹³
Nerve root/plexus enhancement/ Axonal degeneration/enlargement Nodal widening Paranodal myelin loop detachment No overt inflammation or segmental demyelination	

CMAP, compound muscle action potential; IgG, immunoglobulin G

Credits: Fehmi J, Vale T, Keddie S, et al. *Pract Neurol* 2021;21:284–291

TABLE: 3

Ganglioside antibodies

IgG class GQ1b antibodies help identify complex ataxic/ brain-stem syndromes as inflammatory, providing diagnostic reassurance and support for the use of immunomodulatory therapy.

Testing for other antiganglioside antibodies in patients with GBS helps differentiate pathological subtypes but does not add to prognostication, and, as yet, does not support the use of non-standard therapies.

Paranodal protein antibodies

Antibodies against the nodal proteins NF155, CNTN1 and Caspr aid diagnosis of inflammatory neuropathies with atypical features.

Consider testing for;

rNF155 antibodies in the context of neuropathies with young age of onset, motor predominance, ataxia, tremor or additional central nervous system CNS involvement.

CNTN1 antibodies in neuropathies with aggressive onset or motor predominance.

Caspr antibodies in patients with rapidly progressive, motor predominant neuropathies and/or prominent neuropathic pain

In patients with any IgG4 subclass paranodal-protein antibody, IVIg is often ineffective and rituximab should be considered.

Credits: Fehmi J, Vale T, Keddie S, et al. *Pract Neurol* 2021;21:284–291.

Treatment

“Seropositive patients” appear less responsive to first-line treatments for inflammatory neuropathies, and it would seem appropriate to consider initiating Rituximab early in the disease course even if there was a transient response to initial IVIG therapy likely indicating an ongoing and potentially treatment responsive immune process¹⁷. The reason for transient effectiveness of IVIG is through the suppression of complement activity whereas IgG4 subclass antibodies do not fix complement and exert their pathogenic effects by other mechanisms. The effect of plasma exchange is more difficult to judge. Since Rituximab is an anti-CD 20 monoclonal antibody it targets immature CD 20⁺ B cells rather than mature plasma cells¹⁸. The immature CD20⁺ B cells are responsible for generating short lived antibody secreting cells/plasma blasts that may be primarily responsible for nodal/paranodal antibody production early on.

Prognosis

The disability at clinical nadir is high in paranodal antibody positive patients. However, they have the potential to achieve long lasting clinical remission. This is particularly seen in patients with fulminating neuropathy requiring intensive care with presence of pan NF antibodies who go on to have a complete recovery¹⁹. Falling antibody titres are linked to clinical and electrophysiology remission facilitating more aggressive escalation of therapy. It is more difficult to prognosticate the long-term fate of patients in whom seropositivity persists.

In summary, treatment of chronic immune mediated sensorimotor neuropathies (CIN) is challenging. Up to 20% of patients do not adequately respond to first-line therapy with steroids (STE), immunoglobulins (IVIg), and plasmapheresis (PE) and require further immunotherapy²¹⁻²⁵

Studies on these treatments are limited²⁶. Two drugs used commonly in patients refractory to first-line treatment or with severe disease course are rituximab (RTX) and cyclophosphamide (CYP). RTX is a monoclonal anti-CD20 antibody selectively depleting premature B-cells. A total of 60 patients with CIDP with a response rate of 78% to RTX were reported in different case series²⁷⁻³⁰. CYP has also been reported to be a sufficient immunosuppressant therapy. In a case series of 51 CIDP patients, 35 (69%) benefited from CYP therapy. A third novel treatment in refractory CIDP is bortezomib (BTZ) – a proteasome inhibitor. In a previous case series, our group described the efficacy of BTZ in 10 CIDP patients. Further reports about the effectiveness of these therapies in CIN are necessary. The aim of this study was to retrospectively analyze clinical response to treatment with CYP, RTX, and BTZ in a cohort of 200 CIN patients.

Guidelines²⁰

European Academy of Neurology/Peripheral Nerve Society guideline on diagnosis and treatment of chronic inflammatory demyelinating polyradiculoneuropathy/Paranodopathies:

Antibody testing (PICO 5) Good Practice Points • The TF suggested to consider testing for nodal and paranodal antibodies in all patients with clinical suspicion of CIDP: when nodal and paranodal (anti-NF155, anti-CNTN1, antiCaspr1) and possibly anti-NF140/186 antibody testing is available and meeting quality standards. testing of nodal and paranodal antibodies is advised in CIDP patients with the following features: • resistance to standard therapy with IVIg and corticosteroids. • acute or subacute aggressive onset, previous diagnosis of GBS or A-CIDP. • low-frequency tremor, ataxia disproportionate to the sensory involvement or other cerebellar features or predominantly distal weakness. • respiratory failure and cranial nerve involvement. • associated nephrotic syndrome. • very high CSF protein levels. • The TF advised using for nodal and paranodal autoantibody testing: a cell-based assay using mammalian expression vectors encoding human NF155, CNTN1, NF186/NF140, and Caspr1. Expression vectors should avoid the use any protein tag at the N-terminal site, any protein tag at the C terminal site for CNTN1 and avoid the use, in general, of GFP-tagged expression vectors. a confirmatory test with ELISA (using human recombinant proteins) or teased-nerve immunohistochemistry. The order of assays can be interchanged. The application of additional confirmatory tests to the protocol is strongly recommended for low titre sera or dubious staining on the cell-based assay to avoid false positives. • The TF advised anti-MAG antibody testing in all patients with an IgM paraprotein fulfilling CIDP diagnostic criteria (especially distal CIDP) because a high titre of anti-MAG antibodies (>7000 Bühlmann Titre Units, BTU)¹⁵³ would strongly imply a different diagnosis than CIDP. • The TF advised for anti-MAG antibody testing: Bühlmann test ELISA, or Locally validated ELISA, Western blot or immunohistochemistry assays. Considerations supporting the Good Practice Points (supporting information) Evidence summary: Data from 16 cohort studies assessing the presence of nodal-paranodal and anti-MAG antibodies were extracted and analysed. Diagnostic utility seems strong for anti-NF155 and anti-CNTN1 IgG,^{67,69,72} and anti-Caspr1 IgG.^{73–75} More evidence is needed for anti-NF155 IgM,¹⁵⁴ anti-nodal NF140/186 IgG,^{76,77} and anti-MAG without an apparent paraprotein.¹⁵⁵ For autoantibodies against CNTN1 and NF155, replication studies and a systematic review¹⁵⁶ are available with clear associations to clinically relevant features and a high diagnostic specificity. For autoantibodies against Caspr1, nodal NF, and MAG, only small case series or anecdotal cases have been reported. Evidence that autoantibody detection may inform treatment remains anecdotal. Several case reports and case series associate the detection of nodal-paranodal antibodies, especially anti-NF155 and anti-CNTN1 with poorer responses to conventional therapies. There is anecdotal evidence that these patients may respond well to rituximab. Although the evidence is weak due to the low numbers of patients, the response to rituximab has been replicated in independent cohorts and the magnitude of the effect is, at least for a subset of patients, very significant. Rationale: Nodal-paranodal or MAG antibody testing should be considered in patients who fulfil criteria for CIDP, when they present with particular characteristics (Flowchart 1) and when they do not respond well to proven effective treatments for CIDP. Anti-MAG antibodies are relevant, if associated with a distal CIDP phenotype and an IgM paraprotein. The antibody testing has a low cost and positive results have significant implications for diagnosis and treatment. Access to antibody testing requires specialized laboratory procedures that are not available worldwide and standardization of the assays through interlaboratory validation needs to be performed. Patient burden is negligible.

Concluding points

- ⇒ Patients with paranodal/nodal antibodies (PNAbs) have a distinct clinical phenotype, with different electrophysiological and histological characteristics compared with seronegative chronic inflammatory demyelinating polyneuropathy (CIDP).
- ⇒ PNAbs+ patients appear less responsive to standard first-line treatments for CIDP/Guillain-Barré syndrome (GBS) (in particular intravenous immunoglobulin), and are likely to respond to rituximab clinically and serologically, although this is currently based on low- quality evidence.
- ⇒ Patients with an acute, subacute or 'atypical' (including treatment resistant) presentation of suspected GBS or CIDP should be prioritised for PNAbs testing, and we advocate early testing of all patients with suspected immune-mediated neuropathies.
- ⇒ Prolonged suppression of antibody titres may be associated with sustained clinical remission, but the reverse is not necessarily true; we need more data to establish the prognostic implications and clinical utility of serial antibody measurements.

References

1. Uncini A, Susuki K, Yuki N. Nodo-paranodopathy: beyond the demyelinating and axonal classification in anti-ganglioside antibody-mediated neuropathies. *Clin Neurophysiol* 2013; 124:1928–34.

2. Querol L, Rojas-García R, Diaz-Manera J, et al. Rituximab in treatment-resistant CIDP with antibodies against paranodal proteins. *Neurol Neuroimmunol Neuroinflamm* 2015;2: e149.
3. Kuwabara S, Yuki N, Koga M, et al. IgG anti-GM1 antibody is associated with reversible conduction failure and axonal degeneration in Guillain-Barré syndrome. *Ann Neurol* 1998; 44:202–8.
4. Quarles RH. The spectrum and pathogenesis of Antibody-mediated neuropathies. *The Neuroscientist* 1997; 3:195–204.
5. Cortese A, Lombardi R, Briani C, et al. Antibodies to neurofascin, contactin-1, and Contactin-associated protein 1 in CIDP: clinical relevance of IgG isotype. *Neurol Neuroimmunol Neuroinflamm* 2020;7. doi:10.1212/NXI.0000000000000639. [Epub ahead of print: 21 Nov 2019].
6. Thaxton C, Pillai AM, Pribisko AL, et al. Nodes of Ranvier act as barriers to restrict invasion of flanking paranodal domains in myelinated axons. *Neuron* 2011; 69:244–57.
7. Manso C, Querol L, Mekaouche M, et al. Contactin-1 IgG4 antibodies cause paranode dismantling and conduction defects. *Brain* 2016; 139:1700–12.
8. Ilyas AA, Willison HJ, Quarles RH, et al. Serum antibodies to gangliosides in Guillain- Barré syndrome. *Ann Neurol* 1988; 23:440–7.
9. Burnor E, Yang L, Zhou H, et al. Neurofascin antibodies in autoimmune, genetic, and idiopathic neuropathies. *Neurology* 2018;90: e31–8.
10. Vallat J-M, Yuki N, Sekiguchi K, et al. Paranodal lesions in chronic inflammatory demyelinating polyneuropathy associated with anti-Neurofascin 155 antibodies. *Neuromuscular Disorders* 2017; 27:290–3.
11. Koike H, Kadoya M, Kaida K-I, et al. Paranodal dissection in chronic inflammatory demyelinating polyneuropathy with anti-neurofascin-155 and anti-contactin-1 antibodies. *J Neurol Neurosurg Psychiatry* 2017; 88:465–73.
12. Boyle ME, Berglund EO, Murai KK, et al. Contactin orchestrates assembly of the septate-like junctions at the paranode in myelinated peripheral nerve. *Neuron* 2001; 30:385–97.
13. Garcia-Fresco GP, Sousa AD, Pillai AM, et al. Disruption of axo-glial junctions causes cytoskeletal disorganization and degeneration of Purkinje neuron axons. *Proc Natl Acad Sci U S A* 2006; 103:5137–42.
14. Querol L, Nogales-Gadea G, Rojas-Garcia R, et al. Neurofascin IgG4 antibodies in CIDP associate with disabling tremor and poor response to IVIg. *Neurology* 2014; 82:879–86.
15. Ilyas AA, Quarles RH, Dalakas MC, et al. Monoclonal IgM in a patient with paraproteinemic polyneuropathy binds to gangliosides containing disialosyl groups. *Ann Neurol* 1985; 18:655–9
16. Rajabally YA, Durand MC, Mitchell J, et al. Electrophysiological diagnosis of Guillain- Barré syndrome subtype: could a single study suffice? *J Neurol Neurosurg Psychiatry* 2015; 86:115–9.
17. Querol L, Rojas-García R, Diaz-Manera J, et al. Rituximab in treatment-resistant CIDP with antibodies against paranodal proteins. *Neurol Neuroimmunol Neuroinflamm* 2015;2: e149.
18. Demichelis C, Franciotta D, Cortese A, et al. Remarkable rituximab response on tremor related to acute-onset chronic inflammatory demyelinating polyradiculoneuropathy in an Antineurofascin155 immunoglobulin G4-Seropositive patient. *Mov Disord Clin Pract* 2018; 5:559–60.
19. Delmont E, Brodovitch A, Kouton L, et al. Antibodies against the node of Ranvier: a real-life evaluation of incidence, clinical features and response to treatment based on a prospective analysis of 1500 sera. *J Neurol* 2020; 267:3664–72.
20. Van den Bergh PYK, Hadden RDM, Bouche P, et al. European Federation of Neurological Societies/Peripheral Nerve; Society guideline on management of chronic inflammatory demyelinating polyradiculoneuropathy: report of a joint task force of the European Federation of Neurological Societies and the Peripheral Nerve Society - first revision. *Eur J Neurol* 2010; 17:356–63.
21. Dyck PJ, O'Brien PC, Oviatt KF, et al. Prednisone improves chronic inflammatory demyelinating polyradiculoneuropathy more than no treatment. *Ann Neurol* 1982; 11: 136–141.
22. Lopate G, Pestronk A and Al-Lozi M. Treatment of chronic inflammatory demyelinating polyneuropathy with high-dose intermittent intravenous methylprednisolone. *Arch Neurol* 2005; 62: 249–254.
23. Muley SA, Kelkar P and Parry GJ. Treatment of chronic inflammatory demyelinating polyneuropathy with pulsed oral steroids. *Arch Neurol* 2008; 65: 1460–1464.

24. Lozeron P, Denier C, Lacroix C, et al. Long-term course of demyelinating neuropathies occurring during tumor necrosis factor- α -blocker therapy. *Arch Neurol* 2009; 66: 490–497.
25. Yoon M-S, Chan A and Gold R. Standard and escalating treatment of chronic inflammatory demyelinating polyradiculoneuropathy. *Ther Adv Neurol Disord* 2011; 4: 193–200.
26. Mahdi-Rogers M, Brassington R, Gunn AA, et al. Immunomodulatory treatment other than corticosteroids, immunoglobulin and plasma exchange for chronic inflammatory demyelinating polyradiculoneuropathy. *Cochrane Database Syst Rev* 2017; 35: 1173–1163.
27. Muley SA, Jacobsen B, Parry G, et al. Rituximab in refractory chronic inflammatory demyelinating polyneuropathy. *Muscle Nerve*. Epub ahead of print 21 January 2020. DOI: 10.1002/mus.26804.
28. Roux T, Debs R, Maisonobe T, et al. Rituximab in chronic inflammatory demyelinating polyradiculoneuropathy with associated diseases. *J Peripher Nerv Syst* 2018; 23: 235–240.
29. Velardo D, Riva N, Carro UD, et al. Rituximab in refractory chronic inflammatory demyelinating polyradiculoneuropathy: report of four cases. *J Neurol* 2017; 264: 1011–1014.
30. Benedetti L, Briani C, Franciotta D, et al. Rituximab in patients with chronic inflammatory demyelinating polyradiculoneuropathy: a report of 13 cases and review of the literature. *J Neurol Neurosurg Psychiatry* 2011; 82: 306–308.

Citation: Ray PS. “Nodo-Paranodopathy: Beyond the Demyelinating and Axonal Antibody-Mediated Neuropathies”. *SVOA Neurology* 3:2 (2022) Pages 72-79.

Copyright: © 2022 All rights reserved by Ray PS., et al. This is an open access article distributed under the Creative Commons Attribution License, which permits unrestricted use, distribution, and reproduction in any medium, provided the original work is properly cited.