

# Evaluation of Foramen Magnum Dimensions Using CT Scan Images Among Sudanese Patients

Mohammed Elfatih Elbadri<sup>1</sup>, Emad Ibrahim Ahmed<sup>2\*</sup> and Fawaz Eljili<sup>1,3</sup>

<sup>1</sup>Assistant professor of orthopedic surgery and anatomy, National university, Sudan.

<sup>2</sup>Assistant professor of neurosurgery, College of medicine, Sudan University of Science and Technology department of surgery, Khartoum, Sudan.

<sup>3</sup>Registrar of Neurosurgery, MRCS, MSc (Molecular Medicine), MPH, National centre for Neurological Sciences (NCNS), Khartoum, Sudan.

\*Corresponding Author: Emad Ibrahim Ahmed, Assistant professor of neurosurgery, College of medicine, Sudan University of Science and Technology, Department of surgery, Khartoum, Sudan.

Received: October 28, 2022 Published: November 22, 2022

## Abstract

**Background:** The foramen magnum is a spot in the base of the skull through which vital organs pass. It consists of parts of the occipital bone at the axis and the temporal bones bilaterally. The purpose of this study is to evaluate the foramen magnum dimensions using CT scan images. The study is a descriptive and analytic one using different axial sections of skull images.

**Methods:** the study was carried out at Antalya Medical center- Khartoum state – Sudan at 2021. Fifty patients with well-established diagnoses of normal foramen magnum were included in the study. The maximum anteroposterior and transverse diameters of the foramen magnum were measured, the index was calculated, and the shape was identified. Statistical analysis was performed using (SPSS) version 16. Correlations between the variables were performed using ANOVA analysis, Means, and Chi-Square Tests for correlation.

**Results:** the total number of subjects under study is 50 cases, 23 are male and 27 are female. The age ranges from 20 to 70 years. Different shapes of foramen magnum were observed, and the most common is oval, with no significant difference ( $p=.277$ ) between males and females. There is a significant difference in the mean foramen magnum width of males and females ( $p=.001$ ). There is no significant change in foramen magnum length between males and females ( $p = 0.069$ ).

**Conclusion:** CT scan is a useful and effective tool for measuring foramen magnum dimensions.

**Keywords:** foramen magnum, CT scan, sundaes patients, oval shape

## Introduction

The occipital bone contains the foramen magnum, the primary foramen of the skull. In the lower portion of the posterior cranial fossa, there is only one foramen. It has an oval shape. It is a connection between the spinal canal and the cerebral cavity. The basilar process of the occipital bone forms the foramen magnum anteriorly, the left and right condylar processes laterally, and the supraoccipital portion of the occipital bone posteriorly.(1)

Forensics, anthropology, and other medical professions have found measurements of the foramen magnum to be crucial. (2)

A CT scan is a valuable, objective, quantitative, noninvasive diagnostic imaging modality that can be used to assess foramen magnum dimensions and anatomical variations for the specific alive patient with an intra or extra-Dural lesion.

The study of foramen magnum dimensions and anatomical variations using CT scan images will improve the performance of neurosurgeons and decrease the surgical challenges in this area of the body.

Some intra and extra-Dural lesions involving the foramen magnum and brainstem demonstrate a major surgical challenge. Approaches to the anatomy of this part of the skull may lead to successful surgery.

By this study could put the first step in measuring the foramen magnum dimensions among Sudanese patients.

## Objectives

### General objective

Evaluation of Foramen Magnum Dimensions using CT Scan Images.

### Specific objectives

1. To correlate gender and Foramen Magnum Dimensions.
2. There is a correlation between gender and the Foramen Magnum shape.
3. There is a correlation between age and Foramen Magnum Dimensions.
4. To find out any Foramen Magnum anatomical variations.

## Material and methods

The purpose of this study is to evaluate the foramen magnum dimensions using CT scan images. The study is a descriptive and analytic one using different axial sections of skull images.

**Sample selection:** This study was conducted on (50) patients with well-established diagnoses of normal foramen magnum at Antalya Medical Centre Khartoum State, Sudan, from May 2021 to July 2021. The patients are recruited from subjects undergoing CT scan examinations of related organ systems (medicine, surgery, and so forth). All patients were studied for clinical purposes rather than research interests.

**Inclusion and exclusion criteria:** Patients with a well-established diagnosis of normal foramen magnum were selected for the study. Any patient diagnosed with foramen magnum lesions, masses, or congenital anomalies was excluded from this study. Patients were selected from different ages, sex, and professions.

**Instrumentations:** All subjects had been examined with an advanced CT scan machine with the facility of superior image quality, digital printer, hard copy devices and video recorders. The machine used in this study is (a GE Lightspeed 8 Ultra CT scanner) which is one of the fastest 8-slice CT machines. It has a fast speed, low dose, and high-resolution images. GE Lightspeed Ultra 8 Features are 6.3 MHU Tube, Solid State Detectors, High-Performance DAS, Operators Console, 53KW Generator, 10 to 440 MA, Sub-second Scan Time, Dual Monitors, Helical Tilt, Var viewer 70 CM Gantry Aperture, Magnetic Optical Disk Storage, +/- 30 Degree Gantry Tilt, 120 Second Helical. The applications of GE Lightspeed 8 Ultra CT are abdominal, angiography, brain, dental, pediatrics, perfusion, and radiotherapy. Foramen magnum dimensions are read and measured with the Centricity DICOM Viewer and software version 3.1.2 from GE Healthcare.

## Method of study

The technician performed a CT scan of the brain. The image section is immediately displayed on the DICOM Viewer for evaluation. An individualized approach to evaluate the foramen magnum dimensions was taken using axial sections. The maximum anteroposterior and transverse diameters of the FM were measured by the researcher and confirmed by the technologist and radiologist. The FM index was calculated by dividing the AP diameter of the FM by the transverse diameter. The shape was identified according to index and observation. Electronic calipers are used in the measurement.

**Data collection:** All data were collected from patients' files and archived CT images using a data collection sheet designed specifically for redundant research by the researcher.

**Statistical analysis method:** Statistical analysis was performed using the Statistical Package for the Social Sciences (SPSS) version 16 (SPSS, Chicago, Illinois, USA) and Microsoft Excel 2013. Data was expressed as frequencies and as a proportion for continuous and categorical variables. The maximum, minimum, and mean calibers were calculated. Correlations between the variables were performed using ANOVA analysis, Means, and Chi-Square Tests for correlation. Probabilities of  $p < 0.05$  were considered statistically significant. The results were presented as tables and graphs and discussed in detail; the conclusion was recorded.

**Ethical issues:** CT scanning of these patients forms part of a routine. There is no patient identification or individual patient details.

**Data storage:** All data collected during this study were stored in secured files on personal computers (PC), soft copy devices, data collection sheets, and a CT image.

## Results

This study is intended to evaluate the foramen magnum dimension and shape in patients holding normal foramen magnum using CT scan images. The evaluations include the measurements of length, width, and index in the Sudanese population. A correlation was found between the foramen magnum dimension and gender, age, and shape. There was some previously published literature in the evaluation of foramen magnum dimensions using CT scan images, but to our knowledge, there was no previously available published literature specifically on this topic in Sudan. All patients being studied for clinical purposes rather than research purposes were given verbal permission.

A total of 50 CT scans were performed for 50 patients (cases) referred to the radiology department for a brain CT scan. The scans were performed and images of the skull and brain were obtained. The measurements of anteroposterior (AP) diameter in the long axis and transverse diameter were taken, and the index was calculated by dividing the length by width. The results were tabulated in the form of figures and tables depending on the different variables used in the study; they are shown on the following pages.

### Baseline characteristics of the study population

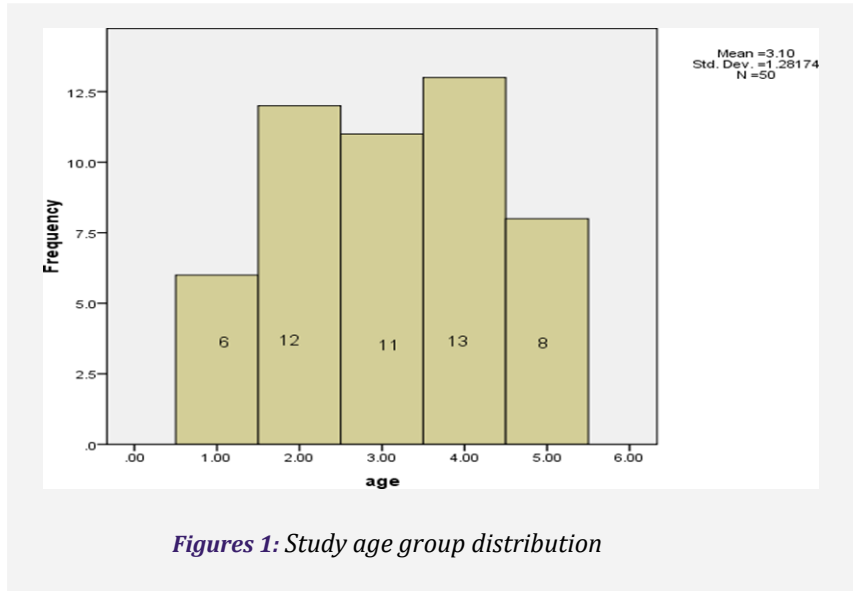
As shown in table (1), the total number of subjects under study is 50. Of these, 23(46%) are male and 27(54%) are female. The age of the study group ranged from 20 to 70 years old. (Table.2), divided into five groups. The Frequency of group1 (20-30) is six patients (12%), group2 (31-40) is twelve patients (24%), group3 (41-50) is eleven patients (22%), group 4 (51-60) is thirteen patients (26%), group5 (61-70) is eight patients (16%) fig (1). The anteroposterior (length) diameter of the foramen magnum measures a mean of 35.3870 mm (ranging from 23.33mm to 46.51 mm), and the transverse(width) diameter measures a mean of 28.3590 mm (ranging from 22.75mm to 37.90 mm). Table 3: As shown in figure (2), the most common foramen magnum shapes observed in this study are oval, circular, irregular, and others, with a frequency of 27 (54%), 14(28%), 5 (10%), and 4(8%), respectively.

**Table 1:** Study group gender distribution.

| G     | Frequency | Percent | Valid Percent | Cumulative Percent |
|-------|-----------|---------|---------------|--------------------|
| M     | 23        | 46.0    | 46.0          | 46.0               |
| F     | 27        | 54.0    | 54.0          | 54.0               |
| Total | 50        | 100     |               | 100                |

**Table 2:** Study age group distribution.

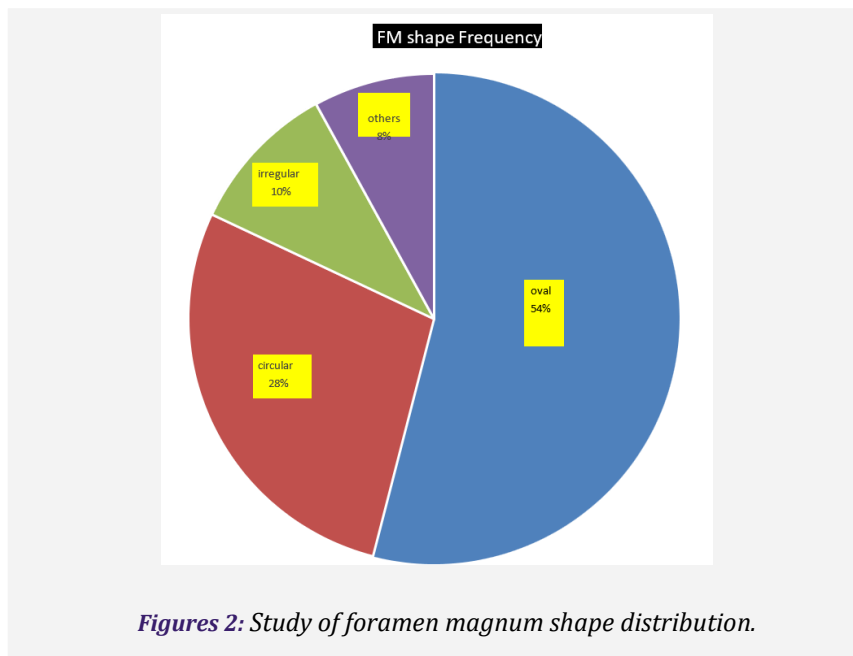
| Group age | Frequency | Percent | Valid Percent | Cumulative Percent |
|-----------|-----------|---------|---------------|--------------------|
| G1(20-30) | 6         | 12.0    | 12.0          | 12.0               |
| G2(31-40) | 12        | 24.0    | 24.0          | 36.0               |
| G3(41-50) | 11        | 22.0    | 22.0          | 58.0               |
| G4(51-60) | 13        | 26.0    | 26.0          | 84.0               |
| G5(61-70) | 8         | 16.0    | 16.0          | 36.0               |



Figures 1: Study age group distribution

Table 3: Study of foramen magnum dimensions.

|         | N  | Minimum | Maximum | Mean    | Std. Deviation |
|---------|----|---------|---------|---------|----------------|
| Fm(l)   | 50 | 23.33   | 46.51   | 35.3870 | 4.41134        |
| Fm(w)   | 50 | 22.75   | 37.90   | 28.3590 | 3.45715        |
| Valid N | 50 |         |         |         |                |



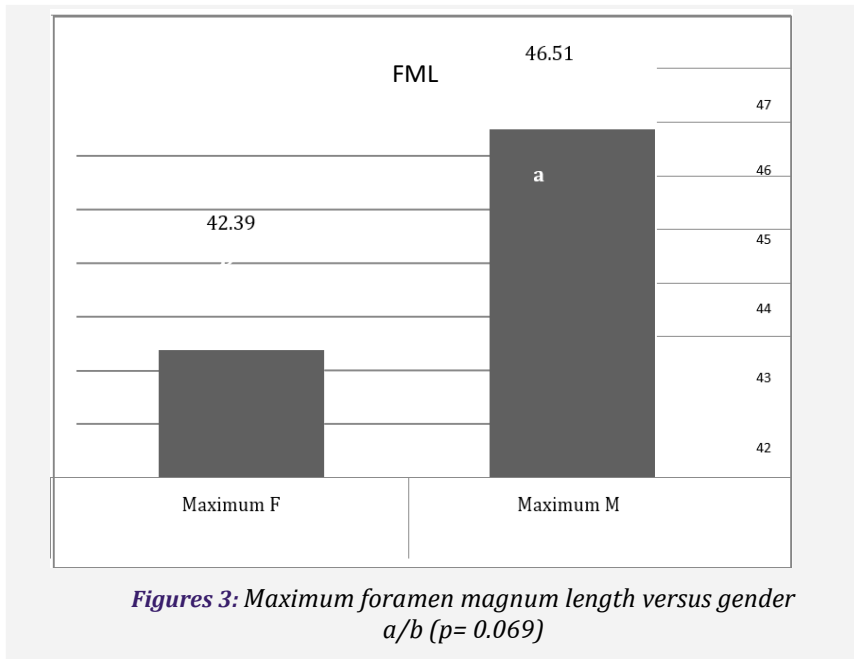
Figures 2: Study of foramen magnum shape distribution.

**Correlations of variables**

**Influence of gender on foramen magnum dimensions:**

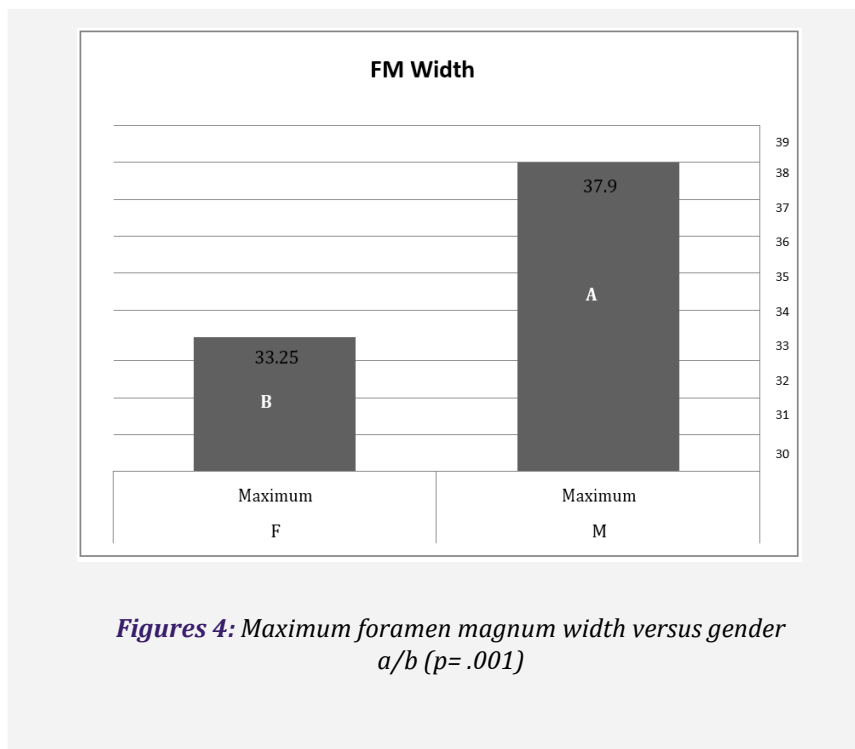
**Influence of gender on foramen magnum length (FML):**

As shown in Figure (3), there is a slight difference between males and females in FML, and it is not significant (p = 0.069). The mean FML of the male is 36.3± 4.679 mm and the mean FML of the female is 34.58±4.084 mm. The maximum FML of the male is 46.51mm, and the maximum FML of the female is 42.39mm (fig 3). The minimum FML of the male is 26.19mm, and the minimum FML of the female is 23.33mm. Table (4).



**The influence of gender on foramen magnum width (FMW)**

As shown in Figure 4, there is a significant difference in the mean FMW of males and females (p =.001). The mean FMW of the male is 29.661±3.309, and the mean FMW of the female is 27.249±3.23. The maximum FMW of the male is 37.9mm, and the maximum FMW of the female is 33.25mm (fig 4). The minimum FMW of the male is 22.75, and the minimum FMW of the female is 22.87. Table (4)

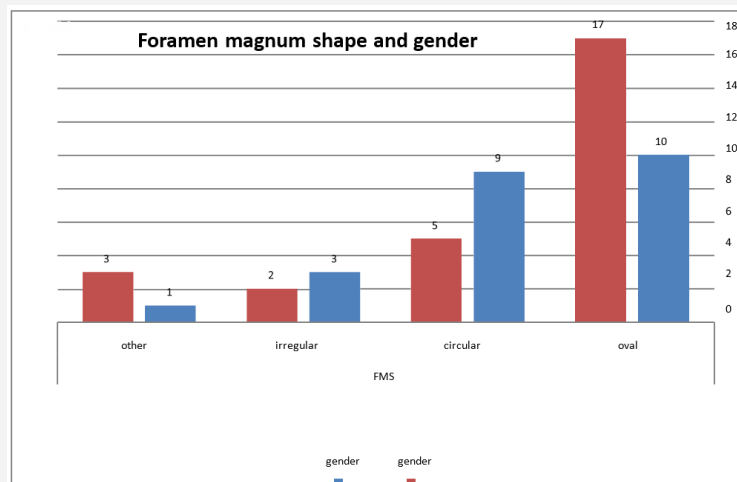


**Table 4:** Influence of gender on foramen magnum dimensions.

| Gender       |                | Fm(l)   | Sig  | Fm (w)  | Sig  |
|--------------|----------------|---------|------|---------|------|
| <b>M</b>     | N              | 23      | .069 | 23      | .001 |
|              | Maximum        | 46.51   |      | 37.90   |      |
|              | Minimum        | 26.19   |      | 25.50   |      |
|              | Mean           | 36.6122 |      | 30.0452 |      |
|              | Std. Deviation | 4.78046 |      | 2.96511 |      |
| <b>F</b>     | N              | 27      |      | 27      |      |
|              | Maximum        | 42.39   |      | 33.25   |      |
|              | Minimum        | 23.33   |      | 22.75   |      |
|              | Mean           | 34.3433 |      | 26.9226 |      |
|              | Std. Deviation | 3.85727 |      | 3.22916 |      |
| <b>Total</b> | N              | 50      |      | 50      |      |
|              | Maximum        | 46.51   |      | 37.90   |      |
|              | Minimum        | 23.33   |      | 22.75   |      |
|              | Mean           | 35.3870 |      | 28.3590 |      |
|              | Std. Deviation | 4.41134 |      | 3.45715 |      |

**Influence of gender on the foramen magnum shape.**

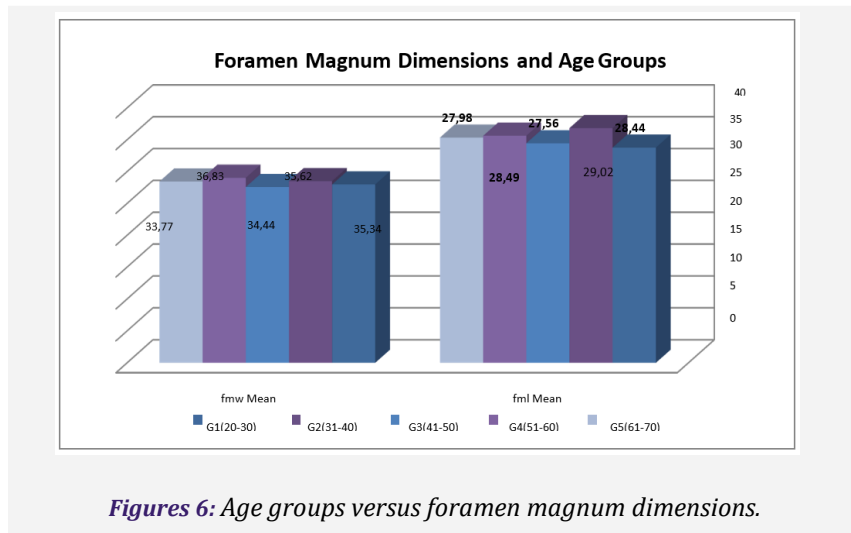
As shown in fig (6) there is no significant difference ( $p=.277$ ) in the foramen magnum shape of the males and females. There are 10 cases of oval FM in males and 17 cases in females. There are 9 cases of circular FM in males and 5 cases in females. There are 3 cases of irregular FM shape in males and 2 cases in females. There is only one case of another FM shape in males and three cases in females.



**Figures 5:** Foramen magnum shape versus gender ( $p= .229$ )

### Influence of age in foramen magnum dimensions

As shown in figure (6) there is no significant difference ( $p=.638$ ) in the mean FML of different age groups. The mean FML in G1 is 33.770 (ranging from 31.66 to 36.1). The mean FML in G2 is 36.83 (ranging from 30.03 to 43.05). The mean FML in G3 is 34.4 (ranging from 26.19 to 46.51). The mean FML in G4 is 35.62 (ranging from 31.3 to 43.01). The mean FML in G5 is 35.34 (ranging from 23.33 to 42). In addition, there is no significant difference ( $p=.896$ ) in the mean FMW of different age groups. The mean FMW in G1 is 27.98 (ranging from 23.56 to 30.75). The mean FMW in G2 is 28.4958 (ranging from 22.87 to 32.95). The mean FMW in G3 is 27.5691 (ranging from 23.44 to 31.40). The mean FMW in G4 is 29.02 (ranging from 22.92 to 35.50). The mean FMW in G5 is 28.4 (ranging from 28.4 to 37.9).



Figures 6: Age groups versus foramen magnum dimensions.

### Discussion

In this study high quality, CT brain images were performed using an advanced CT scan with a DICOM viewer for processing and measurement of the foramen magnum CT image. This mode is very useful in viewing the foramen magnum and related structures. The ability to follow the whole cavity of the foramen magnum on adjacent images can help to confirm the maximum diameter full ring foramen magnum. Following a structure, in combination with the knowledge of normal diameter and shape and variants, usually allows differentiation.

The main objectives of this study are to evaluate the length, width, and shape of the foramen magnum in different gender and group aging.

Awadh k et al(3), from Turkey, stated that the FM Anteroposterior diameter is 35.9mm and transverse diameter 30.4mm in Turkish population, Gruber et al(4) stated that the FM Anteroposterior diameter is 36.6mm and transverse diameter 30.4mm in Europe population, Mahajan et al(5), stated that the FM Anteroposterior diameter is 32.83mm and transverse diameter is 27.47 in Chandigarh population, Sampada PK et al(6) stated that the FM Anteroposterior diameter is 34.84mm and transverse diameter is 29.39mm in Karnataka population, Sharma S et al(7) stated that the FM Anteroposterior diameter is 34.17mm and transverse diameter 28.86mm, in the Present study 2021 the FM Anteroposterior diameter is 35.38mm and transverse diameter 28.35mm.

The maximum length and width of the foramen magnum were measured using electronic caliper.

The current study showed that there is a slight difference in the FML between males and females. This agrees with Kanodia Get al (8), Awadh k et al(3), Gruber et al(4) and Kamath et al(9) 'Uthman et a(10) from Iraq using reconstructed helical CT images, reported great differences between males and females FML.

The current study showed a significant difference in the FMW between males and females.

This agrees with 'Uthman et al(10), Sharma S et al(7), and Awadh k et al t(3)

The current study showed no difference in the shape of the FM between males and females and the most common shape is the oval one. This finding is following what was reported by Dasegowda et(11)al, and Muthukumar et al(12). In contrast, this result disagrees with Awadh k et al(3), from Turkey, who used a millimetric sliding caliper to measure the foramen magnum on cranial computerized tomographic images (CT) of 110 normal subjects (57 males - 53 females); and stated that the FM was found to be oval in 8.1%, egg-shaped in 6.3%, round in 21.8%, tetragonal in 12.7%, pentagonal in 13.6%, hexagonal in 17.2%, irregular (A) in 10.9% and irregular (B) in 9.09%.

The study also disagrees with Shaikh v et(13) al from India, who stated that the incidence of these types had the following frequency of distribution: The oval-shaped FM follows next (16.6%), and is more frequently seen in the adult group (male: 23.3% and female: 26.4%), than the adolescent (male: 15.9% and female: 15.3%) or foetal group (1.85%).

Next is the hexagonal shape (15.3%) which is more frequent in the adult female group (26.4%), followed by the adolescent male group (20.4%).

The rhomboid shape follows (14%) and is more frequent in adolescent males (20.4%) and adolescent female (23%) than the adult male (11.6%) and adult females (17.6%) and foetal group (5.5%).

Their differences in result may be due to different equipment, environment, ethnic group, and/or different genetic factor. The effect of the low population of this study should not be ignored. This current study showed that there is no difference in the FM dimension in different adult group aging.

In the current and previous studies, it was observed that the measurements of the foramen magnum are slightly increased when using CT images, this is probably due to magnification during imaging. Throughout the current study, there were no clear anatomical variations observed, except for some rare types of foramen magnum shapes eggs; irregular and pentagonal shapes.

## Conclusion

- CT scan is a very useful and effective tool in the evaluation of the foramen magnum dimensions and shape in life cases.
- The foramen magnum width is different between males and females.
- There is no difference in length between males and females.
- There is no change in the foramen magnum shape between different adult age groups.
- Foramen magnum shape is not affected by gender.

## Recommendation

- For more accuracy, using a large population sample from a different ethnic group is recommended.
- Moreover, measurement of the height is recommended for reconstructed 3D CT scan images.
- Using and comparison between different methods in measuring the foramen magnum will be effective.

## Conflict of Interest

The authors declare no conflict of interest.

## Reference

1. Sarthak J, Batham I K. Evaluation of foramen magnum in gender determination using helical CT scanning in Gwalior population [Internet]. 2016. Available from: [www.ijmrr.in](http://www.ijmrr.in)
2. Krishan K. Craniometric Analysis of Foramen Magnum for Estimation of Sex Cite this paper.
3. Awadh K. Morphometric Evaluation of the Foramen Magnum and Variations Morphometric Evaluation of the Foramen Magnum and Variations in its Shape: A Study on Computerized Tomographic Images of in its Shape: A Study on Computerized Tomographic Images of Normal Adults Normal Adults [Internet]. Vol. 33, Turkish Journal of Medical Sciences. Available from: <https://journals.tubitak.gov.tr/medical>
4. Gruber P, Henneberg M, Böni T, Rühli FJ. Variability of human foramen magnum size. *Anatomical Record*. 2009 Nov;292(11):1713–9.
5. Mahajan D. An anatomical perspective of human occipital condyles and foramen magnum with neurosurgical correlates. *Anatomy (International Journal of Experimental and Clinical Anatomy)*. 2013;6–7:29–33.
6. P K S, B P, M M, B Sakri S. MORPHOMETRIC AND MORPHOLOGICAL STUDY OF FORAMEN MAGNUM IN DRIED HUMAN SKULL BONES. *International Journal of Anatomy and Research [Internet]*. 2017 Apr 30;5(2.1):3682–6. Available from: <https://www.ijmhr.org/IntJAnatRes/IJAR.2017.139>
7. Sharma S, Mathur S, Joshi P, Gupta UK. MORPHOLOGICAL AND MORPHOMETRIC STUDY OF FORAMEN MAGNUM IN DRIED HUMAN SKULL BONES OF NORTH-WEST INDIAN REGION. *International Journal of Anatomy and Research [Internet]*. 2020 Nov 10;8(4.1):7777–81. Available from: <https://www.ijmhr.org/IntJAnatRes/IJAR.2020.217>
8. Kanodia G, Parihar V, Yadav YR, Bhatele PR, Sharma D. Morphometric analysis of posterior fossa and foramen magnum. *J Neurosci Rural Pract*. 2012 Sep;3(3):261–6.



9. Kamath VG, Asif M, Shetty R, Avadhani R. Binary Logistic Regression Analysis of Foramen Magnum Dimensions for Sex Determination. *Anat Res Int*. 2015 Aug 5;2015:1–9.
10. Uthman AT, Al-Rawi NH, Al-Timimi JF. Evaluation of foramen magnum in gender determination using helical CT scanning. *Dentomaxillofacial Radiology*. 2012 Mar 1;41(3):197–202.
11. Dasegowda G, Padmalatha K, Priyanka B P, Mirmire S. MORPHOLOGY AND MORPHOMETRIC ANALYSIS OF FORAMEN MAGNUM IN ADULT HUMAN SKULLS. *International Journal of Anatomy and Research* [Internet]. 2020 Nov 10;8(4.1):7771–6. Available from: <https://www.ijmhr.org/IntJAnatRes/IJAR.2020.212>
12. Muthukumar N, Swaminathan R, Venkatesh G, Bhanumathy SP. A morphometric analysis of the foramen magnum region as it relates to the transcondylar approach. *Acta Neurochir (Wien)*. 2005 Aug;147(8):889–95.
13. Shaikh V. Morphological And Morphometric Study Of The Major Foramina At The Base Of Human Skull, Their Symmetry On Right And Left Side In Various Age Groups And In Both The Sexes, Including Foetal Skull View project Medical Education Research View project [Internet]. Article in *International Journal of Advanced Research*. 2015. Available from: <https://www.researchgate.net/publication/340634716>

**Citation:** Elbadri ME, Ahmed EI, Eljili F. “Evaluation of Foramen Magnum Dimensions Using CT Scan Images Among Sudanese Patients”. *SVOA Neurology* 2022, 3:6, 255-263.

**Copyright:** © 2022 All rights reserved by Ahmed EI., et al. This is an open access article distributed under the Creative Commons Attribution License, which permits unrestricted use, distribution, and reproduction in any medium, provided the original work is properly cited.