

Case Report: Apoplexy Associated with Prostatic Carcinoma Metastasis in Epidural Extramedullary Tumour Tissue

Avila-Cervantes Rodrigo, MD^{1*}, Avila-Ramirez Jose, MD¹, Ulibarri-Vidales Mario, MD², Curiel-Valdes Jose de Jesus, MD³, Avila-Anguiano Emmanuel, MD³, Navarrete-Pacheco Mayra, MD², Solorio-pineda Saul, MD⁴, Alvarez-Perera Luis Angel, MD⁵, Hernandez-Luna Jackeline, MD³ and San-Juan Daniel, MD⁶

¹Angeles de Pedregal Hospital, Neurosurgery, Mexico City, Mexico

²Instituto Nacional de Ciencias Médicas y Nutrición Salvador Zubiran (INCMNSZ), Mexico

³HMG HOSPITAL, Coyoacán, Mexico

⁴Instituto Nacional de Rehabilitación de México

⁵Universidad Popular Autónoma del Estado de Puebla, México

⁶Instituto Nacional de Neurología y Neurocirugía Manuel Velasco Suárez de México (INNNMVS), Mexico

***Corresponding Author:** Dr. Avila-Cervantes Rodrigo, MD, Angeles de Pedregal Hospital, Neurosurgery, Mexico City, Mexico.

Received: October 09, 2022 **Published:** January 17, 2023

DOI: Registering

Abstract

Background: Prostate cancer (PCa) is unique among potentially lethal human malignancies because of the wide discrepancy between the considerable prevalence of histological changes recognizable as prostate cancer and the smaller prevalence of the clinical disease itself. Spinal Metastasis (SpM) may also be the first sign of malignancy in patients with previously undiagnosed PCa, causing numerous complications associated with the acceleration of bone resorption and an increase in bone pain, pathological fractures, and spinal cord compressions. The main treatment options for patients with SpM are analgesics, corticosteroids, chemotherapy, radiotherapy and surgery.

Case presentation: A 68-year-old man in the emergency service presented a sudden onset of chest pain, paraplegia and sphincter incontinence 24 hours prior to his admission; Magnetic resonance imaging (MRI) showed a meningeal extramedullary tumor at the level of D3 to D4 causing spinal compression, secondary syringomyelia, multiple dorsal bone metastases, mediastinal lymph node conglomerates, left dorsal scoliosis, multilevel disc extrusion with radiculopathy, a narrow dorsal canal at D3-D4 level, and, in D3-D4 D9-D10, yellow ligament hypertrophy and multilevel facet sclerosis.

Conclusions: Decompression of the spinal canal and removal of the tumour was completed, the patient was sent to physical rehabilitation. Follow-up is performed at 6 months and a year with recovery of strength and coordination of pelvic and thoracic limbs.

Keywords: prostatic carcinoma, spine, apoplexy, metastasis, tumor, cancer, tissue, surgery.

List of abbreviations

MRI: Magnetic resonance imaging

CT: Computed tomography

PCa : Prostate Cancer

Spm: Spinal Metastasis

Background

Prostate cancer is unique among potentially lethal human malignancies because of the wide discrepancy between the considerable prevalence of histological changes recognizable as prostate cancer and the smaller prevalence of the clinical disease itself. Approximately 30% of men with prostate cancer have distant metastases at the time of diagnosis. Meanwhile, although more than 30% of all men older than 50 years have been shown to harbour prostate cancer, only 9% develop clinical disease. Approximately 15% of patients have a locally extensive stage C or T tumour at the time of diagnosis. (1) Bubendorf²

Detailed findings about the distribution of metastases of 100 consecutive patients shows a decreasing prevalence dependant on location (figure 1). Metastases found exclusively in the thoracic or cervical spine was recorded in only 2% and 1% of these patients respectively. Metastases were rarely recorded in other bones such as ribs (18.2%), long bones (15%), and skull (8%), but these sites were not systematically examined during autopsy. (2)

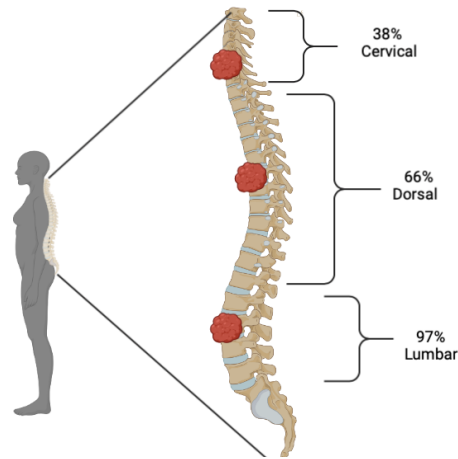


Figure 1. Spinal metastasis percentage Bubendorf L, Schöpfer A, (Et.Al). Metastatic patterns of prostate cancer: an autopsy study of 1,589 patients. *Hum Pathol.* 2000 May;31(5):578-83.

Prostate Cancer caused 365,933 deaths (95% uncertainty interval 303,492-459,614) around the world in 2015, an increase of 91% from 191,896 deaths (95% uncertainty interval 154,039-236,473) in 1990. The number of deaths increased in all sociodemographic index quintiles. Globally, the highest number of PCa deaths occurred in men 70 years old or older across all the age groups studied. The challenge of PCa treatment must be addressed in multiple ways: ensuring access to health care for everyone, diagnosing aggressive cancers early without causing harm by treating indolent cancers, and developing easily-tolerated treatment regimes while making them available to all patients with PCa. (3)

Metastasis can occur in any bone in the body but is most often found in bones near the body's centre. The spine is the most common site of bone metastasis. It is estimated that over 10% of patients with cancer develop symptomatic spinal metastasis. The initial anatomic location of metastases within vertebrae is in the posterior portion of the body. Analysis of CT scans show that the body is involved before the pedicles. Destruction of the pedicles occurs only in combination with the involvement of the vertebral body. (4)

Spinal Metastasis (SpM) may also be the first sign of malignancy in patients with undiagnosed PCa as numerous complications associated with the acceleration of bone resorption start to develop with the condition, causing an increase in bone pain, pathological fractures, and spinal cord compressions. (5) SpM, with or without cord compression, is a debilitating and common complication of cancer. More than 20,000 new cases are reported each year in the United States. These complications contribute to decreased ambulatory/neurological status, quality of life, and survival. The main treatment options for patients with SpM are analgesics, corticosteroids, chemotherapy, radiotherapy and surgery. (6)

Unlike many other cancers, sites of disease such as lung, liver, and soft tissue have traditionally been less commonly encountered clinically. (7,8) Obesity and weight gain in adulthood have been linked with a higher risk of advanced and fatal prostate cancer as well as prostate cancer recurrence and survival (8,9). Gonadotropin-releasing hormone agonists, used widely in the treatment of metastatic prostate cancer and hormone receptor-positive breast cancer, are associated with a rare but potentially fatal outcome of pituitary apoplexy (PA). (10) Assessment of a man's genetic risk of developing prostate cancer has promise for guiding individualized screening decisions (11).

Mutationally activated kinases play an important role in the progression and metastasis of many cancers. The RAF family, MERTK, and NTRK2 drove bone and visceral metastasis and were clearly visible in human metastatic prostate cancer tissues (12). Despite early detection of the primary tumour, bone metastases were already detected in up to 10% of patients at the early stages of Pca diagnosis. Additionally, 20%–30% of the patients subjected to radical prostatectomy (RP) for organ-confined (stage T1–T3) PCa relapsed and fatally progressed to a more advanced form of disease. 70%–80% of those patients will harbour bone metastases. (13)

Case Presentation

A 68-year-old man in the emergency service presented a sudden onset of chest pain, paraplegia and sphincter incontinence 24 hours prior to his admission. The patient had a history of diabetes and hypertension over many years and didn't receive treatment for these chronic diseases. No previous history of trauma or other symptoms were reported.

After being admitted, the patient's initial evaluation displayed temperature at 36°C, blood pressure at 110/82mmHg, heart rate at 82 beats per minute, SatO₂ at 94%, and alertness at Glasgow 15/15. During the physical examination the patient had paraparesis of both legs and hyperalgesia below the T4 level, patellar areflexia, and a diminished Achilles reflex.

Laboratory data revealed a white blood cell count of $7.9 \times 10^3/\mu\text{L}$ with 86.1% segmented neutrophils and 10.4% lymphocytes – levels suggesting lymphopenia and neutrophilia, an erythrocyte count of $4.11 \times 10^6/\mu\text{L}$ with 37% hematocrit, and glucose of 203 mg/dL. The rest of the laboratory data is represented in table 1.

Table 1: Laboratory data

	Values	Normal range	Unit of measurement
Prostate – specific antigen	5085.54	0.05 – 4	Ug/L
Triglycerides	91	<150	mg/dL
Thrombocytes	201	130 – 480	$10^3/\mu\text{L}$
Leukocytes	7.9	3.9-11.1	$10^3/\mu\text{L}$
Erythrocytes	4.11	4.2-6.1	$10^6/\mu\text{L}$
Hemoglobin	13.1	13 – 18.1	g/dL
Hematocrit	37	37.7 - 56	%
Prothrombin time (PT)	16.5 (75%)	13.5	Seconds
Serum Creatinine	0.7	0.72 – 1.25	Mg/dL
Serum glucose	203	70-99	Mg/dL
Total Cholesterol	172	130-199	Mg/dL

Magnetic resonance imaging (MRI) showed a meningeal extramedullary tumor at the level of D3 to D4 causing spinal compression, secondary syringomyelia, multiple dorsal bone metastases, mediastinal lymph node conglomerates, left dorsal scoliosis, multilevel disc extrusion with radiculopathy, a narrow dorsal canal at D3-D4 level, and, in D3-D4 D9-D10, yellow ligament hypertrophy and multilevel facet sclerosis. The MRI also displayed syringomyelia changes in the spinal cord; inflammatory changes and infiltrations in T3-T6; dorsal spondylosis; right convex scoliosis and decreased bone density; T10-T11 discarthrosis; lithic lesions in T3, T11, T4 and C7 vertebral bodies; conglomerate mediastinal lymph nodes; a narrow lumbar canal L2-L3 and L3-L4 with bilateral involvement of the foramina conjunction; osteoarthritis and lumbar facet synovitis in the lumbar segments; and thickening of the yellow ligament.

A triphasic computed tomography (CT) scan of the abdomen and pelvis revealed voluminous retroperitoneal tumour activity, inflammatory changes in peripheral fat, diverticular disease, prostatic hypertrophy, hepatic cysts, bilateral mild renal ectasia with associated extra-renal pelvis, focal lesion in the body of L1, bilateral pleural effusion, bilateral basal atelectasis, and changes in the density of the pulmonary interstitial space of the right middle lobe.

Treatment

The patient was taken into emergency service for T3-T6 right hemilaminectomy, with complete macroscopic excision of the lesion. Surgery was performed in the prone position. Right hemilaminectomy of the T3-T4, T4-T5, T5-T6 vertebrae was performed during the surgery and vascular grey tissue surrounded by a dark reddish hematoma with soft consistency was found. The hematoma was aspirated. The grey tissue, softly adhered to the dura matter was carefully dissected and excised.

Intraoperative neuromonitoring was performed. No changes were noted in electromyography (EMG), somatosensory-evoked potentials (SSEP) or the motor-evoked potentials (MEPs) of the lower limbs during the surgery.

Histological examination

At histopathological examination, a malignant mass composed of small, monomorphic cells with round hyperchromatic nuclei was found. The cytoplasm was poorly defined, granular and eosinophilic due to large areas of necrosis and haemorrhage. The cells had also infiltrated the surrounding connective tissue and yellow ligament. Hemorrhagic areas and inflammatory infiltrates formed by polymorphonucleates and macrophages with hemosiderin were discovered as well.

The histology report revealed a prostate metastatic cancer (Image 2), with positive immunohistochemistry for prostate specific antigen, and a 3% proliferation index with Ki67. The final diagnosis was metastasis of prostatic adenocarcinoma to extramedular epidural tissue.

Outcome and follow-up

The patient did not have any motor or sensory improvement immediately after the surgery, although he experienced no pain. At the 6-weeks follow up, slight sensory improvement was present but no motor improvement was shown.

Discussion and Conclusions

In the literature is very poorly the information about this pathology and its clinical presentation. Mixter and Barr first provided the description of herniated disk causing sciatica in 1934. The surgical technique focuses on a less invasive surgical approach with decreased surgical manipulation and trauma to the paraspinal muscles, ligamentum flavum, and the affected nerve root. Advances in fluoroscopy, image-guided techniques, and high-resolution endoscopy, along with the widespread use of tubular retractors, have provided surgeons with a minimally invasive form of lumbar discectomy. With these minimally invasive retractors, it was possible to maximize the visualization of the anatomy. The measurements of the adenocarcinoma are illustrated in the histopathological study (figure 2). Once with decompression of the spinal canal and removal of the tumour was completed, the patient was sent to physical rehabilitation. Follow-up is performed at 6 months and a year with recovery of strength and coordination of pelvic and thoracic limbs.

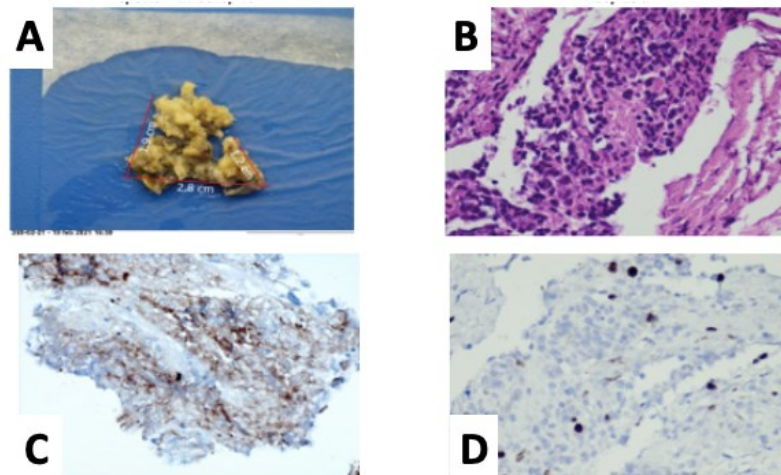


Figure 2. A.- Specimen received macroscopic. B Photomicrograph (400X) stained with HE, small cells diffuse infiltration to soft tissues. C.- immunohistochemistry with prostate specific antigen stains cytoplasm positive. D.- immunohistochemistry with proliferative antibody Ki67 with 3% positive cells.

Conflict of Interest

The authors declare no conflict of interest.

References

- Scardino PT, Weaver R, Hudson MA. Early detection of prostate cancer. *Hum Pathol.* 1992 Mar;23(3):211-22.
- Bubendorf L, Schöpfer A, Wagner U, Sauter G, Moch H, Willi N, Gasser TC, Mihatsch MJ. Metastatic patterns of prostate cancer: an autopsy study of 1,589 patients. *Hum Pathol.* 2000 May;31(5):578-83.
- Pishgar F, Ebrahimi H, Saeedi Moghaddam S, Fitzmaurice C, Amini E. Global, Regional and National Burden of Prostate Cancer, 1990 to 2015: Results from the Global Burden of Disease Study 2015. *J Urol.* 2018 May;199(5):1224-1232.
- Maccauro G, Spinelli MS, Mauro S, Perisano C, Graci C, Rosa MA. Physiopathology of spine metastasis. *Int J Surg Oncol.* 2011;2011:107969

5. Amelot A, Terrier LM, Le Nail LR, Cristini J, Cook AR, Buffenoir K, Pascal-Moussellard H, Carpentier A, Dubory A, Mathon B. Spine metastasis in patients with prostate cancer: Survival prognosis assessment. *Prostate*. 2021 Feb;81(2):91-101.
6. Beaufort Q, Terrier LM, Dubory A, Le Nail LR, Cook AR, Cristini J, Buffenoir K, Pascal-Moussellard H, Carpentier A, Mathon B, Amelot A. Spine Metastasis in Elderly: Encouraging Results for Better Survival. *Spine (Phila Pa 1976)*. 2021 Jun 1;46(11):751-759.
7. Doctor SM, Tsao CK, Godbold JH, Galsky MD, Oh WK. Is prostate cancer changing?: evolving patterns of metastatic castration-resistant prostate cancer. *Cancer*. 2014 Mar 15;120(6):833-9.
8. Pernar, C. H., Ebot, E. M., Wilson, K. M., & Mucci, L. A. (2018). The Epidemiology of Prostate Cancer. *Cold Spring Harbor perspectives in medicine*, 8(12).
9. Dickerman, B. A., Ahearn, T. U., Giovannucci, E., Stampfer, M. J., Nguyen, P. L., Mucci, L. A., & Wilson, K. M. (2017). Weight change, obesity and risk of prostate cancer progression among men with clinically localized prostate cancer. *International journal of cancer*, 141(5), 933–944.
10. Tanios, G., Mungo, N. A., Kapila, A., & Bajaj, K. (2017). Pituitary apoplexy: a rare complication of leuprolide therapy in prostate cancer treatment. *BMJ case reports*, 2017,
11. Huynh-Le, M. P., Fan, C. C., Karunamuni, R., Et. Al. ... PRACTICAL Consortium (2020). A Genetic Risk Score to Personalize Prostate Cancer Screening, Applied to Population Data. *Cancer epidemiology, biomarkers & prevention: a publication of the American Association for Cancer Research, cosponsored by the American Society of Preventive Oncology*, 29(9), 1731–1738.
12. Faltermeier, C. M., Drake, J. M., Clark, P. M., Smith, B. A., Zong, Y., Volpe, C., Mathis, C., Morrissey, C., Castor, B., Huang, J., & Witte, O. N. (2016). Functional screen identifies kinases driving prostate cancer visceral and bone metastasis. *Proceedings of the National Academy of Sciences of the United States of America*, 113(2), E172–E181. <https://doi.org/10.1073/pnas.1521674112>
13. Manna, F., Karkampouna, S., Zoni, E., De Menna, M., Hensel, J., Thalmann, G. N., & Kruithof-de Julio, M. (2019). Metastases in Prostate Cancer. *Cold Spring Harbor perspectives in medicine*, 9(3), a033688.

Citation: Rodrigo AC, Jose AR, Mario UV, de Jesus CVJ, Emmanuel AA, Mayra NP, Saul SP, Angel APL, Jackeline HL, Daniel SJ. Case Report: Apoplexy Associated with Prostatic Carcinoma Metastasis in Epidural Extramedullary Tumour Tissue. *SVOA Neurology* 2023, 4:1, 01-05.

Copyright: © 2023 All rights reserved by Rodrigo AC., et al. This is an open access article distributed under the Creative Commons Attribution License, which permits unrestricted use, distribution, and reproduction in any medium, provided the original work is properly cited.