

Radio Induced Temporal Meningioma: A Rare Case Report and Literature Review

Badache K^{1*}, Habchi N^{1,2} and Djafer M¹

¹Department of Neurosurgery, Mustapha PACHA Hospital, Algeria.

²Department of Endocrinology, University of Science and Technology Houari Boumediene, Algeria.

*Corresponding Author: Badache K, Department of Neurosurgery, Mustapha PACHA Hospital, Algeria.

DOI: <https://doi.org/10.58624/SVOANE.2023.04.085>

Received: October 24, 2022 Published: March 14, 2023

Abstract

We report the case of a 37 year old female patient who had got high-dose irradiation after subtotal removal of an ependymoma in posterior cerebral fossa. 16 years later a temporal meningioma is diagnosed and removed surgically. In this case the following meningioma fulfills the criteria for a radiation-induced tumor. There exist many reports about tumors of the central nervous system which have developed after radiotherapy in the irradiated field after a latency period. But after a thorough review of the international literature about radiation-induced tumors of the CNS is this the five cases in which a benign meningioma has followed a radiotherapy for an ependymoma.

Keywords: meningioma, radiotherapy and ependymoma of the posterior cerebral fossa.

Introduction

Radiation therapy has been widely applied for cancer treatment. Radiation, since its first application for cancers in 1889, has been a relatively well tolerated and simple, yet powerful means of tumor management. Brain tumors are not exclusive ever since the development of high energy generators such as linac and cobalt-60 unit. Although the radiation is not deleterious immediately, it may induce serious side effects such as radiation-induced necrosis, radiation-related arteriopathy or tumorigenesis apart from the beneficial effects on primary target neoplasm. Post-radiation tumor, such as fibrosarcoma of the Central Nervous System (CNS) was first reported by Mann et al. [1] and the role of radiation on tumorigenesis of the brain was documented for the first time by Modan et al. [2]

Case Report

We report a case observed in a 37 years old female who received radiotherapy at the age of 20 years for Ependymoma of the posterior cerebral fossa (Figure 1 and 2). She consults for left hemiparesis and seizures which appear four months prior to her admission. The neurological examination reveals: Intracranial hypertension syndrome, left hemiparesis and sequellar kinetic and static cerebellar syndromes. The radiological exploration shows no recurrence of primitive tumors (ependymoma of PCF) (figure 01), but there is radiation-induced meningioma after 16 years (figure 02).

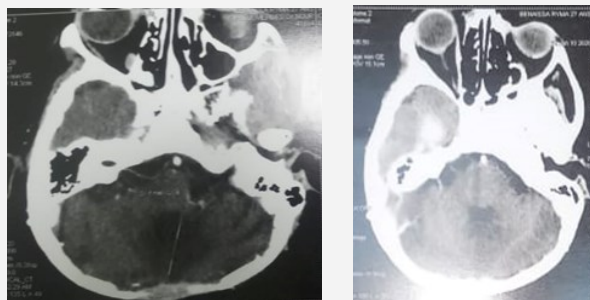
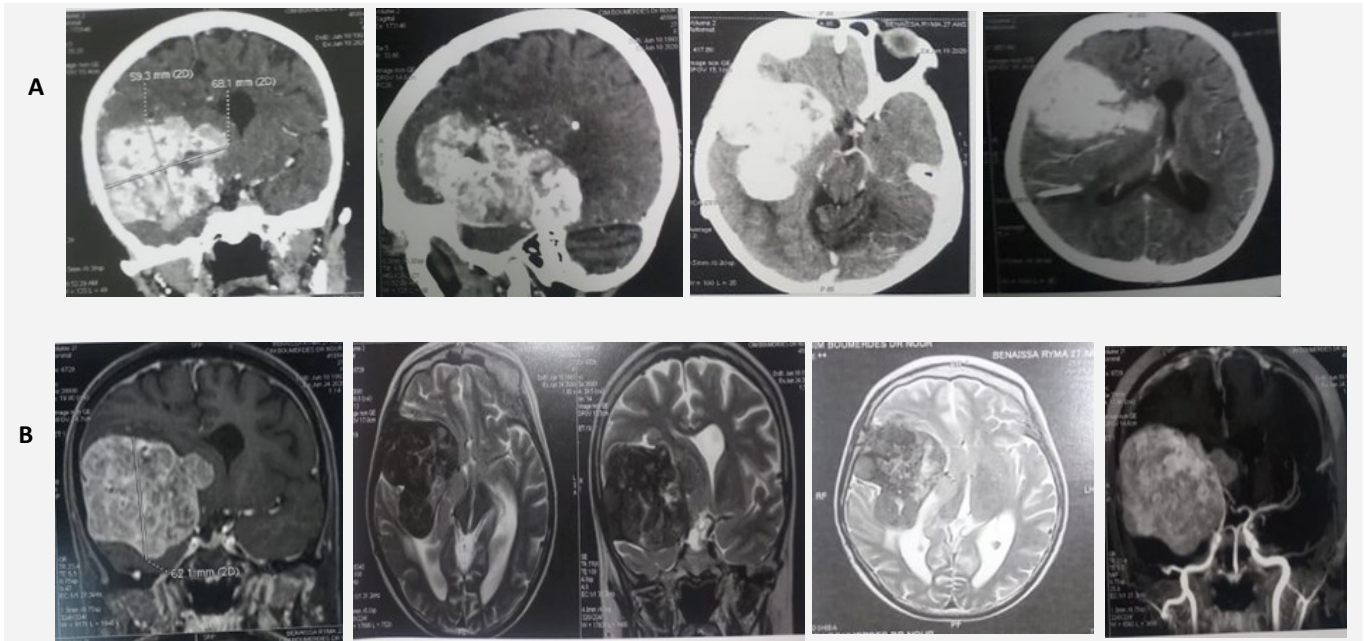


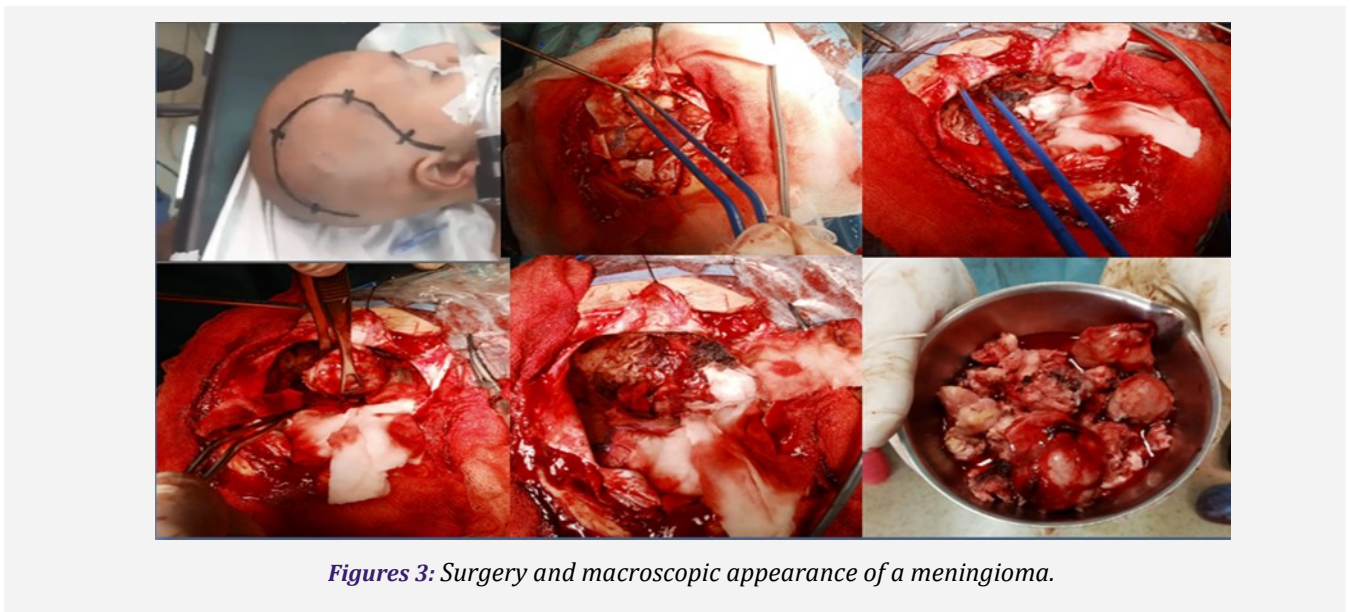
Figure 1: Cerebral CT. Scan shows no recurrence of the posterior fossa ependymoma.



Figures 2: Cerebral CT. Scan (A) and MRI (B) showed: radiation-induced temporal meningioma after 16 years.

The patient undergoes a maximalist surgery (Figure 3) confirmed in post operative Cerebral CT Scan (figure 04) and MRI (figure 05). The outcome is uneventful.

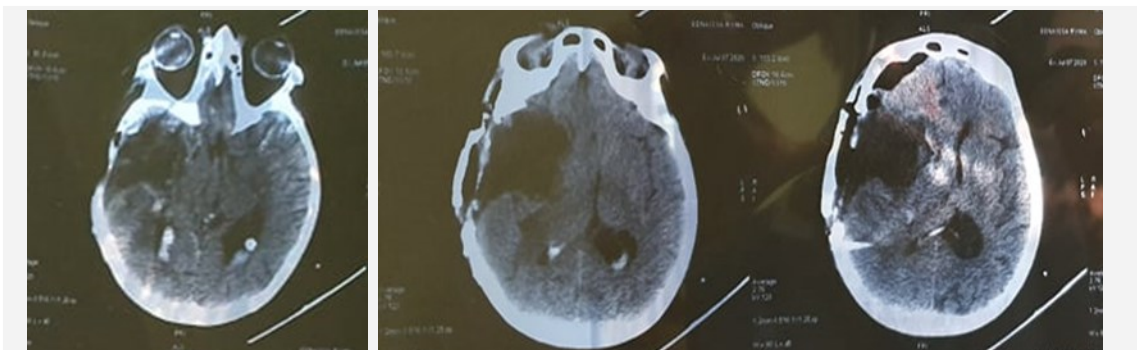
The diagnosis of Meningioma grade1 is confirmed by histopathological examination.



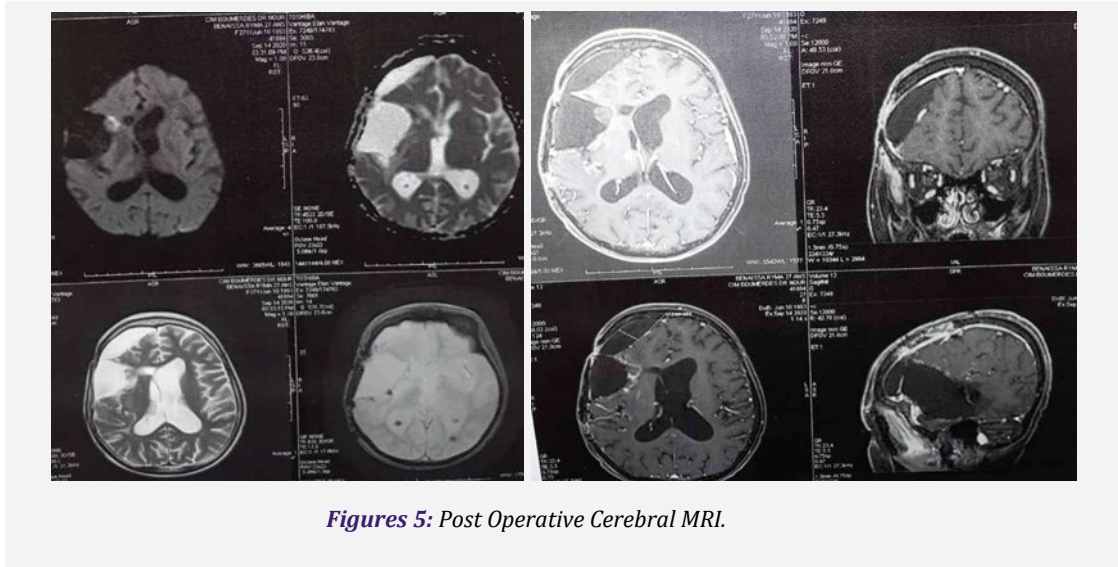
Figures 3: Surgery and macroscopic appearance of a meningioma.

Post operative status

We have noticed the persistence of the left hemiparesis, but there is not clinical status aggravation.



Figures 4: Post Operative Cerebral CT scan.



Figures 5: Post Operative Cerebral MRI.

Discussion

The first radio induced tumor was described in 1902, seven years after the discovery of x-rays. The definition of radio induced tumors is based on indirect criteria initially established by Cahan: Location in irradiated territory, after a latency period more than 5 years, with a different histological type from the irradiated tumor initially absent, and without genetic predisposition. The central nervous system is one of the sensitive tissues and there seems to be no threshold dose.

Thus, brain tumors secondary to conventional fractional radiotherapy would be linked either to low doses of benign irradiated lesions with a long follow-up (tumors of the sellar region, meningiomas). Several factors influence the incidence of these radio induced tumors, including age of exposure and individual susceptibility linked to heredity.

We describe this case firstly because of its rare histological variety and discuss its clinical, radiological, histopathological, therapeutic and prognostic characteristics with literature data [3,4]. Secondly, because of its occurrence 16 years after external radiotherapy, which could suggest the hypothesis of radio-induced meningioma.

Irradiation of cells results in an increased rate of mutagenesis, which inevitably leads to the occurrence of mutations in critical regions of the genome, which can lead to cancer. Furthermore, it seems that irradiation of the cells carrying mutations may contribute to the occurrence of a second tumor in the field of irradiation [5,6]. It must therefore be vigilant in monitoring children treated for cancer when there is a first in their family with early cancers. About clinical, para-clinical and therapeutic view, radiation-induced brain tumors are comparable to the "spontaneous" tumors [7].

Conclusion

The sensitivity of the irradiation is very different from organ to organ. We must consider the dose received by the organ, whether or not it is in the irradiation field. Radio-induced tumors following therapeutic irradiation for a first cancer are rare, it can be benign or malignant and however, this risk must be taken into consideration when developing treatment protocols especially in children and in patients with a genetic predisposition to cancer. Long-term monitoring arrangements should be established based on the foreseeable risk.

Conflict of interest

The authors declare of no conflict of interest.

References

1. Mann I, Yates PC, Ainslie JP. Unusual case of double primary orbital tumour. *Br J Ophthalmol.* 1953;37(12):758-62.
2. Modan B, Baidatz D, Mart H, Steinitz R, Levin SG. Radiation induce head and neck tumors. *Lancet.* 1974;303(7852):277-9.
3. Peraud A, Watanabe K, Schwechheimer K, Yonekawa Y, Kleihues P, Ohgaki H. Genetic profile of the giant cell glioblastoma. *Lab Invest.* 1999;79(2):123-9.
4. Neglia JP, Robison LL, Stovall M, Liu Y, Packer RJ, Hammond S, et al. New primary neoplasms of the central nervous system in survivors of childhood cancer a report from the childhood cancer survivor study. *J Natl Cancer Inst.* 2006 ;98(21):1528-37

5. Chauveinc L, Lefevre S, Malfoy B and Dutrillaux B. Département de radiothérapie, Institut Curie, 26, rue d'Ulm, 75005 Paris

6. Chauveinc L. MISE AU POINT vol /numero 4 AOUT 22/04/04. Les tumeurs solides radio-induites post-thérapeutiques. De la clinique à la biologie

7. Chantal K. Département de Pédiatrie Institut Gustave Roussy Les cancers secondaire radio -induits.

Citation: Badache K, Habchi N, Djafer M. Radio Induced Temporal Meningioma: A Rare Case Report and Literature Review. *SVOA Neurology* 2023, 4:2, 20-23.

Copyright: © 2023 All rights reserved by Badache K., et al. This is an open access article distributed under the Creative Commons Attribution License, which permits unrestricted use, distribution, and reproduction in any medium, provided the original work is properly cited.