

Alice in Wonderland Syndrome and Covid-19: A Report of Three Cases

Ana Moura Figueiredo^{1,2}, Laura Correia^{1,3}, Joana Afonso Ribeiro¹, Cristina Pereira¹ and Filipe Palavra^{1,4,5*}

¹ Center for Child Development – Neuropediatrics Unit, Hospital Pediátrico, Centro Hospitalar e Universitário de Coimbra, Coimbra, Portugal.

² Pediatrics Department, Centro Hospitalar do Médio Tejo, Torres Novas, Portugal.

³ Pediatrics Department, Centro Hospitalar do Baixo Vouga, Aveiro, Portugal.

⁴ Laboratory of Pharmacology and Experimental Therapeutics, Coimbra Institute for Clinical and Biomedical Research (iCBR), Faculty of Medicine, University of Coimbra, Coimbra, Portugal.

⁵ Clinical Academic Center of Coimbra, Coimbra, Portugal.

***Corresponding Author:** Filipe Palavra, Center for Child Development – Neuropediatrics Unit, Hospital Pediátrico, Avenida Afonso Romão, 3000-602 Coimbra, Portugal, ORCID-ID: 0000-0002-2165-130X.

DOI: <https://doi.org/10.58624/SVOANE.2023.04.087>

Received: March 20, 2023 **Published:** April 05, 2023

Abstract

Introduction: “Alice In Wonderland Syndrome” (AIWS) is characterized by episodes of distorted perceptions or temporal/spatial changes. The pathophysiological mechanism is not well defined. However, some authors argue that it is a rare perceptive disturbance, which affects mainly associative sensorial cortex integration mechanisms, involved in internal-external relationship development. It was initially described in migraine and/or epilepsy patients. Infections are considered the main cause of AIWS in children, and it can occur before, during or after the contact with the microorganism. COVID-19 is the disease caused by the SARS-CoV-2 virus, which can be linked with neurological manifestations.

Clinical case reports: Three children, between 6 and 11 years of age, previously healthy and without personal or familiar history of migraine and/or epilepsy, were observed in Neuropediatrics consultations because of visual changes, described as corresponding to macropsia, micropsia, teleopsia and pelopsia. In two of the cases, symptoms began during SARS-CoV-2 infection and, in the other one, a week after the disease. Every episode lasted a few minutes and resolved spontaneously in a few days.

Discussion: No complementary exams are needed to diagnose AIWS. Nevertheless, when paroxysmic visual changes are present, other aetiologies frequently need to be excluded. Generally, episodes are self-limited, and symptoms completely resolve, with a long-term good prognosis. Until this moment, AIWS has not been linked to COVID-19. However, in this case reports, SARS-CoV-2 was the only identified trigger. Similarly to other viruses, like EBV or H1N1, cerebral hypoperfusion by hypoxemia and/or by pro-inflammatory cytokines action in response to SARS-CoV-2 are possible underlying pathophysiological mechanisms.

Keywords: Alice in Wonderland Syndrome; Children; COVID-19

Introduction

The term “Alice in Wonderland Syndrome” was first used by the English psychiatrist John Todd in 1955.¹ This name was assigned in tribute to Lewis Carroll, author of the book “Alice in Wonderland”, in which the main character experiences drastic illusory changes of her body size, as was as size, shape and position of surrounding objects.² Although the pathophysiologic mechanism of this condition is not well defined, some authors mention that it is a rare perceptive disturbance, which affects mainly associative sensorial cortex integration mechanisms, involved in internal-external relationship development.³ It is characterized by episodic visual perception changes, namely in objects shape, size and spatial orientation and/or body image changes.^{2,3,4}

While it can occur in any age, it is more frequent in paediatric populations.³ According to some authors, this can be explained by differences between adults and children's brain structure.³ It was initially described in migraine and/or epilepsy patients^{2,4} and later associated to temporoparietal injuries, psychiatric changes, as depression or schizophrenia, and to some hallucinogenic drugs.² Recent studies suggest infectious aetiology as the main cause for AIWS, specially in children, as viruses are the most frequently associated agents. Symptoms can occur before, during or after primary infection recognition.²

In late 2019, a new coronavirus was found in Wuhan city, China, and rapidly disseminated throughout the world. In February 2020, WHO named the disease caused by this coronavirus (SARS-CoV-2) as COVID-19.⁵ This disease can affect multiple systems and, although the respiratory system is the most frequently involved, in some situations neurological features can occur.⁶

Case Summary

The first case was an 11-year-old boy, previously healthy, that was admitted to Paediatrics Emergency Room (PER) after experiencing three episodes of visual phenomena which he described as follows: "I saw peoples' heads very big and their body's very small and then the opposite way"; in one episode he described black lines and dots concurrently with the changes described. Complaints lasted about 5 minutes and then disappeared. He denied previous episodes of such manifestations, as well as personal and familiar history of epilepsy or migraine. When asked about previous infections, parents reported that their child had been infected with SARS-CoV-2 the week before the first episode. During COVID-19, the child reported having high fever, vomit, diarrhoea, and rhinorrhoea, but without any need for inpatient care. Physical exam showed no changes, namely neurological focal deficits. Afterwards, an electroencephalogram (EEG) and magnetic resonance imaging (MRI) were performed that also showed no changes. Episodes spontaneously disappeared after a week, and a final diagnosis was established as AIWS associated with SARS-CoV-2 infection.

The second case was a 7-year-old boy, previously healthy, that was admitted to PER with visual changes and the complaints were described as follows: "I see people from far away" and "people get their hands very big" (Fig. 1); his mother said that although he showed some fear and got frightened, there was no signs of associated depersonalisation: "It lasted a few minutes, he got scared, we [the parents] stayed with him for about 15 minutes to calm him down and it went away". Symptoms usually started 20-30 minutes after falling asleep. In the initial episodes he also complained of transitory fleeting headaches located to the temporoparietal region. He denied previous similar episodes, as well as personal and familiar history of epilepsy or migraine. Physical exam showed no changes, namely neurological focal deficits. When asked about previous infections, the mother reported that symptoms beginning coincided with the diagnosis of SARS-CoV-2 infection. After PER discharge, complaints slowly improved. After 10 days, episodes completely disappeared, and he never had any similar complaints. An EEG was later performed, which did not show any specific paroxysmal activity, therefore establishing AIWS associated with SARS-CoV-2 infection as the final diagnosis.

The third case was a 6-year-old boy, previously healthy, that went to a private medical office appointment with perceptive visual changes that initiated during SARS-CoV-2 infection, lasted a few minutes, and that were described as follows: "I saw things that were far away and then came closer" and "I saw people's heads small" (Fig. 2). No history of any similar event in the past has been identified. He had been previously checked in an Ophthalmology appointment, without changes. He denied personal and familiar history of epilepsy or migraine. He was not submitted to any complementary exams and AIWS associated with SARS-CoV-2 infection diagnosis was established. In several clinical follow-up consultations, no similar complaints were mentioned again.

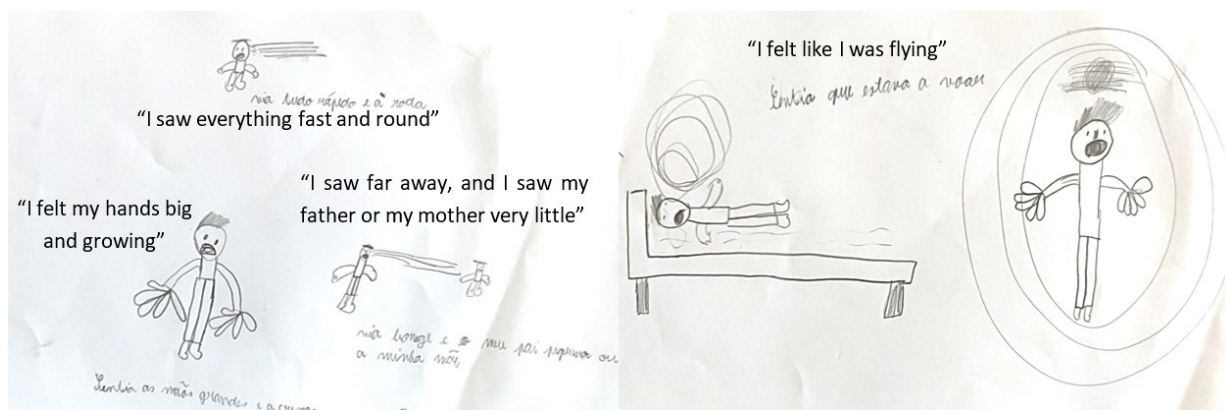

Figure 1: Clinical case 2: representation in drawing of visual complaints.

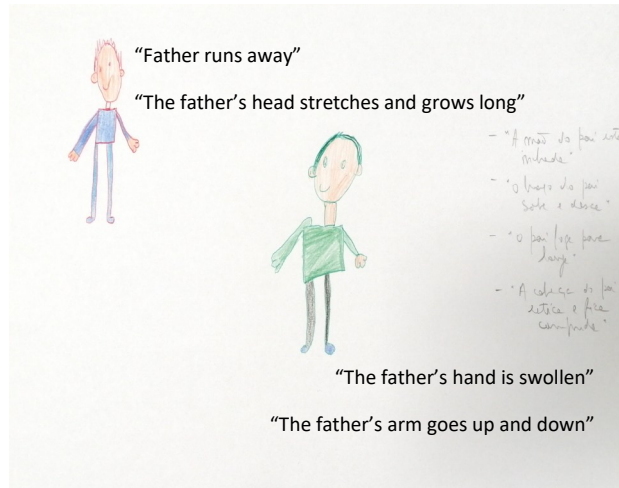


Figure 2: Clinical case 3: representation in drawing of visual complaints.

Discussion

AIWS is an entity first described more than 50 years ago, although it remains, mostly, an enigma.² Its prevalence is still unknown, namely due of the absence of large-scale studies.³ Infection is the most frequent trigger reported in paediatric age, followed by migraine and epilepsy.² Viruses are the most frequently reported infectious agents, however, other agents like bacteria or fungi may be in the origin of AIWS.³ The most common is Epstein-Barr Virus (EBV), but other viruses such as H1N1, Citomegalovirus, Coxsackie and Varicella-Zoster may be involved.^{2,3,7}

Although the pathophysiological mechanisms are still not well established³, some of the proposed ones, promoted by infectious agents, are: cerebral hypoperfusion and ischemia; autoimmunity mediated by molecular mimicry; increased blood-brain barrier permeability influenced by pro-inflammatory cytokines; direct cytopathic neuronal injury; degenerative changes leading to synaptic alterations, brain inflammation and neuronal death due to accumulation of protein aggregates.²

More than 60 different symptoms are described in AIWS,⁸ the most frequent being shape (distortions), size (macropsia and micropsia), distance perception (teleopsia and pelopsia) or movement changes.^{2,3,8} Auditory symptoms may also be present, as hallucinations or sound distorted perceptions.⁹ Patients are usually aware that these perceptions are not real, unlike in psychiatric conditions as psychosis.² Episodes duration is short, varying between 5 and 30 minutes. In most cases, they are self-limiting and symptoms fully resolve,⁹ with long-term good prognosis.²

To diagnose AIWS there is no need for complementary exams.² Nevertheless, the presence of paroxysmal visual changes need the exclusion of other diagnostic hypotheses, such as epilepsy or migraine. Epilepsy, in particular when involving occipital focal seizures, is characterized by the occurrence of focal events of non-motor and sensorial nature, that, if assigned to a focus that is located at the primary visual cortex, result in positive (typically multicolour shapes like circles or flashes) or negative visual phenomena (visual field defects or blindness).¹⁰ Episodes are usually brief, during less than 2 minutes.¹⁰ Visual aura is the most common type of aura associated with migraine and frequently presents as a fortification spectrum (a zigzag-shaped figure that arises near the fixation point, can sprawl right or left and create a lateral convexity with angulated sparkling edges, leaving absolute or variable degrees of a relative scotoma in its path), and photopsies.¹¹ Episodes usually last 5-15 minutes up to 1 hour and, typically, the aura disappears as the headache begins.¹¹

COVID-19 was described for the first time at the end of 2019, and it rapidly disseminated around the world, breaking into our daily life. This disease can affect multiple organic systems.⁵ Although the respiratory system is the most frequently involved, in some situations neurological disturbances can be present. In paediatric age, symptoms as myalgia, headache, acute encephalopathy, convulsion and asthenia are frequently described.⁶ We did not identify any other cases in the literature where the occurrence of AIWS was described in relation to SARS-CoV-2 infection. Even so, in our 3 patients, no other relationship with any other infectious agent was identified, so it seems very likely that there is a link (even in terms of time) between the visual symptoms and the aforementioned viral infection. Some potential pathophysiological mechanisms may justify these disturbances, e.g., neurologic injury caused by hypoxemia and systemic dysfunction, pro-inflammatory status, and eventual direct viral invasion of the nervous system.⁶ However, this is a situation that naturally needs further investigation.

Conclusion

Paroxysmal phenomena description in paediatric age can be challenging, consequently leading to the prescription of complementary exams, unnecessary to the diagnosis of AIWS. These 3 cases reveal the possible link between SARS-CoV-2 infection and the diagnosis of AIWS, which is based exclusively on the clinical description of perceived visual changes.

Conflict of interest

The authors declare no conflicts of interest.

Acknowledgements

A special recognition to every parent and child involved in the cases, for their availability.

References

1. J T. Alice in Wonderland. *Can Med Assoc J.* 1995;73(1):701-704.
2. Perez-Garcia L, Pacheco O, Delgado-Noguera L, Motezuma JPM, Sordillo EM, Paniz Mondolfi AE. Infectious causes of Alice in Wonderland syndrome. *J Neurovirol.* 2021;27(4):550-556. doi:10.1007/s13365-021-00988-8
3. Matria G, Mancini V, Viganò A, Di Piero V. Alice in Wonderland Syndrome: A Clinical and Pathophysiological Review. *Biomed Res Int.* 2016;2016. doi:10.1155/2016/8243145
4. Gómez-Sánchez D, Ros-Cervera G, Pérez-Verdú J, Pelechano-Ribes F, Orta-Sibú N, Saquí Canet JM. Aura sin migraña o síndrome de Alicia en el País de las Maravillas. Caso clínico pediátrico. *Arch Argent Pediatr.* 2019;117(1):e34-e36.
5. Mcintosh AK. COVID-19 : Epidemiology , virology , and prevention. UpToDate. Published online 2022:1-28. [Access in july 2022]
6. Deville JG, Song E, Ouellette CP. COVID-19: Clinical manifestations and diagnosis in children. *Up to Date.* Published online 2021:1. [Access in july 2022]
7. Hossain MM. Alice in Wonderland syndrome (AIWS): a research overview. *AIMS Neurosci.* 2020;7(4):389-400. doi:10.3934/Neuroscience.2020024
8. Blom JD, Nanuashvili N, Waters F. Time Distortions: A Systematic Review of Cases Characteristic of Alice in Wonderland Syndrome. *Front Psychiatry.* 2021;12(May):1-16. doi:10.3389/fpsy.2021.668633
9. O'Toole P, Modestino EJ. Alice in Wonderland Syndrome: A real life version of Lewis Carroll's novel. *Brain Dev.* 2017;39(6):470-474. doi:10.1016/j.braindev.2017.01.004
10. <https://www.epilepsygianosis.org/> [Consulted in march 2022]
11. Pereira Monteiro JM, Barros J, Esperança P, Fernandes G, Gil-Gouveia R, Luzeiro I, et al. International Classification of Headache Disorders - Portuguese Translation of the 3rd Edition. *Sinapse.* 2018; 18 (Suppl. 2): 1-171.

Citation: Figueiredo AM, Correia L, Ribeiro JA, Pereira C, Palavra F. Alice in Wonderland Syndrome and Covid-19: A Report of Three Cases. *SVOA Neurology* 2023, 4:2, 29-32.

Copyright: © 2023 All rights reserved by Palavra F., et al. This is an open access article distributed under the Creative Commons Attribution License, which permits unrestricted use, distribution, and reproduction in any medium, provided the original work is properly cited.