

Intracerebral Neuroblastoma in a Pediatric Patient with One Year of Life

Anabel Borrero Fernandez¹, Ana Lidia Ford Torralba², Damian Lastra Copello^{3*} and Yohana Camejo Sanchez⁴

¹ First Degree Specialist in Imaging and Comprehensive General Medicine Instructor, Master in Diagnostic Media, Assistant teacher, Havana, Cuba. ORCID:0000-0003-3935-8408

² First degree specialist in Imaging and Comprehensive General Medicine, Instructor, Havana, Cuba. ORCID:0000-0002-4836-6824

³ First Degree Specialist in Neurosurgery, Diploma in Critical and Emergency Care, Havana, Cuba. ORCID: 0000-0002-9393-1933.

⁴ First Degree Specialist in Neurosurgery, Specialist in Comprehensive General Medicine, Diploma in Critical and Emergency Care, Havana, Cuba. ORCID: 0000-0002-9393-1933.

***Corresponding Author:** Damian Lastra Copello, First Degree Specialist in Neurosurgery, Diploma in Critical and Emergency Care, Havana, Cuba. ORCID: 0000-0002-9393-1933.

DOI: <https://doi.org/10.58624/SVOANE.2023.04.089>

Received: April 03, 2023 **Published:** May 02, 2023

Abstract

The case of a 13-month-old infant who was assisted at the Neurosurgery Service of the Antonio Maria Baguez Cesar South Children's Hospital in Santiago de Cuba, referred from the oncology service of the aforementioned institution for presenting proptosis, exophthalmos of the right eye, is described. and increased head circumference. After carrying out the clinical examination and the pertinent complementary studies, including magnetic resonance imaging of the simple and contrasted skull; Histopathological study, aspiration and bilateral bone marrow biopsy concluded that we are in the presence of parameningeal neuroblastoma with medullary infiltration (stage IV) without evidence of a primary tumor. Satisfactory post-treatment chemotherapy evolution.

Keywords: neuroblastoma; burr hole; small round blue cell tumor of childhood.

Introduction

Neuroblastoma (NB) is the most common extracranial solid tumor in children, with 90% of cases being diagnosed in children under 5 years of age. It is a complex and heterogeneous disease where various factors such as: age at diagnosis, stage, location of the primary tumor and its histological and molecular characteristics, determine the prognosis and condition the treatment. ⁽¹⁾

It originates from the neural crest, during embryogenesis, and can appear at any of the anatomical sites along the sympathetic ganglionic chain, from the neck to the pelvis, as well as in the adrenal gland. It represents 7% of pediatric cancers and is the cause of 15% of all deaths from oncological processes in childhood ⁽²⁾

It ranks fourth in frequency of all childhood neoplasms after leukemias, central nervous system tumors, and lymphomas. ^{(1),(3),(4)} It presents an annual incidence in Spain of 13 cases per 106 children. Among 1,100 new cases of cancer diagnosed annually in this country in children under 15 years of age, approximately 95-100 are neuroblastic tumors. ⁽³⁾

It presents a wide spectrum of behavior, since it is the neoplasm in which more cases of spontaneous regression and differentiation into a benign tumor have been demonstrated, while in some children with metastatic forms it can cause death. ⁽²⁾ Neuroblastoma is a very fast-growing tumor, it spreads through hematogenous and lymphatic routes.

Approximately 70% of patients with neuroblastoma present with metastatic disease at the time of diagnosis. ⁽⁵⁾

It is responsible for 12-15% of cancer mortality in the pediatric age, with an overall survival at 5 years of 70-80% and only 50% in high-risk disseminated forms. ⁽¹⁾

In Cuba, at the end of 2017, the specific rate for patients between 1 and 4 years old was 56.5 per 100,000 inhabitants and for patients between 5 and 9 years old it was 10.0 per 100,000 inhabitants for age. ⁽⁶⁾

Clinical Case

The case of a 13-month-old patient, born by physiological delivery, at term, normal birth weight at birth, is presented. No prenatal, perinatal, or postnatal history; with normal psychomotor development; he was received at the Neurosurgery Service of the Antonio Maria Baguez Cesar South Children's Hospital in Santiago de Cuba, with an increase in the cranial perimeter; proptosis and exophthalmos at the level of the right eye.

Positive data on physical examination

- Increase in craniometry 4cm above normal limit.
- Exophthalmos
- Proptosis
- Paresis of the 6th cranial nerve in the right eyeball.
- Glasgow Scale for Coma modified for pediatric patients 15/15 points.

Complementary exams:

- Complete blood count. Hemoglobin: 110 g/L; hematocrit: 30; leukocytes: $3.8 \times 10^9/L$; platelet count: $216 \times 10^9/L$
- Erythrocyte sedimentation rate: 31mm/min
- Bleeding time: 1½ minutes
- Blood group and Rh factor: O+
- Clotting time: 8 minutes
- Urine catecholamines: vanilylmandelic acid (VMA); homovanillic acid (HA) and total catecholamines: normal value.

Imaging studies

Magnetic resonance imaging of the simple skull: an extra-axial image of the right hemispheric polylobulated contours is observed, isointense on T1 sequence, with hyperintense areas due to areas of early subacute bleeding, and slightly hyperintense on T2 and FLAIR sequences. Associated with changes in signal intensity at the level of the adjacent bone structure and the greater wing of the sphenoid on this side. Thickening of ipsilateral subgaleal tissue. Producing compression of the adjacent brain tissue and the lateral ventricles; displacing the midline structures 10 mm towards the contralateral side. Signs of intracranial hypertension and diffuse cerebral edema

As it grows, it penetrates the right orbit towards the extraconal fatty tissue, compresses and infiltrates the lateral rectus muscle, causing proptosis, encompasses and infiltrates the rectus, oblique and elevator palpebrae muscles. **(Fig. 1)**

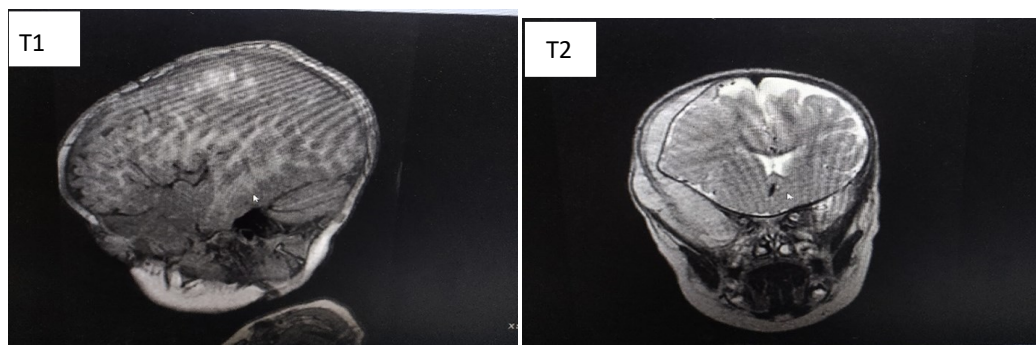


Fig1:T1 and T2 coronal slice simple scanning MRI.

Contrasted magnetic resonance imaging of the skull description

Intense uptake of the gadolinium contrast by the tumor is observed, except for the areas of intratumoral bleeding (Fig. 2).

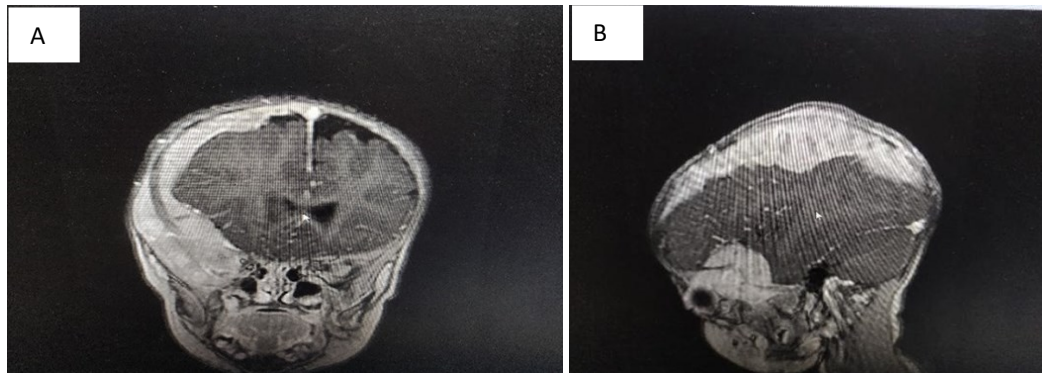


Fig 2: A: MRI of the skull contrasted coronal slice B: MRI contrasted sagittal slice.

Other extension studies carried out:

- Abdominal ultrasound: no changes
- Chest X-ray: no abnormalities
- Bone survey: no alterations

Obtaining tissue for biopsy

Diagnostic-therapeutic procedures such as bone marrow aspiration biopsy and sampling of the intracranial lesion were performed through the right parietal Burr Hole, observing severe metastatic infiltration of cells with histological characteristics typical of Neuroblastoma in a microscopic study.

Biopsy result: tissue infiltrated by small round blue cell tumor of childhood. Neuroblastoma.

Treatment

With the histological diagnosis of INSS stage IV Intracranial Neuroblastoma (bone marrow metastasis) and absence of primary tumor), it was decided to perform polychemotherapy; P6 scheme consisting of 7 cycles every 28 days without complications.

Achieving a Satisfactory Evolution after treatment.

Discussions

Neuroblastomas arise from the precursor stem cells of the sympathetic-adrenal nervous system of the neural crest. Its etiology is unknown. The association with syndromic pictures is much less frequent than in Wilms tumor. There is an autosomal dominant familial form described in 1% of cases. (7)

Neuroblastoma can have a very early onset in intrauterine life, adrenal tumors have been found in situ during autopsies of preterm fetuses and infants. The symptoms associated with the tumor vary depending on age, the origin of the tumor and the presence of metastases. Most NB are diagnosed in children under one year of age, and 65% originate in the adrenal gland. The second most frequent site of occurrence is the Zuckerland organ in the pelvis, near the aortic bifurcation. With respect to the extra-abdominal locations, the thoracic and the cervical, are the most frequent after the abdominal. In 1% of the NB the primary tumor is not located, as in our case. The symptoms, of course, will depend on the location and size of the tumor. (8)

It manifests as a hard and fixed asymptomatic tumor mass along the sympathetic pathways, more frequently in the abdomen. Skin and soft tissue injuries can be confused with trauma injuries and child abuse. Thoracic neuroblastoma is usually a radiographic finding. In the pelvis it can produce bladder or intestinal alterations due to compression of organs by the mass. Intestinal obstruction is rare. In 60-65% of cases there is metastatic disease at diagnosis, presenting weight loss, anorexia, compromised general condition and fever.

Other signs and symptoms include fatigue, irritability, lethargy, bone pain, and lymphadenopathy. Signs and symptoms of excessive catecholamine secretion may also occur, such as sweating, paleness, hypertension, failure to thrive, headache, facial flushing, palpitations, bloating, watery diarrhea, and hypokalemia. ⁽²⁾

Orbital involvement is an indicator of metastatic disease. Orbital manifestations are well known and include proptosis, periorbital ecchymosis, Horner syndrome, opsoclonus/myoclonus syndrome, ocular motility defects, ptosis, and blindness. ⁽²⁾

The most important prognostic factors are age and stage at diagnosis. Among the biological factors, the most important are the amplification of the MYCN proto-oncogene, the histopathological classification and the DNA content (ploidy). Regarding the stage, The International Neuroblastoma Staging System (INSS) is used. ⁽²⁾ The advantage of this staging system is that the patient is included in a certain risk group. This classification of patients with neuroblastoma has proven to be very useful as it allows planning the best treatment and avoids unnecessary therapies for the child. ⁽⁵⁾

In studies carried out by Meena and Gupta (2019), ⁽⁹⁾ the importance of imaging studies for the diagnosis of neuroblastoma is described, including:

AP and L chest x-ray: To look for metastases in the pleura or lung or both, taking mediastinal lymph nodes, bone lesions (osteolysis) in the chest bones, pleural or pericardial effusion.

Plain X-ray of the abdomen AP and L: radiopacity can be seen: calcifications, rejection of the intestinal loop to the opposite side.

Abdominal ultrasound: This study allows us to see its origin, its diameters, its relationship with other organs, the presence of infiltration or compression of large vessels, enlarged intra-abdominal lymph nodes, the presence of ascites or intra-abdominal metastases. In addition to this, it allows performing a fine needle aspiration biopsy (BAAF) and obtaining a sample of the lesion.

Bone survey: In this study, the presence of metastatic bone lesions is ruled out.

Computed Axial Tomography (CAT): This imaging study allows preoperative evaluation of the size and extension of the tumor, its relationship with the great vessels, the existence of intratumoral thrombi in the vena cava, presence of metastases not diagnosed with the aforementioned means. . In addition, it offers a more precise vision to plan the surgery.

Nuclear Magnetic Resonance (NMR): It is of vital importance in those specific cases, given the suspicion of intramedullary or spinal lesions caused by the tumor.

Bone scintigraphy: It is an optional study that is performed in certain patients, according to medical criteria.

NB is a tumor of small, round and blue cells, characteristics that define a group of undifferentiated neoplasms typical of the pediatric age. Neuroblastic tumors are made up of two cell types, ganglion cells, or neuroblasts, and reactive cells, called Schwann stroma. The arrangement of neuroblasts around an eosinophilic staining center is known as a Homer-Wright rosette, characteristic of the tumor. Schwann cells, in response to substances synthesized by the tumor, inhibit proliferation and induce maturation of neuroblasts. Among the histochemical markers that help diagnosis are: neuronal specific enolase (ENE), synaptophysin, GD2 ganglioside, TrK receptors, and chromogranin A. ⁽⁴⁾

Neuroblastoma treatment is performed by multidisciplinary teams, including oncologists, surgeons, pediatricians, and radiotherapists, to fully evaluate each patient and personalize treatment. It has three basic therapeutic weapons: surgery, chemotherapy and radiotherapy that are used depending on the stage of the disease, as well as an arsenal of new therapeutics that already provide encouraging results in the current treatment of neuroblastoma. ⁽²⁾

There are other therapies that have proven to be effective in the current treatment of neuroblastoma. Targeted radiotherapy with ¹³¹I-MIBG is an effective option on which there are results; also small inhibitory molecules for targeted therapies and another fundamental pillar is immunotherapy, both monoclonal antibodies and therapies with targeted NK lymphocytes. ⁽¹⁰⁾

Conclusions

1. Neuroblastomas arise from the precursor stem cells of the sympathetic-adrenal nervous system of the neural crest.
2. Orbital involvement is an indicator of metastatic disease.

3. The most important prognostic factors are age and stage at diagnosis.
4. Nuclear Magnetic Resonance (NMR): It is of vital importance in those specific cases, given the suspicion of intramedullary or spinal lesions caused by the tumor.
5. It is recommended for the treatment of patients diagnosed with neuroblastoma regardless of the involvement of the central nervous system due to the disease, to establish an evaluation by a multidisciplinary team made up of oncologists, surgeons, pediatricians and radiotherapists, with the aim of achieving a comprehensive evaluation at each patient that allows us to apply a more effective treatment.

Conflict of Interests

The authors declare that there are no conflicts of interest.

References

1. Yan P, Qi F, Bian L, Xu Y, Zhou J, Hu J, et al. Comparison of incidence and outcomes of neuroblastoma in children, adolescents, and adults in the united states: A surveillance, epidemiology, and end results (SEER) program population study. *Med Sci Monit*; 2020. p. 26
2. González Escudero R, Gómez Dermit V, López Almaraz R. Exoftalmos unilateral de corta evolución. Una forma de debut de un neuroblastoma. *Bol Pediatría*. 2016; 56:186-190
3. Cañete Nieto A, Pardo Romaguera E, Muñoz López A, Valero Poveda S, Porta Cebolla S, Barreda Reines M, et al. Cáncer infantil en España. Estadísticas 1980-2020.Registro Español de Tumores Infantiles (RETI-SEHOP). Valencia. 2021. Disponible en: <https://www.uv.es/rnti/informes.html>.
4. Park J, Hogarty M, Bagatell R, Schleiermacher G, Mosse Y, Maris JM. Neuroblastoma. In: Pizzo P, Poplack D, editors. *Principles and Practice of Pediatric Oncology*. 8th ed. Philadelphia, PA, EE.UU.: Wolters Kluwer; 2020. p. 647-72.
5. Granda Velasco KA, Solis Monserrate AA, Torres Paredes KM, Duarte Padilla MM, Guzmán González JI. Pronóstico y supervivencia en pacientes con Neuroblastoma. *Pertinencia Académica*. 2021; 5 (2)
6. Cuba. Ministerio de Salud Pública. Anuario estadístico de salud. La Habana: MINSAP; 2020
7. De Castro Almeida, D. A. R., Martínez León, D. M. I., Rodríguez Ortega, D. R., Bravo Bravo, D. C., Garcia Herrera Taillefer, D. P., & Lopez Rosa, D. A. (2021). El neuroblastoma en menores de 18 meses: importancia de la edad en el pronóstico. *Seram*, 1(1). Recuperado a partir de <https://piper.espacio-seram.com/index.php/seram/article/view/4397>
8. Barrena Delfa S, Rubio Aparicio P, Martínez Martínez L. Neuroblastoma. *Cir Pediatr*. 2018; 31: 57-65
9. Meena JP, Gupta AK. Neuroblastoma in a Developing Country: Miles to Go. *Indian journal of pediatrics*.2019; 86(5), 403– 405. <https://doi.org/10.1007/s12098-019-02930-7>
10. MacFarland S, Bagatell R. Advances in neuroblastoma therapy. *Current opinion in pediatrics*. 2019; 31(1), 14–20. <https://doi.org/10.1097/MOP.000000000000071>

Citation: Fernandez AB, Torralba ALF, Copello DL, Sanchez YC. Intracerebral Neuroblastoma in a Pediatric Patient with One Year of Life. *SVOA Neurology* 2023, 4:3, 37-41.

Copyright: © 2023 All rights reserved by Copello DL., et al. This is an open access article distributed under the Creative Commons Attribution License, which permits unrestricted use, distribution, and reproduction in any medium, provided the original work is properly cited.