

# Unilateral Primary Carotiditis: A Case Report

Luigi F Saccaro MD<sup>1\*</sup>, Beatrice Milano<sup>2</sup> and Santi Galletta MD<sup>1</sup>

<sup>1</sup> Department of Neurology, University Hospital, Geneva, Switzerland.

<sup>2</sup> Sant'Anna School of Advanced Studies, Pisa, Italy.

\*Corresponding Author: Luigi F Saccaro MD, Department of Neurology, University Hospital, Geneva, Switzerland.

DOI: <https://doi.org/10.58624/SVOANE.2023.04.098>

Received: June 12, 2023 Published: July 05, 2023

## Abstract

We report the first case of isolated unilateral carotid arteritis, following an upper respiratory tract infection in a patient without other medical conditions. We collected clinical information during the patient's hospitalization and follow-up. Through a Pubmed search, we identified articles discussing TIPIC syndrome, carotid pain, or inflammation. After reviewing the articles and the corresponding images, none of these reported clinical and radiological findings similar to ours. A 55-year-old man consulted for unilateral neck pain, without relevant clinical history apart from an upper respiratory tract infection, nor other signs or symptoms. An MRI before admission showed signs of focal adventitial inflammation of the left internal carotid artery. Ultrasound identified a mixed plaque with hypoechoic and isoechoic components at the beginning of the left internal carotid. In particular, there was no halo sign suggestive of giant cell arteritis. Extensive laboratory exams only found increased plasma IL-1 receptor antagonist. After three days of corticosteroid and acetylsalicylic acid treatment, cervicalgia completely regressed, and prednisone was stopped. The patient was discharged on day 7 on daily acetylsalicylic acid. At three months, he remained asymptomatic, carotid ultrasound was comparable to the first one, and treatment was stopped. We suggest that a purely vascular inflammation of the carotid could appropriately be defined "carotiditis", considering the focal, isolated involvement of the carotid wall, and that such a unilateral presentation has never been reported before. Speculatively, we propose an association between carotiditis and the upper respiratory tract infection in this patient.

**Keywords:** Cervicalgia; carotidynia; isolated carotid arteritis; carotiditis; upper respiratory tract infection.

## Introduction

The term arteritis indicates an artery inflammation [3,4]. Arteritides of neurovascular interest are most often intracerebral and with multifocal arterial involvement, while the literature on description and management of unifocal, extracerebral, exclusively carotid involvement is lacking. In fact, radiological and clinical findings were not compatible with carotid dissection or intra-cranial arteritis. Recently, the name "TIPIC syndrome" has been proposed to replace numerous other labels (such as "carotiditis", "carotid periarteritis", "carotidynia", "carotidodynia", "carotidobulbia") [5] that have been used to describe the same clinical syndrome, characterized by pericarotid tissue inflammation and carotidynia. Etymologically, the term "carotidynia" means "carotid pain", thus referring to a symptom rather than to a distinct clinical entity. Importantly, while TIPIC syndrome includes all etiologies underlying carotid pain and pericarotid inflammation, it does not include isolated carotid inflammation, which would be better defined in physiopathological terms as "carotiditis", i.e. Inflammation of the carotid artery. We report clinical, radiological, and laboratory findings, as well as therapeutical management of the first reported case of isolated unilateral carotid arteritis, following an upper respiratory tract infection in a patient without other medical conditions.

## Case Presentation

A 55-year-old Caucasian man consulted the ER for left unilateral neck pain and headache. He reported that the pain had begun progressively ten days before, irradiating from the neck to the left jaw and the left retro-orbital area. He did not report traumatism, nor violent sneezing, no cervical massage, no abnormal movements, no vomiting, coughing nor exertion upon defecation. The only remarkable event was an upper respiratory tract infection, three weeks before the apparition of the neck pain. He reported no neoplastic or inflammatory sign or symptom and he had no history of genetic, inflammatory, neurological, or vascular disease.

He had performed an MRI before admission that showed signs of focal adventitial inflammation of the left internal carotid artery on the T2 axial FLAIR sequence (Figure 1), no restriction of diffusion on DWI or ADC sequences, no microbleeds on the SWAN sequence, and permeability of vessels on the gadolinium-enhanced T1 MRI (not shown).

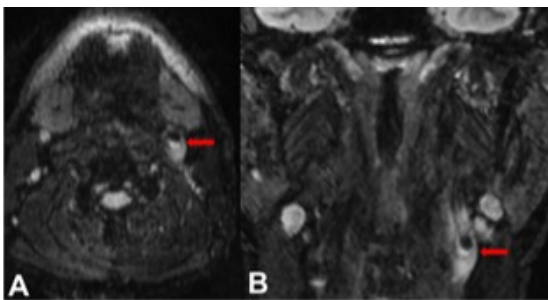
The patient was admitted to the Stroke Center of the University Hospital of Geneva for further investigations. At admission (day 0, 30 October), general and neurological clinical examinations were unremarkable, his NIHSS score was 0, without focal neurological signs nor carotid bruit upon auscultation of the neck. The only symptom was the persistence of moderate left retro-orbital headache and cervicalgia, which increased with palpation.

We performed ultrasound of the carotid and vertebral arteries that identified a mixed plaque with hypoechoic and isoechoic components, without significant stenosis at the beginning of the left internal carotid (Figure 2). In particular, there was no halo sign suggestive of giant cell arteritis. Intracranial ultrasound was unremarkable. Ophthalmologic investigations were normal, without signs of uveitis.

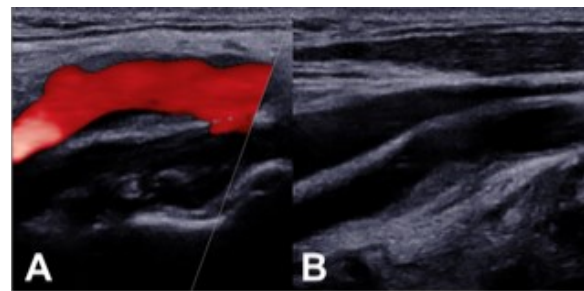
We performed extensive laboratory exams on day 1 after admission, including infective (e.g. SAR COVID-19 igg), inflammatory, metabolic, and hematological panels (infections, inflammation, metabolic), as well as a lumbar puncture. The only anomalies were a slight folate deficiency (6 nmol/L), increased IL-1 receptor antagonist (1358 pg/ml, normal range: 20-880 pg/ml), slightly elevated anti-cardiolipin antibodies (igg: 14.7 U/ml, normal range: 0-14 U/ml), and unexplained renal insufficiency (creatinine: 119 umol/L, EGFR [CKD-EPI]: 59 ml/min/1.73m<sup>2</sup>) that was not previously known.

Since he did not have fever, anemia, jaw claudication, visual disturbances, nor constitutional signs or symptoms, there was no indication to performing an arterial biopsy.

We started a therapy with acetylsalicylic acid 100mg/die, and prednisone 0.6mg/kg (50mg/die) as empiric treatment. On day 3, the cervicalgia completely regressed and prednisone was stopped, to avoid unnecessary immunosuppressive risk. On day 7, the patient was discharged on daily acetylsalicylic acid.



**Figure 1: Carotid adventitial inflammation.**  
A, axial and B, coronal cervical MRI show hyperintense left carotid signal (red arrows) suggestive of carotid adventitial inflammation sparing the pericarotid tissue.



**Figure 2: Atheromatous plaque of the left internal carotid artery.** A, ultrasound of the left internal carotid artery showing a mixed atheromatous plaque. B, Doppler ultrasound of the left internal carotid artery showing no evidence of hemodynamically significant stenosis.

## Discussion

We presented the case of an adult man with isolated carotid arteritis revealed by neck pain.

The differential diagnosis of pain and inflammation in the carotid region includes transient perivascular inflammation of the carotid artery (TIPIC) syndrome, also known as Fay syndrome [1], dissection, aneurysm, systemic vasculitis, infective and neoplastic etiologies.

Our patient did not meet the criteria for any inflammatory diseases, especially for vasculitis, such as giant cell arteritis, Takayasu's arteritis, granulomatosis with polyangiitis, poly-arteritis nodosa and Churg-Strauss variant, or Bechet's disease. Tuberculosis or fungal infections have been reported as possible causes of carotid inflammation [2], but the patient did not have any signs of active infections.

To the best of our knowledge, this is the first reported case of isolated unilateral carotid arteritis. Other cases of benign isolated arteritis of the CNS have been reported [3,4]. However, these describe an intracerebral and multifocal arterial involvement, contrary to our case, in which unifocal, extracerebral, exclusively carotid involvement was found. In fact, radiological and clinical findings were not compatible with carotid dissection or intra-cranial arteritis. In particular, there were no signs of pericarotid fatty tissue inflammation, excluding the diagnosis of TIPIC syndrome [1]. As mentioned in the Introduction, while TIPIC syndrome includes all etiologies underlying carotid pain and pericarotid inflammation [5], it does not include isolated carotid inflammation (as the case of our patient), which would be better defined in physiopathological terms as "carotiditis", i.e. Inflammation of the carotid artery.

Through a Pubmed search for the keywords "(carotid AND (carotiditis OR carotid periarthritis OR carotidynia OR carotidodynia)) AND (unilateral AND carotid AND (inflammation OR arteritis))" we identified 245 articles discussing TIPIC syndrome, carotid pain or inflammation. After reviewing the articles and the corresponding images, none of these reported clinical and radiological findings similar to ours. Thus, we suggest that a purely vascular inflammation of the carotid could appropriately be defined "carotiditis", considering the focal, isolated involvement of the carotid wall, and that such a unilateral presentation has never been reported before.

In this case, the only relevant findings were increased IL-1 receptor antagonist, slightly elevated anti-cardiolipin antibodies, and the clinical history of a respiratory infection one month before the symptoms. IL-1Ra has been associated with atherosclerosis [6] and, in general, it may constitute a compensatory anti-inflammatory response to arteritis-dependent inflammation. On the other hand, elevated anti-cardiolipin antibodies are likely reactive to endothelial lesions due to arteritis [7]. An autoimmune etiology has been proposed for bilateral internal carotid arteritis [8] but, in our case, the purely unilateral carotid involvement may suggest other underlying mechanisms. Although speculatively, we propose an association between the present clinical presentation and the upper respiratory tract infection reported by the patient, either through molecular mimicry or through other mechanisms.

## Conclusion

To conclude, this case demonstrates that not always inflammatory carotid pain is attributable to TIPIC syndrome or other well-characterized diseases. Carotiditis, defined as an isolated, unilateral, focal inflammation of a carotid artery, may be a new clinical identity with different clinical course and implications than TIPIC syndrome. Differentiating the etiologies of carotid pain is of the utmost importance to study the most appropriate treatment for the underlying condition, which may be associated with increased risk of serious events such as stroke or dissection.

## Author Contributions

LFS and SG designed the manuscript; LFS drafted the manuscript; BM edited the manuscript; SG critically reviewed the manuscript.

## Acknowledgments

None.

## Supplementary Material

None.

## Disclosure

The authors report no disclosures relevant to the manuscript.

## Conflict of Interest Statement

The authors report no conflict of interest.

## Funding

None.

## Patient Consent

Written informed consent was obtained from the patient for publication of this case report and any accompanying images.

## Statement of Ethics

This paper complies with internationally accepted standards for research practice and reporting. No ethical from an ethical review board approval was obtained as no research intervention was carried out.

## References

1. Santarosa C, Stefanelli S, Sztajzel R, Mundada P, Becker M. Carotidynia: A Rare Diagnosis for Unilateral Neck Pain Revealed by Cross-Sectional Imaging. *Case Rep Radiol.* 2017;2017:1–4.
2. Little JS, Cheng MP, Hsu L, Eduardo Corrales C, Marty FM. Invasive Fungal Carotiditis: A Rare Manifestation of Cranial Invasive Fungal Disease: Case Series and Systematic Review of the Literature. *Open Forum Infect Dis.* 2019;6:1–8.
3. Van Calenbergh F, van den Bergh V, Wilms G. Benign isolated arteritis of the central nervous system. *Clin Neurol Neurosurg.* 1986;88:267–73.
4. Bettoni L, Juvarrá G, Bortone E, Lechi A. Isolated benign cerebral vasculitis. Case report and review. *Acta Neurol Belg. Italy;* 1984;84:161–73.
5. Lecler A, Obadia M, Savatovsky J, Picard H, Charbonneau F, Menjot De Champfleury N, et al. TIPIC syndrome: Beyond the myth of carotidynia, a new distinct unclassified entity. *Am J Neuroradiol.* 2017;38:1391–8.
6. Gottsäter A, Forsblad J, Mätzsch T, Persson K, Ljungcrantz I, Ohlsson K, et al. Interleukin-1 receptor antagonist is detectable in human carotid artery plaques and is related to triglyceride levels and chlamydia pneumoniae iga antibodies. *J Intern Med.* 2002;251:61–8.
7. Liozon E, Roblot P, Paire D, Loustaud V, Liozon F, Vidal E, et al. Anticardiolipin antibody levels predict flares and relapses in patients with giant-cell (temporal) arteritis. A longitudinal study of 58 biopsy-proven cases. *Rheumatology.* 2000;39:1089–94.
8. Fukuma K, Kowa H, Nakayasu H, Nakashima K. Atypical arteritis in internal carotid arteries: A novel concept of isolated internal carotid arteritis. *Yonago Acta Med.* 2016;59:248–54.

**Citation:** Saccaro LF, Milano B, Galletta S. Unilateral Primary Carotiditis: A Case Report. *SVOA Neurology* 2023, 4:4, 94-97.

**Copyright:** © 2023 All rights reserved by Saccaro LF., et al. This is an open access article distributed under the Creative Commons Attribution License, which permits unrestricted use, distribution, and reproduction in any medium, provided the original work is properly cited.