

Contralateral Hyperhidrosis After Large Acute Left MCA Territory Infarction: A Case Report

Ibrahim KALEEL¹, Ayoub HAMBLI¹ and Abdel Salam KALEEL^{1*}

¹ Department of Neurology, Grand River Hospital, McMaster University/Michael De Groot School of Medicine, Kitchener/Waterloo, Ontario, Canada.

***Corresponding Author:** Abdel Salam Kaleel, Department of Neurology, Grand River Hospital, McMaster University/Michael De Groot School of Medicine, Kitchener/Waterloo, Ontario, Canada.

DOI: <https://doi.org/10.58624/SVOANE.2024.05.0143>

Received: July 01, 2024 **Published:** July 11, 2024

Abstract

A 51-year-old female presented with sudden onset of right-sided hemiparesis and aphasia. Imaging confirmed a left middle cerebral artery (MCA) territory infarct affecting the insular cortex. During her recovery, she developed excessive sweating exclusively on the right side of her body, leading to a diagnosis of contralateral hyperhidrosis. This case highlights the unusual presentation of hyperhidrosis following an MCA stroke and underscores the role of the insular cortex in autonomic regulation.

Keywords: Hyperhidrosis; Stroke; Insular cortex

Introduction

Stroke is a major cause of disability and death, often leading to serious neurological deficits. Middle cerebral artery (MCA) strokes vary in their presentation given the large cerebral territory, but may produce degrees of motor and/or sensory deficits contralateral to the lesion in addition to aphasia, visual deficits, neglect, and gaze preference based on the location and size. However, autonomic nervous system symptoms, like hyperhidrosis, are not often reported after MCA territory strokes.

This case report describes a 51-year-old female who developed contralateral hyperhidrosis following an MCA infarct. This unusual manifestation provides insight into the complex role of the insular cortex, a region of the brain located deep within the lateral sulcus between the frontal and temporal lobes, in autonomic regulation and highlights the need for awareness of such presentations in stroke patients. (1-5)

Case Presentation

A 51-year-old right-handed female with a history of hypertension and hyperlipidemia presented to the emergency department with sudden onset of right-sided weakness and aphasia. On examination, she was alert but exhibited expressive aphasia, right facial droop, and right hemiparesis. Her National Institutes of Health Stroke Scale (NIHSS) score was 14.

Investigations

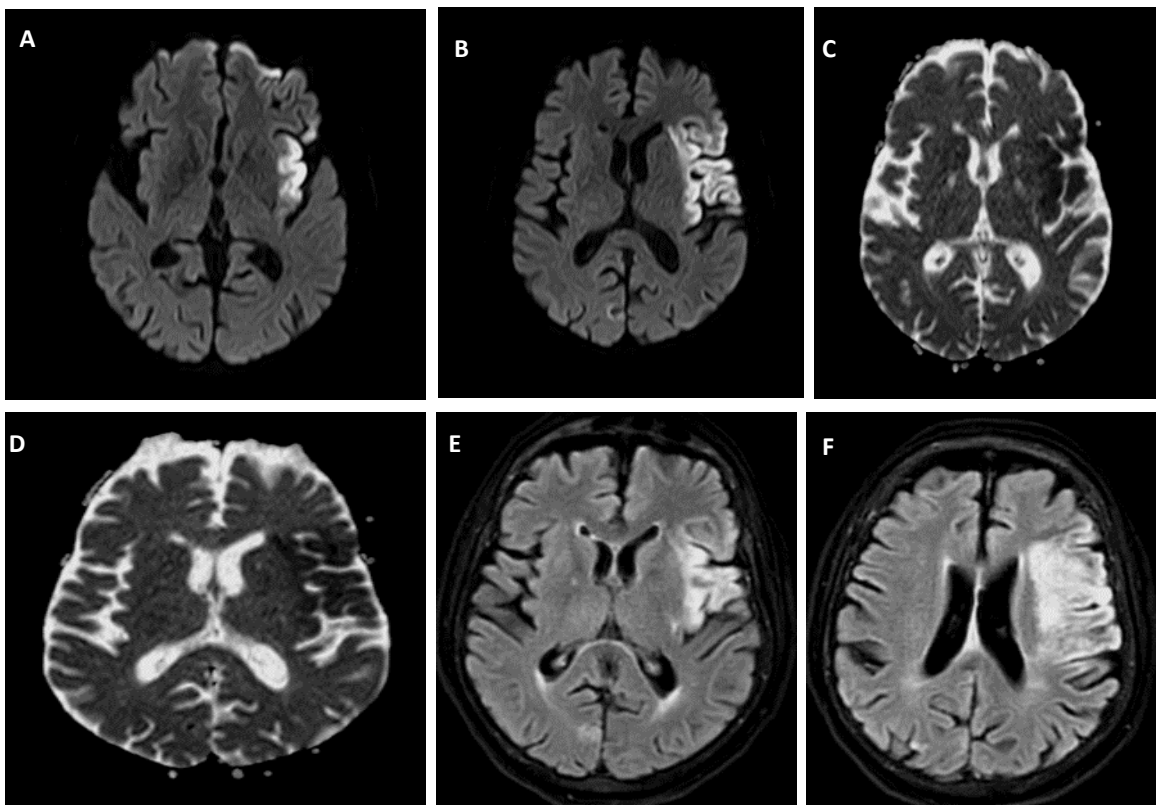
A non-contrast computed tomography (CT) scan of the head revealed an acute ischemic stroke in the left MCA territory. Magnetic resonance imaging (MRI) confirmed an infarct involving the left insular cortex. The patient was treated with intravenous thrombolysis and admitted to the stroke unit for further management.

Clinical Course

During her hospital stay, the patient showed gradual improvement in her motor functions and speech. However, on the fourth day post-stroke, she began to experience excessive sweating on the right side of her body, particularly affecting the face, arm, and upper trunk. This sweating was not associated with physical activity or ambient temperature changes and was markedly asymmetrical compared to the left side of her body.

Diagnosis

Given the timing and unilateral nature of the hyperhidrosis, a diagnosis of contralateral hyperhidrosis secondary to the left MCA stroke affecting the insular cortex was made. Other potential causes, such as hyperthyroidism/other endocrinological disorders, medication side effects, and infections, were ruled out through appropriate investigations. Her workup revealed atrial fibrillation following a two week cardiac holter monitor and she was treated with rivaroxaban. Her hyperhidrosis resolved spontaneously after four weeks without treatment.



Figures 1 (A-F): The MRI of the brain sequences (DWI, ADC map, and FLAIR sequences, respectively) demonstrate a large hyperintensity along the left MCA territory, including the left insular cortex.

Discussion

Hyperhidrosis, or excessive sweating, is a condition typically associated with excessive sympathetic activity and autonomic dysregulation, but its presentation following a stroke is relatively uncommon. In this case, a 51-year-old female patient developed contralateral hyperhidrosis affecting her right hemi-body after experiencing a left MCA stroke. This phenomenon can likely be attributed to the infarction involving the insular cortex, an area known to play a crucial role in autonomic regulation. (2)

The insular cortex is felt to affect autonomic functions via its projections to brainstem nuclei that control autonomic functions, including the nucleus of the solitary tract (NTS), which is involved in cardiovascular and respiratory regulation. (3) The insular cortex also communicates with other brain regions involved in autonomic control, including the hypothalamus, the amygdala, and the prefrontal cortex. Several studies have highlighted the role of the insular cortex in cardiovascular regulation, thermoregulation, and sweat production. (4) Disruption to this area may lead to abnormal sympathetic activity, resulting in hyperhidrosis.

Hyperhidrosis following stroke may resolve spontaneously. If treatment is needed, options are limited. Current management of hyperhidrosis may include antiperspirants as well as anticholinergics. By reducing the stimulation of sweat glands, anticholinergics can decrease sweat production though the potential risk of cognitive impairment/encephalopathy or cardiovascular risks may outweigh the benefits in the setting of acute ischemic stroke. Botulinum toxin injections, while often used successfully in many cases of hyperhidrosis, may also have limited utility in this setting given the broad distribution of hyperhidrosis and the high dosing required.

Conclusions

Hyperhidrosis following a left middle cerebral artery (MCA) stroke is a rare but significant complication that can lead to considerable discomfort and impact quality of life. Various management strategies, including anticholinergic medications and botulinum toxin injections, may be considered, but their efficacy and safety in this specific context are not well established. (5) Further studies may be useful to determine the optimal treatment approach for this uncommon condition.

Conflict of Interest

The authors declare that there is no conflict of interest.

References

1. Kumar P, Clark ML. Clinical Medicine. 9th edition. Edinburgh: Saunders Elsevier; 2017. Chapter 8, Stroke and transient ischaemic attacks. Available from: <https://www.ncbi.nlm.nih.gov/books/NBK459348/>
2. Oppenheimer SM, Gelb A, Girvin JP, Hachinski VC. Cardiovascular effects of human insular cortex stimulation. *Neurology*. 1992; 42(9):1727-1732. doi:10.1212/WNL.42.9.1727
3. Hassan KM, Joshi KC, Khurshid Z, Ahmed B, Shabbir J. The insular cortex: a review. *Malays J Med Sci*. 2019; 26(1):6-16. doi:10.21315/mjms2019.26.1.2
4. Benarroch EE. The central autonomic network: functional organization, dysfunction, and perspective. *Mayo Clin Proc*. 1993; 68(10):988-1001. doi:10.1016/s0025-6196(12)60585-0
5. Kuruvilla A, Bhattacharya P. Hyperhidrosis: anatomy, pathophysiology and treatment with emphasis on the role of botulinum toxins. *Toxins (Basel)*. 2016; 8(2):36. doi:10.3390/toxins8020036

Citation: Kaleel I, Hambli A, Kaleel AS. Contralateral Hyperhidrosis After Large Acute Left MCA Territory Infarction: A Case Report. *SVOA Neurology* 2024, 5:4, 154-156. doi: 10.58624/SVOANE.2024.05.0143

Copyright: © 2024 All rights reserved by Kaleel AS., et al. This is an open access article distributed under the Creative Commons Attribution License, which permits unrestricted use, distribution, and reproduction in any medium, provided the original work is properly cited.