

Literature Review on Effective Use of Modern Modalities in Management of Intra-Axial Brain Lesions

Okoro Emmanuel Uzoma^{1,2*}, Havryliv Taras^{1,2}, Aigbogun Julia³ and Smolanka Andriy^{1,2}

¹ Department of Neurosurgery, Neurology and Psychiatry, Uzhhorod National University, Ukraine.

² Municipal Non-profit Enterprise Regional Clinic, Center of Neurosurgery and Neurology, Transcarpathian Regional Council, Ukraine.

³ Department of Vascular Neurology, University of Texas Medical Branch, USA.

***Corresponding Author:** Okoro Emmanuel Uzoma, Department of Neurosurgery, Neurology and Psychiatry, Uzhhorod National University, Ukraine.

DOI: <https://doi.org/10.58624/SVOANE.2024.05.0144>

Received: June 04, 2024 **Published:** July 17, 2024

Abstract

The significant health burden caused by intra-axial brain lesions and the difficulties associated with their diagnosis and treatment have prompted a large number of researchers and practitioners to investigate various diagnostic and treatment modalities for their effectiveness and safety. This study focuses on evaluating different pre-, intra- and postoperative techniques and analyzes their advantages and limitations to ultimately improve the management of this type of brain lesion. Through a critical analysis of various scientific sources, this research aimed to synthesize existing knowledge on the topic. Magnetic resonance imaging plays a crucial role in diagnosing and managing brain tumors. Functional MRI identifies functional brain areas, but tumor-induced blood flow changes can affect its reliability. Connectome analysis provides information on functional localization and brain networks, which became possible using diffusion tensor imaging, that visualizes white matter pathways, aiding in tumor boundary delineation and surgical planning. Studies suggest this method can predict tumor histology and prognosis. Intraoperative MRI improves the extent of tumor resection and potentially patient survival. But due to its limitations it has alternative intraoperative techniques, like intraoperative ultrasound, fluorescence-guided surgery, direct electrical stimulation, deep brain stimulation, but evidence for most of these methods is limited for most brain tumors. Only ultrasound showed real-time tumor visualization and residual disease analysis offering high accuracy and is relatively inexpensive compared to ioMRI. This study can be useful to neurosurgeons, neuro-oncologists, neurologists, neuro-radiologists, and will demonstrate prospects for further research.

Keywords: Diffusion tensor imaging, Tumor excision, Intraoperative-ultrasound, Neurosurgery, Intraoperative imaging, Neuronavigation, Deep brain stimulation.

Introduction

Modern neuroradiology has made great progress, although it currently has its shortcomings in the diagnosis of most brain lesions without histopathology [1]. E. U. Okoro, A. Smolanka *et al.* described guided biopsy through ultrasound (US) and computer tomography (CT) as the foremost approaches for intracerebral biopsy not only aids in anticipating the selection of adjuvant therapy and determining the extent of resection but also underscores the absence of unanimity regarding the optimal biopsy method for brain lesions. Magnetic resonance imaging (MRI) at different periods of management of patients with intra-axial brain injuries is currently the most common imaging method [2]. Thus, scientists, despite the large list of imaging tools, are in search of methods that could satisfy all the requirements for safety and efficiency at various stages of the management patients with intra-axial brain lesions.

Interpretation of imaging data in cases of damage to brain structures (for example, tumor or traumatic origin) can be difficult due to factors such as fiber overlap and tissue edema [3]. Among the various types of intra-axillary brain lesions, gliomas of varying degrees of differentiation are one of the most problematic areas in neuroradiological studies and in neurosurgical practice. In the study of R. A. Volodymyrovych *et al.* it was shown that age older than 45 years and a high degree of anaplasia on MRI significantly reduce patient survival to about 17 months after the operation [4]. The grading system proposed by the authors allows preoperative assessment of tumor resectability, which, together with the use of 3D surgical planning and MRI navigational support, makes it possible to perform safe resection and prevent development of postoperative neurological disorders.

It is worth noting among such large-scale projects «The Human Connectome Project», that is a collaborative initiative to improve diffusion tensor imaging (DTI) and it has resulted in an impressive map of functional pathways and connections in the human brain [5]. In practical terms, integrating diffusion tensor imaging (DTI), functional MRI, and connectome analysis into surgical planning proves invaluable for neurosurgeons, particularly when confronting tumors exhibiting infiltrative growth patterns such as gliomas. But traditional MRI has the inability to visualize fiber anatomy in detail in structures such as the brainstem and the inability to accurately distinguish between different types of tumors, such as high-grade gliomas and solitary metastases [6]. The other limitations are the following: cost-effectiveness and accessibility, image distortions, limited functional specificity and many others. Traditional MRI has the inability to visualize fiber anatomy in detail in structures such as the brainstem and the inability to accurately distinguish between different types of tumors, such as high-grade gliomas and solitary metastases.

Intra-axial brain tumors pose a serious health threat and face many challenges in diagnosis and treatment. Thus, the purpose of this work is to study various brain imaging methods that can be used pre- and intraoperatively, their benefits and drawbacks for effective management of intra-axial brain lesions.

Materials and Methods

The conducted research is presented in the form of a theoretical systematic review. The research used the methods of comparative analysis of scientific literature, abstraction and synthesis as the main methods of scientific knowledge. Data selection and analysis was performed among review articles and published studies among PubMed database. The search was conducted in English by filtering publications in the time frame from January 1, 2019 to March 10, 2024. Keywords used for the search included "intra-axial brain lesions", "intra-axial brain tumors", "brain imaging", "brain MRI", "intraoperative MRI" and modern techniques of intra-axial brain lesion management. Part of the research was obtained from the list of literature with active links, as well as using the Google Academy search engine with search queries in Ukrainian and English by keywords.

Filtering of publications obtained during the search was carried out using inclusion and exclusion criteria from the study. The following criteria were chosen for inclusion in the review: (1) articles must be published within the specified time frame; (2) articles must be published in academically significant resources (scientific journals); (3) the articles should be review, comparative, and experimental studies in which the topic of pre-, intra- and postoperative techniques is described for intra-axial type brain lesion. Despite the fact that some papers did not meet the previously established deadline, it was still decided to include them in the review because their data coincided with the data of the initially selected papers, corresponded to the objectives of the study and addressed the questions asked.

The exclusion criteria from the study were: (1) Incompletely published research results; (2) missing parts of the study (*eg*, abstract or discussion); (3) studies published by the same author or group of authors; (4) studies related to all types of brain lesions, but without indication or comparison with intra-axial brain lesions specifically.

In the course of filtering, 34 sources were included in the literature review. Data were obtained from the selected articles, including the name of the first author or all authors (if the number did not exceed 2), characteristics of the studies (*eg*, type and purpose of the study), and the main results of the studies relevant to the search topic.

Results and Discussion

Current possibilities and limitation of magnetic resonance imaging

Functional MRI encompasses two primary types: targeted and resting-state, with the latter predominantly employed in preoperative planning [7]. Nevertheless, the reliability of functional MRI findings may be compromised by tumors altering blood supply dynamics [8]. High-grade gliomas, for instance, can induce abnormal vascular proliferation and tumor necrosis, disrupting the blood-brain barrier and causing leakage of intravenous gadolinium contrast agent into the vasculature. This extravasation manifests as shortening and hyperintensity on T1-weighted images, commonly referred to as "contrast enhancement."

Connectome analysis offers insights into both functional localization and intrinsic brain networks [7-9]. Within the human brain, numerous crucial white matter pathways exist, among which the corticospinal tract stands out. Responsible for conveying signals essential for motor control, preserving the integrity of corticospinal tracts proves pivotal in averting movement disorders [8]. Diffusion tensor imaging MRI allows visualization of white matter fibers, reflecting their orientation relative to the direction of water diffusion and based on the concept of isotropic and anisotropic diffusion, which allows detailed visualization and segmentation of white fiber bundles and provides important information about tumor boundaries, its spread, neighboring paths and much more [9, 10]. This information can play a key role in non-invasive diagnosis, preoperative tumor classification, biopsy planning, surgical planning and prognosis. In a study by D.K. Karmakar *et al.* among 91 patients with gliomas of varying degrees of malignancy, total tumor excision was performed mainly in patients with fiber displacement on DTI, and subtotal resections were performed mainly in cases of damage and infiltration in the conduction tracts. Correlation between the histopathological appearance and DTI tractography showed that intact/displaced tracts were observed mainly in low grade glioma differentiated (79%), whereas in 86% of high grade glioma, destroyed/infiltrated fibers were observed. Therefore, the authors conclude that preoperative DTI for brain tumors is an important tool for selecting the appropriate surgical approach for maximally safe resection, which improves the postoperative neurological outcome of patients. It also helps predict tumor histology and also serves as an important indicator of prognosis.

Enhancing control over brain tumors aligns closely with the objective of safely expanding the extent of resection, facilitated by advancements in imaging techniques and potentially broadening resection margins [11]. Initially, intraoperative MRI (ioMRI) was considered as an additional safety method when neuronavigation became less reliable due to brain deformation and loss of cerebrospinal fluid during surgery [12]. The use of intraoperative MRI can influence the decision to perform additional resection of visible residual tumor, which significantly reduces the volume of both low-grade and high-grade tumors. In accordance with data from Z. Li, Y. Song Y, H.U. Farrukh Hameed *et al.* intraoperative MRI has a positive effect, not only improving the extent of tumor resection (gross total resection of 83.85% in the iMRI group vs. 50.00% in the control group), but also increasing the survival rates of patients with gliomas (overall survival of 33.58 months in the iMRI vs. 21.16 months in the control group) [13]. For institutions equipped with intraoperative MRI, this is a powerful tool for enhancing tumor control. In a systematic review, Giussani, C., Trezza, A., Ricciuti, V., *et al.* in 38% of cases, additional resection was required after ioMRI scanning in pediatric cohort [14]. This study also compared intraoperative MRI with intraoperative ultrasonographic examination, which will be mentioned in the following section. Figure 1 and 2 presents illustrative examples of DTI and ioMRI taken from published clinical cases of M. Tamura, H. Kurihara, T. Saito, *et al.* and K. Bunyaratavej, K. *et al.*

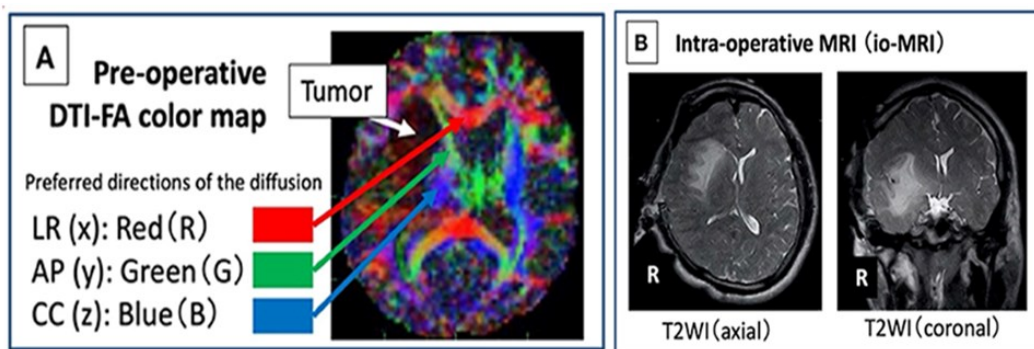


Figure 1. Examples of images obtained preoperatively with assistance intraoperative MRI (B) and intraoperatively with assistance Diffusion tensor imaging MRI (A) Source: [15].

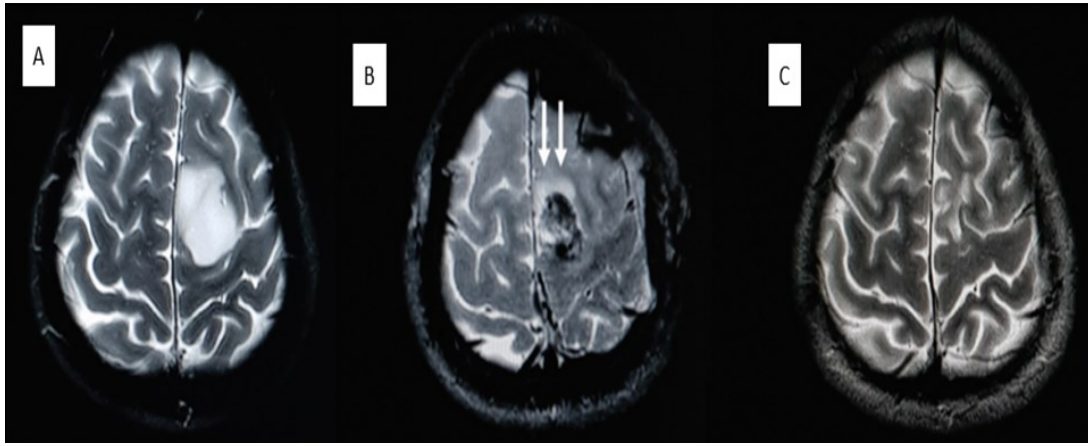


Figure 2. Example of images obtained preoperatively with assistance preoperative (A), intraoperative (B) and postoperative (C) MRI Source: [16].

According to R. Morabito, C. Alafaci, S. Pergolizzi *et al.* MRI perfusion techniques, including Dynamic Susceptibility Contrast-enhanced (DSC) and Dynamic Contrast-Enhanced (DCE), utilize a gadolinium-based contrast agent administered intravenously to aid in distinguishing between tumor recurrence and radiation necrosis in follow-up after radiosurgery [17]. This non-invasive approach not only enhances diagnostic accuracy but also informs treatment planning and monitoring.

In tandem with intraoperative MRI, fluorophore agents like fluorescein, indocyanine green, and 5-aminolevulinic acid (5-ALA) can facilitate fluorescence-guided surgery. Notably, among these agents, only 5-ALA has approval from the Food and Drug Administration (FDA) for high-grade glioma treatment [18]. Thus, in a study by A.J. Schupper, R.B. Baron, W. Cheung *et al.* 69 patients underwent fluorescence-guided surgery with 5-ALA and this technique. The study revealed a sensitivity of 96.5%, a specificity of 29.4%, a positive predictive value for histopathology indicating high-grade gliomas (HGG) of 95.4%, and a diagnostic accuracy of 92.4%. Drug-related adverse events, primarily photosensitivity reactions, were observed in 22% of cases, with 4.3% deemed serious. Lower preoperative tumor volume and use of intraoperative MRI predicted lower residual tumor volume. Also, 5-ALA fluorescence in combination with photodynamic therapy is being studied to identify an additional antitumor cytotoxic effect with stimulation of local formation of cytotoxic free radicals, which is quite promising, but at the moment there is little existing data to implement such a method in a daily practice, as and in general, evidence of the effectiveness of fluorescence is limited to patients with other types of intra-axial brain tumors [19].

Other visualization methods for intra-axial lesions and their comparative characteristics

At the same time, excellent practical and statistical outcomes in patients with intra-axial tumors were demonstrated by intraoperative ultrasound examination (ioUS). Thus, a study by L. Dixon used navigational intraoperative brain ultrasound to guide tumor resection and detect residual lesion using convex and linear probes [20]. Figure 3 presents illustrative examples of ioUS and ioMRI of glioblastoma taken from this study.

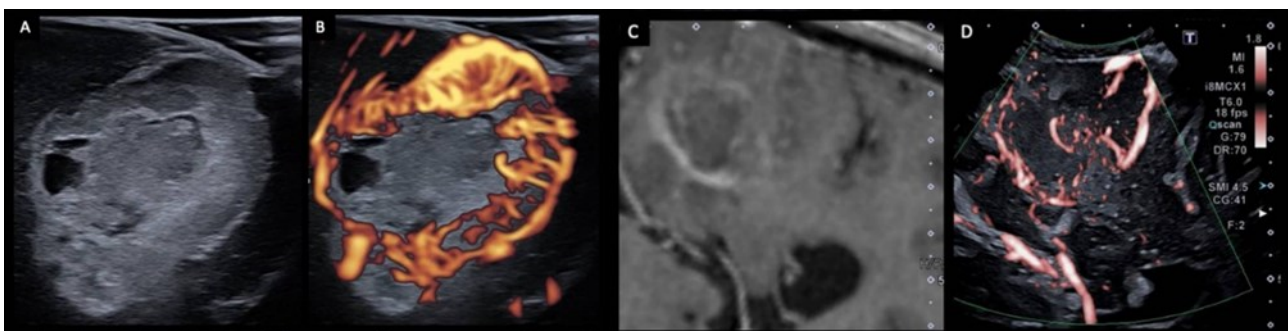


Figure 3. Examples of images obtained intraoperatively with assistance of intraoperative US at B-mode (A), doppler (B, D) and intraoperatively with assistance MRI © Source: [20].

The study included 80 patients, with gliomas accounting for 73%, metastatic processes 21.6%, and other tumors 5.7%. Most tumors (75%) were clearly visible on ultrasound, with the exception of tumors in the insula. The regression model revealed an exceptionally high correlation between tumor volumes on MRI and intraoperative ultrasound, with ultrasonographic visibility notably influencing this correlation, particularly for tumors with high visibility. While the correlation between postoperative MRI and ioUS was weaker for residual tumors, it remained statistically significant. In summary, the authors assert that ioUS proves to be a dependable intraoperative technique, enabling real-time monitoring of brain tumor resections and facilitating volumetric analysis of residual lesion.

In a study conducted by researchers C. de Quintana-Schmidt, L. Salgado-Lopez, J.A. Aibar-Duran *et al.*, involving 100 patients who underwent intra-axial resection of brain tumors, notable findings emerged [21]. Among the patients, 53 had high-grade gliomas, 26 had metastases, 14 had low-grade gliomas, and 7 had other tumor types. The study reported that 96% of lesions were clearly visualized, with the tumor margin clearly demarcated in 71% of cases. Agreement with preoperative MRI data was observed in 78% of cases. The average sterile probe coating time was slightly over 2 minutes, while the average image acquisition time was approximately 2.5 minutes. Factors such as tumor location in the insula, low-grade glioma, awake surgery, and tumor recurrence were associated with a statistically significant increase in the duration of ultrasound use. Ultrasound demonstrated a sensitivity of 94.4% and a specificity of 100% for detecting residual tumor. Additionally, a systematic review focusing on a pediatric cohort indicated that intraoperative ultrasound exhibited high accuracy in delineating resection boundaries in 77% of cases, which was further confirmed by post-operative MRI in 68% of cases [22]. These findings underscore the notion that expensive equipment does not always equate to superior performance, as evidenced by the pediatric cohort wherein ioUS demonstrated efficacy nearly identical to that of intraoperative MRI.

Direct electrical stimulation (DES) stands as an invaluable surgical adjunct for identifying critical functional changes intraoperatively in cases of intra-axial brain tumors. Unlike techniques such as MRI, electrical stimulation offers direct insights into the functional capacity of specific brain regions and is commonly perceived to simulate the effects of a temporary lesion in the stimulated area [23, 24]. Statistical data on the use of DES in brain lesion management may vary depending on the specific condition being treated, the patient population, and the surgical center. Using the example of gliomas Li, T., Bai, H., Wang, G., *et al.* showed up that total tumor resection under DES control was achieved in 58,2% cases and subtotal – 33,3% [24]. Nevertheless, DES does have notable limitations, including the need for exposure to the surgical field and restricted intraoperative testing time during awake procedures, along with the absence of bilateral stimulation capabilities. Furthermore, tasks are typically constrained to simple movements or verbal tasks feasible within the operating room setting during an awake craniotomy. However, advancements such as FDA-approved cranial implants for epilepsy treatment, capable of both stimulating and recording neural data, are opening avenues to explore broader neural networks in more natural neural environments [25].

Deep brain stimulation has established itself as an adjunct to potential recording in identifying, mapping and characterizing subcortical structures in conditions such as tremor and dystonia (*eg.*, Parkinson's disease) [26, 27]. Intraoperative methods of micro- and/or macrostimulation in awake patients with DBS help to identify somatotopy of sensorimotor subregions in such intracranial structures as the ventral intermediate and ventral caudal parts of the thalamus, subthalamic nucleus, globus pallidus and others, which may be difficult to access with other techniques. Similarly, these stimulation techniques hold promise in refining the localization of potential subcortical therapeutic targets, aiming to achieve maximal clinical efficacy with minimal stimulation thresholds, while mitigating adverse effects such as sustained paresthesia, seizures, diplopia, dysarthria, others. For example, in a study by T. Eibl, M. Schrey, A. Liebert, *et al.* 75 patients were assessed and their resting motor threshold scores were statistically higher in patients with upper limb paresis and lower in patients with high-grade gliomas [28]. An inverse correlation was also found with the age of the patient and the volume of edema near the lesion – thus, an increase in the infiltration of perifocal edema of the motor parts of the brain reduces the values of the resting motor threshold. The authors conclude that electrical stimulation techniques can detect lesion-specific findings that can be used in clinical work to inform motor mapping. In the study conducted by A.G. Yearley *et al.*, which involved 80 patients with 157 implanted deep brain stimulation (DBS) electrodes, targeting the subthalamic nucleus exhibited significantly larger trajectory errors compared to those targeting the nucleus of the inner part of the globus pallidus [29]. The authors highlighted that when comparing intraoperative MRI with postoperative CT, where errors averaged <1 mm, DBS failed to demonstrate its efficacy, prompting consideration of other neuro mapping methods as more pertinent.

In a comprehensive analysis, I.J. Gerard and colleagues underscored the invaluable advantages of intraoperative neuronavigation in awake patients [30]. Neuronavigation (using MRI and ioUS) approach not only facilitates precise localization of damage within eloquent cortical and subcortical areas but also enhances comprehension of the intricate relationship between the skull base and intracranial vessels, thereby mitigating the risk of vascular injury and optimizing lesion resection. The integrated strategy for brain tumor resection, integrating multimodal MRI, neuronavigation, and awake craniotomy with motor and language areas mapping, empowers neurosurgeons to mitigate the likelihood of enduring neurological deficits while enabling maximal tumor removal while preserving patients' functional integrity [31, 32]. A noteworthy epidemiological study by A. Mansouri *et al.* sheds light on neurosurgeons' practice, revealing that 60.8% of neurosurgeons believed that any lesion, even if nearby without infiltration, suffices to determine involvement of cortical/subcortical motor pathways [33]. Moreover, 82.4% of respondents deemed motor mapping necessary for brain tumors affecting motor pathways, irrespective of tumor histology or patient age. Regarding the choice between awake and asleep mapping, 90.2% cited tumor location as the primary determinant, while 31.4% favored awake mapping for all cases.

Thus, improvements in MRI techniques, including diffusion tensor imaging and tractography, provide neurosurgeons with the opportunity to study the relationships between brain damage and critical functional pathways preoperatively. This makes it possible to maintain surgical boundaries defined by functional pathways, which helps to increase the volume of tumor resection and maintain functional activity. Strategies such as intraoperative MRI continue to be actively used, and new adjuvant tools, including fluorescent agents, may further improve patient survival by optimizing the extent of resection. Neuronavigation ultrasound can be considered as a preferred real-time intraoperative imaging technique because it does not significantly increase surgical time and provides optimal visualization of intra-axial brain lesions and residual tumor comparing to MRI.

Conclusions

In conclusion, effective management of intra-axial brain lesions is highly dependent on modern imaging modalities and multispecialty team work. Advanced MRI techniques such as DTI, DSC, DCE are better because they have a higher spatial and contrast resolution and provide functional information. These imaging techniques help in achieving optimal management of axial brain lesions by ensuring accurate delineation of lesion boundaries for better diagnosis and subsequent management such as surgery, radiation therapy, and chemotherapy. They are also crucial for the surgeon's plan to remove the lesion while avoiding adjacent healthy brain matter responsible for essential functions such as movement and sensory functions. Serial imaging allows for assessment of the response to therapy and predict the need to adjust the therapy with time. Improved imaging possibilities are likely to revolutionize efficient management of intra-axial brain tumors. A multimodal imaging approach means combining various imaging techniques. For example, such techniques as fluorescence-guided surgery, intraoperative ultrasound, direct electrical stimulation, deep brain stimulation can greatly detail and change the course of intra-axial lesion therapy, although each of these methods has its own limitations and post-procedural complications. Nonetheless, challenges remain. These include financial burden, availability, and absence of standardized protocols. Furthermore, ioUS is particularly useful in improving surgical precision and reduces the risk of collateral damage and it does not need extra financial cost. It also demonstrated good efficacy in different patient groups, as evidenced by good survival rates and high resection rates, Future research should focus on addressing these challenges and further refining the role of modern imaging modalities in the management of intra-axial brain lesions, including refining MRI techniques (diffusion tensor imaging, tractography) for preoperative planning, utilizing fluorescent agents to improve visualization of different tumors during surgery and usage of ultrasound in different cohorts.

Conflict of Interest

The authors declare no conflict of interest.

References

1. Okoro, E. U., Smolanka, A., Smolanka, V., Devinyak, O., & Havryliv, T. 2023. Biopsy of intrinsic brain lesions: comparison of computed tomography-guided stereotactic and real-time ultrasound-guided techniques. *Journal of Neurosurgery*, 1:1-6. <https://doi.org/10.3171/2023.7.JNS231310>
2. Ungar, L., Zibly, Z., Wohl, A., *et al.* 2021. Utility of the Polestar N30 low-field MRI system for resecting non-enhancing intra-axial brain lesions. *Neurol Neurochir Pol.* 55(2):202-211. doi:10.5603/PJNNS.a2021.0017

3. Wu, A., Wu, J.Y., Lim, M. 2022. Updates in intraoperative strategies for enhancing intra-axial brain tumor control. *Neuro Oncol.* 24(Suppl 6):S33-S41. doi: 10.1093/neuonc/noac170. PMID: 36322098; PMCID: PMC9629479.
4. Volodymyrovych, R. A., Mykolajovych, K. V., Davydovych, R. V., Volodymyrovych, D. A., Pavlivna, F. Z. 2019. Surgical management of periventricular glioma: decision-making and preoperative assessment of resectability. *Ukrainian Neurosurgical Journal*, (1), 40-47. <https://doi.org/10.25305/unj.153708>
5. Elam, J.S., Glasser, M.F., Harms, M.P., *et al.* 2021. The Human Connectome Project: A retrospective. *Neuroimage.* 244:118543. doi:10.1016/j.neuroimage.2021.118543
6. Radwan, A.M., Emsell, L., Blommaert, J., *et al.* 2021. Virtual brain grafting: Enabling whole brain parcellation in the presence of large lesions. *Neuroimage.* 229:117731. doi:10.1016/j.neuroimage.2021.117731
7. Cacciaguerra, L., Rocca, M.A., Storelli, L., Radaelli, M., Filippi, M. 2021. Mapping white matter damage distribution in neuromyelitis optica spectrum disorders with a multimodal MRI approach. *Mult Scler.* 27(6):841-854. doi:10.1177/1352458520941493
8. Carrete, L.R., Young, J.S., Cha, S. 2022. Advanced Imaging Techniques for Newly Diagnosed and Recurrent Gliomas. *Front Neurosci.* 16:787755. doi:10.3389/fnins.2022.787755
9. Karmakar, D.K., Badhe, P.V., Mhatre, P., Shrivastava, S., Sultan, M., Shankar, G., Tekriwal, K., Moharkar, S. 2023. Utility of Diffusion Tensor Imaging in Assessing Corticospinal Tracts for the Management of Brain Tumors: A Cross-Sectional Observational Study. *Cureus.* 15(10):e47811. doi: 10.7759/cureus.47811. PMID: 38021806; PMCID: PMC10679788.
10. Khan, K.A., Jain, S.K., Sinha, V.D., Sinha, J. 2019. Preoperative Diffusion Tensor Imaging: A Landmark Modality for Predicting the Outcome and Characterization of Supratentorial Intra-Axial Brain Tumors. *World Neurosurg.* 124:e540-e551. doi:10.1016/j.wneu.2018.12.146
11. Shin, H., Park, J.E., Jun, Y., *et al.* 2023. Deep learning referral suggestion and tumour discrimination using explainable artificial intelligence applied to multiparametric MRI. *Eur Radiol.* 33(8):5859-5870. doi:10.1007/s00330-023-09710-0
12. Luna, L.P., Drier, A., Aygun, N., *et al.* 2021. MRI features of intra-axial histiocytic brain mass lesions. *Clin Radiol.* ;76(2):159.e19-159.e28. doi:10.1016/j.crad.2020.09.015
13. Li, Z., Song, Y., Farrukh Hameed, N.U., *et al.* 2024. Effect of high-field iMRI guided resection in cerebral glioma surgery: A randomized clinical trial. *Eur J Cancer.* 199:113528. doi:10.1016/j.ejca.2024.113528
14. Giussani, C., Trezza, A., Ricciuti, V., *et al.* 2022. Intraoperative MRI versus intraoperative ultrasound in pediatric brain tumor surgery: is expensive better than cheap? A review of the literature. *Childs Nerv Syst.* 38(8):1445-1454. doi:10.1007/s00381-022-03800-0
15. Tamura, M., Kurihara, H., Saito, T., *et al.* 2022. Combining Pre-operative Diffusion Tensor Images and Intraoperative Magnetic Resonance Images in the Navigation Is Useful for Detecting White Matter Tracts During Glioma Surgery. *Front Neurol.* 12:805952. doi:10.3389/fneur.2021.805952
16. Bunyaratavej, K., Siwanuwatn, R., Tuchinda, L., Wangsawatwong, P. 2022. Impact of Intraoperative Magnetic Resonance Imaging (i-MRI) on Surgeon Decision Making and Clinical Outcomes in Cranial Tumor Surgery. *Asian J Neurosurg.* 17(2):218-226. doi:10.1055/s-0042-1751008
17. R. Morabito, C. Alafaci, S. Pergolizzi, *et al.* 2019. DCE and DSC perfusion MRI diagnostic accuracy in the follow-up of primary and metastatic intra-axial brain tumors treated by radiosurgery with cyberknife. *Radiat Oncol.* 14(1):65. doi:10.1186/s13014-019-1271-7
18. Schupper, A.J., Baron, R.B., Cheung, W., *et al.* 2021. 5-Aminolevulinic acid for enhanced surgical visualization of high-grade gliomas: a prospective, multicenter study. *J Neurosurg.* 136(6):1525-1534. doi:10.3171/2021.5.JNS21310
19. Li, K., Dong, W., Miao, Y., Liu, Q., Qiu, L., Lin, J. 2021. Dual-targeted 5-aminolevulinic acid derivatives with glutathione depletion function for enhanced photodynamic therapy. *J Photochem Photobiol B.* 215:112107. doi:10.1016/j.jphotobiol.2020.112107
20. Dixon, L., Lim, A., Grech-Sollars, M., Nandi, D., Camp, S. 2022. Intraoperative ultrasound in brain tumor surgery: A review and implementation guide. *Neurosurg Rev.* 45(4):2503-2515. doi: 10.1007/s10143-022-01778-4. PMID: 35353266; PMCID: PMC9349149.
21. de Quintana-Schmidt, C., Salgado-Lopez, L., Aibar-Duran, J.A., *et al.* 2022. Neuronavigated Ultrasound in Neuro-Oncology: A True Real-Time Intraoperative Image. *World Neurosurg.* 157:e316-e326. doi:10.1016/j.wneu.2021.10.082

22. Aibar-Duran, J.A., Salgado-López, L., Anka-Tugbiyele, M.O., *et al.* 2024. Navigated intraoperative ultrasound in neuro-oncology: volumetric accuracy and correlation with high-field MRI. *J Neurosurg*. doi:10.3171/2023.10.JNS231244
23. Boerger, T.F., Pahapill, P., Butts, A.M., Arocho-Quinones, E., Raghavan, M., Krucoff, M.O. 2023. Large-scale brain networks and intra-axial tumor surgery: a narrative review of functional mapping techniques, critical needs, and scientific opportunities. *Front Hum Neurosci*. 17:1170419. doi:10.3389/fnhum.2023.1170419
24. Li, T., Bai, H., Wang, G., *et al.* 2015. Glioma localization and excision using direct electrical stimulation for language mapping during awake surgery. *Exp Ther Med*. 9(5):1962-1966. doi:10.3892/etm.2015.2359
25. Viganò, L., Callipo, V., Lamperti, M., *et al.* 2022. Transcranial versus direct electrical stimulation for intraoperative motor-evoked potential monitoring: Prognostic value comparison in asleep brain tumor surgery. *Front Oncol*. 12:963669. doi:10.3389/fonc.2022.963669
26. Visser-Vandewalle, V. 2023. Networkmodulation through deep brain stimulation. *Tijdschr Psychiatr*. 65(10):619-623. <https://pubmed.ncbi.nlm.nih.gov/38174396/>
27. Soumpasis, C., Díaz-Baamonde, A., Ghimire, P., *et al.* 2023. Intraoperative Neuromonitoring of the Visual Pathway in Asleep Neuro-Oncology Surgery. *Cancers (Basel)*. 2023;15(15):3943. doi:10.3390/cancers15153943
28. Eibl, T., Schrey, M., Liebert, A., *et al.* 2023. Influence of clinical and tumor-specific factors on the resting motor threshold in navigated transcranial magnetic stimulation. *Neurophysiol Clin*. 53(6):102920. doi:10.1016/j.neucli.2023.102920
29. Yearley, A.G., Chua, M., Horn, A., Cosgrove, G.R., Rolston, J.D. 2023. Deep Brain Stimulation Lead Localization Variability Comparing Intraoperative MRI Versus Postoperative Computed Tomography. *Oper Neurosurg (Hagerstown)*. 25(5):441-448. doi:10.1227/ons.0000000000000849
30. Gerard, I.J., Kersten-Oertel, M., Hall, J.A., Sirhan, D., Collins, D.L. 2021. Brain Shift in Neuronavigation of Brain Tumors: An Updated Review of Intra-Operative Ultrasound Applications. *Front Oncol*. 10:618837. doi:10.3389/fonc.2020.618837
31. Šteňo, A., Hollý, V., Mendel, P., *et al.* 2018. Navigated 3D-ultrasound versus conventional neuronavigation during awake resections of eloquent low-grade gliomas: a comparative study at a single institution. *Acta Neurochir (Wien)*. 160(2):331-342. doi:10.1007/s00701-017-3377-8
32. Chen, X., Sun, J., Jiang, W., *et al.* 2022. Awake craniotomy for removal of gliomas in eloquent areas: An analysis of 21 cases. *Brain Res Bull*. 181:30-35. doi:10.1016/j.brainresbull.2021.12.017
33. Mansouri, A., Ibrahim, S., Bello, L., Martino, J., Velasquez, C. 2023. The current state of the art of primary motor mapping for tumor resection: A focused survey. *Clin Neurol Neurosurg*. 229:107685. doi:10.1016/j.clineuro.2023.107685

Citation: Okoro EU, Havryliv T, Aigbogun J, Smolanka A. Literature Review on Effective Use of Modern Modalities in Management of Intra-Axial Brain Lesions. *SVOA Neurology* 2024, 5:4, 157-164.

Copyright: © 2024 All rights reserved by Okoro EU, et al. This is an open access article distributed under the Creative Commons Attribution License, which permits unrestricted use, distribution, and reproduction in any medium, provided the original work is properly cited.