

# Intraorbital AVF Treated by Direct Puncture of the Superior Ophthalmic Vein: A Case Report and Review of the Literature

José Manuel Muñoz-Olmedo<sup>1\*</sup>, Irene Martínez-González<sup>1</sup>, Julián Cuesta-Pérez<sup>2</sup>, Gonzalo Vega Muñoz<sup>3</sup>, Eduardo Bárcena-Ruiz<sup>4</sup>, Pedro Saura-Lorente<sup>4</sup>, David Seoane<sup>4</sup> and Federico Ballenilla-Marco<sup>4</sup>

<sup>1</sup> Interventional Neuroradiology, University hospital of Getafe, Madrid, Spain.

<sup>2</sup> Vascular and Interventional Radiology Head, University hospital of Getafe, Madrid, Spain.

<sup>3</sup> Interventional Neuroradiology, University hospital of Getafe, Madrid, Spain.

<sup>4</sup> Interventional Neuroradiology, University hospital of 12 de Octubre, Madrid, Spain.

\*Corresponding Author: José Manuel Muñoz-Olmedo, Interventional Neuroradiology, University hospital of Getafe, Madrid, Spain.

DOI: <https://doi.org/10.58624/SVOANE.2024.05.0150>

Received: September 09, 2024 Published: September 30, 2024

## Abstract

Intraorbital AV fistulas are quite uncommon, so they are a challenge for most neurointerventional teams. Since a venous approach has shown better results, it is the preferred approach for physicians, but it is not always feasible. A direct puncture of the superior ophthalmic vein (SOV) as shown in this case is a safe and quick alternative in such cases, providing a definitive solution for the patient.

**Keywords:** AV fistula, Intraorbital, Vascular malformation.

## Introduction

Intraorbital arteriovenous fistulas (AVFs) represent an extremely rare, yet clinically significant, vascular anomaly characterized by aberrant shunting between orbital arteries and veins. Its precise incidence is not known, but in 2014 only 26 cases have been described. These malformations disrupt normal hemodynamics within the orbit, often leading to a spectrum of ophthalmologic and neurologic sequelae, including proptosis, chemosis, pulsatile exophthalmos, and, in severe cases, visual impairment or blindness.

The etiology of intraorbital AVFs is multifactorial, encompassing congenital predispositions, traumatic events, and iatrogenic causes, such as complications from orbital surgery or catheterization procedures. (1-3)

The complexity of the orbital anatomy, coupled with the potential for severe complications, underscores the critical need for accurate diagnosis and timely intervention. Advanced imaging modalities, including digital subtraction angiography (DSA) and magnetic resonance imaging (MRI), have enhanced the diagnostic precision for these lesions, facilitating the identification of feeding arteries, draining veins, and the specific location of the fistula. (4)

Treatment options for orbital AVFs include endovascular embolization, which has become the preferred approach due to its minimally invasive nature and high success rate. Embolization involves the selective occlusion of the fistula through transarterial or transvenous routes, often using coils, liquid embolic agents, or stents.

A venous approach is preferred, when possible, because of lower complications. Surgical intervention, though less common, may be indicated in cases where embolization is not feasible or fails, and involves direct ligation or resection of the fistula. Conservative management may be appropriate for low-flow fistulas with minimal symptoms, as these may resolve spontaneously. Early diagnosis and tailored treatment are crucial for preserving vision and preventing complications. (5)

In this case we present another feasible option when the endovascular route is not possible: direct puncture and coiling of the superior ophthalmic vein. We will expose the keys we found in the diagnosis, treatment and management of the patient, as well as the follow up.

### Case Presentation

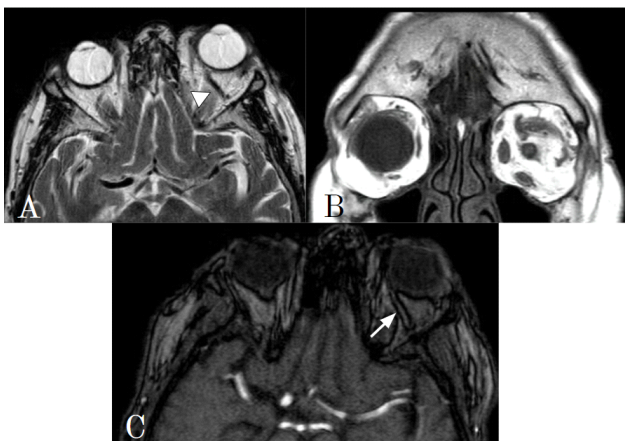
An 88 year old patient presented with a six months history of progressive visual loss, diplopia and limitation of left eye extrinsic mobility, plus left sided exophthalmus and intraocular pressure of 29 mm Hg (normal values 12-22 mm Hg).

A brain MRI (figure 1) was performed at her hospital. The findings suggested low-flow carotid-cavernous fistula. At that moment the patient was transferred to our institution to carry out a digital subtraction angiography (DSA). Angiography showed intraorbital AVF (figure 2) among the ophtamic artery and the superior ophthalmic vein (SOV). The case was discussed with the Neurosurgery team and endovascular treatment was offered to the patient as a first approach.

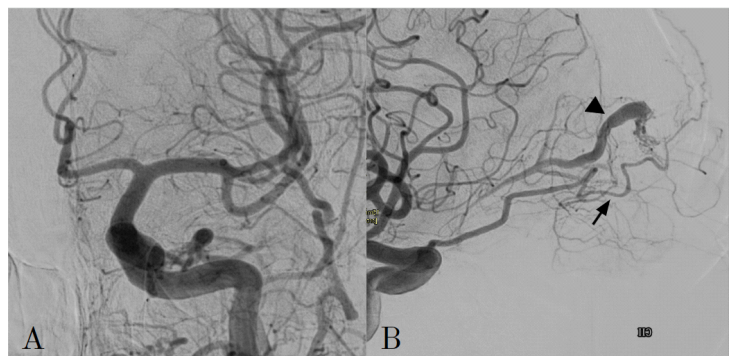
We catheterized the left ICA with a 5F diagnostic catheter for control and performed a venous navigation from the right femoral vein to the SOV, recanalizing the inferior petrosal sinus, navigating the cavernous sinus and finally placing in the left SOV with a 0,07" guidewire (Asahi Chikai). Unfortunately, there was a stenosis in the superior ophthalmic fissure, and we could not cross it with any microcatheter. Moreover, facial vein was not patent, so we did not have other options for venous navigation. Given that the fistula was in the most anterior part of the globe, treatment was performed by ultrasound and fluoroscopy guided puncture of the SOV and coiling through a 18G spinal puncture metallic needle (figure 3). Pressing downward with the transducer helped us not to puncture the globe. We employed two coils: 4x13 cm Optima Soft and 5x10 cm Optima Complex-10 Supersoft (Balt). Complete closure of the fistula was observed in the control run we performed.

The procedure ended without complications. The patient experienced some periorbital hematoma during the next week that did not required any extra measures and was discharged three days after the embolization.

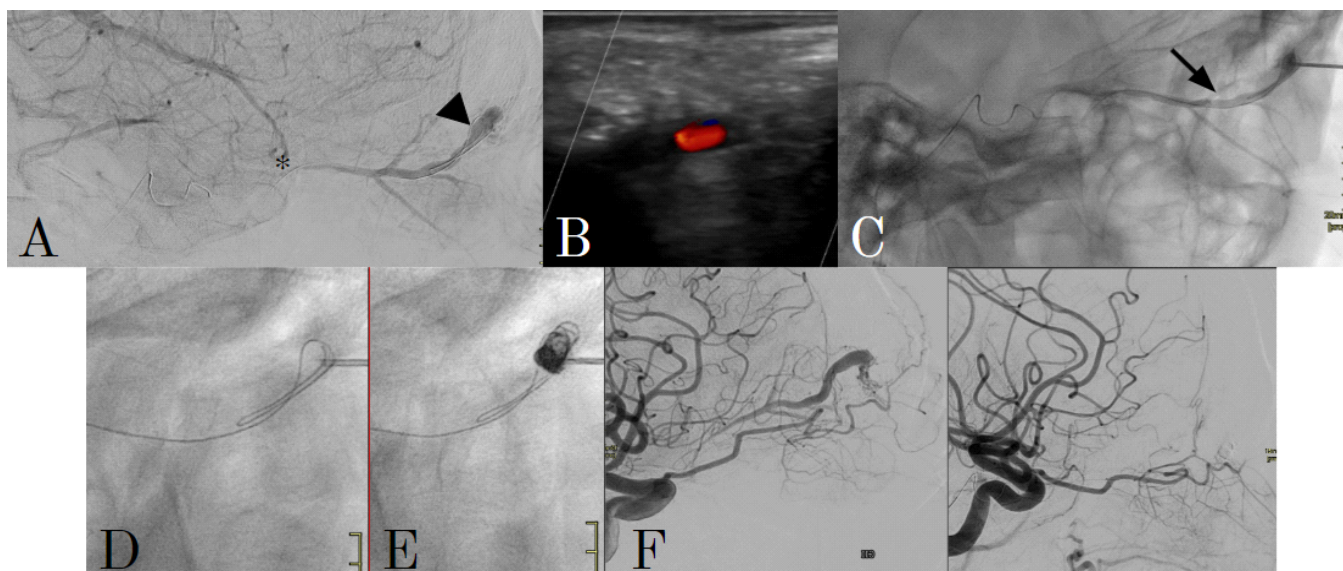
Three months later we performed a follow up DSA, with no recurrence of the fistula (figure 4). By then the patient recovered vision, normal ocular mobility and intraocular pressure dropped to normal values.



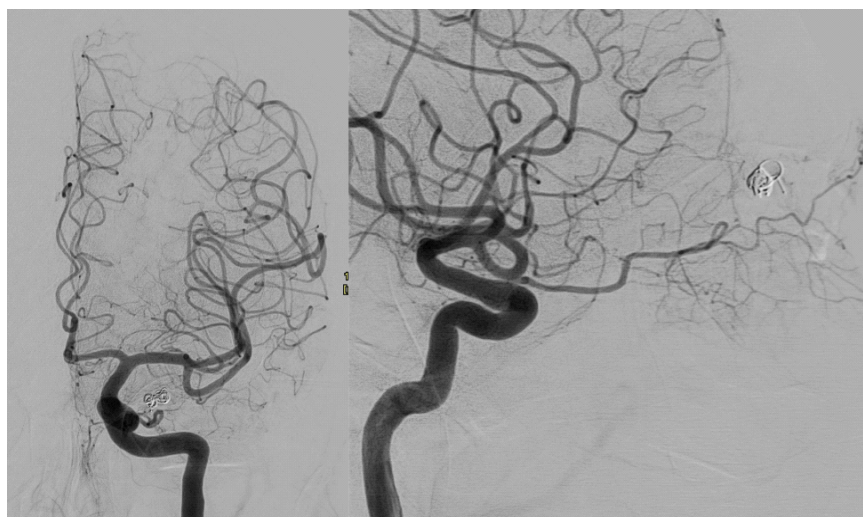
**Figure 1.** MR study shows axial T2 (A), coronal T2 (B) and 3D TOF (C) sequences. Enlarged SOV is appreciated in the left orbit (A, arrowhead), as well as left exophthalmus (B). 3D TOF shows slightly increased signal in the SOV (C, arrow) with no significant signal boost in any cavernous sinus.



**Figure 2.** DSA in AP (A) and lateral (B) views show abnormal connection among ophthalmic artery (B, arrow) and SOV (B, arrowhead). No nidus is present. These findings are consistent with intraorbital AVF.



**Figure 3.** DSA in lateral view (A) shows venous phase with navigation of a 0,07'' guidewire until the SOV (internal jugular vein - inferior petrosal sinus - cavernous sinus - SOV). Despite multiple attempts, it was impossible to navigate a microcatheter through the upper orbital fissure (asterisk). By Doppler-ultrasound (B) we checked the patency of the SOV and punctured it with a 18G metallic needle, checking our position by injecting contrast (C, arrow). We embolized deploying coils directly from the needle, with 4x13 cm Optima Soft and 5x10 cm Optima Complex-10 Supersoft (Balt) (D, E). Complete closing of the fistula was observed immediately after the procedure (F, pre and post-embolization).



**Figure 4.** Five months follow up shows no recurrence of the fistula. Patient remains asymptomatic with normal intraocular pressure.

## Discussion

Treatment options include endovascular embolization, surgical approaches, and, in select cases, conservative management. We decided to treat it because of the high intraocular pressure and the visual disturbance.

Endovascular embolization is the most common treatment modality and involves accessing the fistula either transarterially or transvenously. The transvenous route, typically via the superior ophthalmic vein (SOV) or cavernous sinus, is preferred when feasible, allowing the use of embolic agents such as coils or EVOH. The arterial approach is another valid option, but it may carry greater risk due to the proximity of critical vascular structures in the orbit (5).

In cases with difficult venous access or tortuous vessels, direct puncture of the SOV can be performed under imaging guidance, offering a safe alternative for embolization. Surgical treatment is typically reserved for cases where embolization is not possible or fails. It involves direct ligation or excision of the AVF, though this approach carries higher risks of orbital damage and postoperative complications, such as scarring and visual impairment.

We consider that direct puncture of the SOV, even not being a well-studied treatment option, should be systematically considered as a solid alternative when venous navigation is not possible, as it can quickly treat the disease avoiding a risky surgery, especially in a case like this one, with non-patent facial vein, given that the SOV can be reached through the facial vein, enabling safe treatment options when the intracranial route is not feasible (6).

The biggest paper related to direct puncture of the SOV has been published in 2024 by Pathuri SC et al and shows three cases in over fifty years, two out of three complicating with orbital hematoma, showing that they are a serious complication of which operators should be aware. (7) We did not experience any complications. In our opinion, the possibility of US guidance and coiling directly through the metallic needle allows less manipulation and diminishes the possibility of orbital hematoma. To our knowledge, this has not been described yet. It should be noted that more cases should be treated this way before suggesting the superiority of this technique, but as it has been stated before, intraorbital AVF is extremely rare.

In summary, endovascular embolization remains the gold standard for treating intraorbital AVFs, with direct SOV puncture offering an effective alternative in select cases. Surgical intervention remains a last resort due to its higher morbidity. Careful imaging and patient selection are critical to achieving successful outcomes.

## Conclusion

- Intraorbital AVF is a rare entity, and definitive diagnosis shall require DSA in most cases and is usually delayed.
- Endovascular approaches are preferred for definitive treatment and, when possible, venous approach is preferred.
- Direct puncture of the SOV is a quick and safe option when venous navigation is not possible.
- Embolization can be done directly from a metallic needle.

## Conflict of Interest

The authors declare no conflict of interest.

## References

1. Kupersmith MJ, Hurst R, Berenstein A, Choi IS. The benign course of cranial dural arteriovenous fistulas with cortical venous drainage. *J Neurosurg.* 1995;83(2):233-241.
2. Miller NR, Monsein LH, Debrun GM, Dandy WE. Treatment of orbital arteriovenous fistulas using a combination of detachable balloons and transvenous platinum microcoils. *Ophthalmology.* 1995;102(8):1164-1170.
3. Chaudhary MY, Sachdev VP, Cho SH, Weitzner I Jr, Ausman JI, Samii M. Traumatic arteriovenous fistula of the orbit. *AJNR Am J Neuroradiol.* 1982;3(4):501-503.
4. Diaz, R., Rodriguez, R., Almeida, P., & Ferrer, G. (2019). Spontaneous Intra-orbital Arteriovenous Fistula: A Rare Cause of Proptosis. *Cureus, 11*(10), e5984.
5. Ienaga, J., Tsukada, T., Watanabe, T., Sakai, Y., Uda, K., Shintai, K., Araki, Y., Nagatani, T., & Seki, Y. (2023). Transvenous embolization via the facial vein for intraorbital dural arteriovenous fistula: illustrative case. *Journal of neurosurgery. Case lessons, 6*(13), CASE23232.
6. Lv, X., Li, W., Liu, A., Lv, M., & Jiang, C. (2017). Endovascular treatment evolution for pure intraorbital arteriovenous fistula: Three case reports and literature review. *The neuroradiology journal, 30*(2), 151–159.
7. Pathuri, S. C., Johnson, W. C., Russell, K. L. P., Robledo, A., Albuquerque, F. C., Kan, P., & Mascitelli, J. R. (2024). Treatment of intraorbital arteriovenous fistulas with direct puncture: a case series and review of treatments since 1978. *Journal of neurointerventional surgery, jnis-2023-020967*

**Citation:** Muñoz-Olmedo JM, Martínez-González I, Cuesta-Pérez J, Muñoz GV, Bárcena-Ruíz E, Saura-Lorente P, Seoane D, Ballenilla-Marco F. Intraorbital AVF Treated by Direct Puncture of the Superior Ophthalmic Vein: A Case Report and Review of the Literature. *SVOA Neurology* 2024, 5:5, 193-196. doi. 10.58624/SVOANE.2024.05.0150

**Copyright:** © 2024 All rights reserved by Muñoz-Olmedo JM and other authors. This is an open access article distributed under the Creative Commons Attribution License, which permits unrestricted use, distribution, and reproduction in any medium, provided the original work is properly cited.