

Trapezio-Metacarpal Dislocation: A Rare Lesion: About Two Cases

Ben Amor Yosri*

Sfax Medical School, Tunisia

*Corresponding Author: Ben Amor Yosri, Sfax Medical School, Tunisia

Received: March 03, 2022 Published: March 28, 2022

Abstract

Purpose: By reporting two cases of trapezio metacarpal dislocation. We studied the physiopathology and surgical treatment.

Observations: The first patient was a 55-year-old man admitted for closed thumb trauma. The clinical exam found Tillaux sign. The radiograph of the hand showed dorsal dislocation of the trapezio metacarpal joint and bone tearing of the base of the first metacarpal. We used Wagner technique for TMJ stabilization. The second patient was a 12-year-old child who presented to describe a closed trauma right thumb. The radiograph of the hand showed a Trans trapezium dislocation of the trapezio-metacarpal joint and a trapezium fracture. Closed reduction, trapezium pinning and Iselin's tri-cortical pinning helped us to stabilize the joint.

Discussion: Trapezio-metacarpal dislocation associated with a Bennett fracture usually results from a thumb shear mechanism in adduction. Wagner's trapezio-metacarpal pinning reduces dislocation and subsequently stabilizes the joint. Trapezio-metacarpal dislocation associated with a trapezium fracture is usually the result of an axial compression mechanism.

Conclusion: However, the incarceration of capsulo-ligamentous lesions is an indication for open reduction and internal fixation. Apart from intra-articular ligamentous incarceration, reduction by external maneuvers and trapezio metacarpal pinning or inter metacarpal pinning represents the final steps in surgical treatment of trapezio-metacarpal dislocation.

Keywords: Pinning, Trapezium, Dislocation, Trapezio-metacarpal joint.

Introduction

Trapezio-metacarpal dislocation is a rare trauma of the first metacarpal ray. It is exceptionally isolated and is usually associated with a trapezium fracture and / or a fracture of the base of the first metacarpal [1-3]. The purpose of treatment is to reduce dislocation and subsequently stabilize the trapezio metacarpal joint.

The aim of this work is to present two cases of trapezio-metacarpal dislocation and to recall through this review of the literature the main etiopathogenic, diagnostic and therapeutic features of this rare trauma.

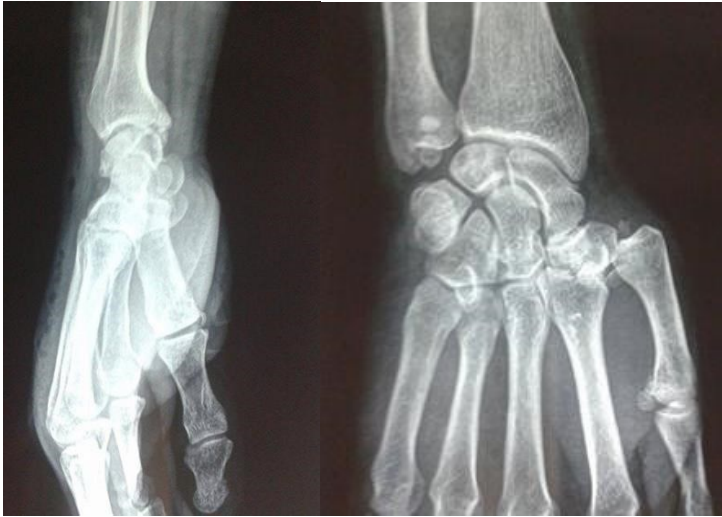Observations

First case

This was a 55-year-old man admitted through emergency for closed thumb trauma. The examination found a posterolateral dislocation of the trapezio metacarpal joint. The traction in the axis of the thumb perceives a projection corresponding to the reduction of luxation. Radiography of the hand showed complete dislocation of the trapezio metacarpal joint and bone tearing of the base of the first metacarpal (see Figures 1 and 2). Traction reduction and racking according to the Wagner technique (see Figure 3). After 8 months, Kapandji's score was 10/10.

Second case

This was a 12-year-old child who presented to describe following a domestic accident resulting in closed trauma to the right thumb. The examination found functional impotence and thumb deformity. X-ray of the hand showed Trans osseous dislocation of the trapezio metacarpal joint and vertical fracture of the trapezium (see Figures 4 and 5). Traction reduction and percutaneous pinning helped to stabilize the joint (see Figures 6 and 7). After 9 months, the child has a good Torque test.



Figures 1 and 2: First metacarpal fracture.

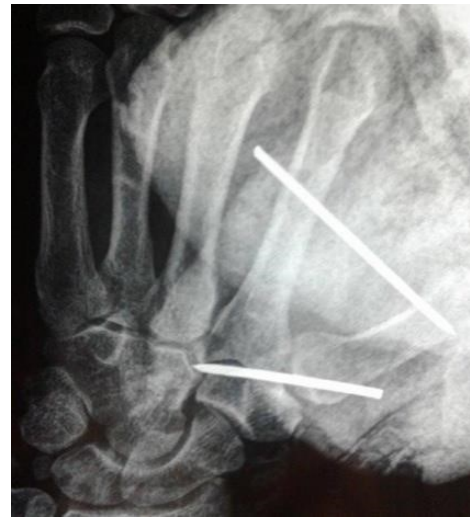
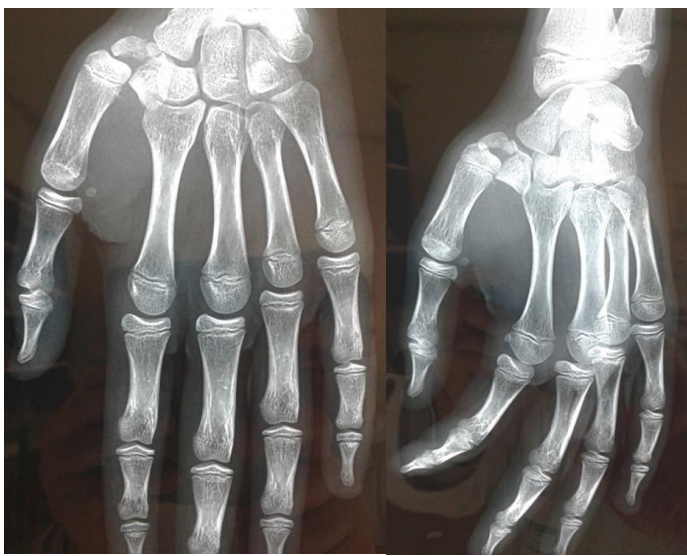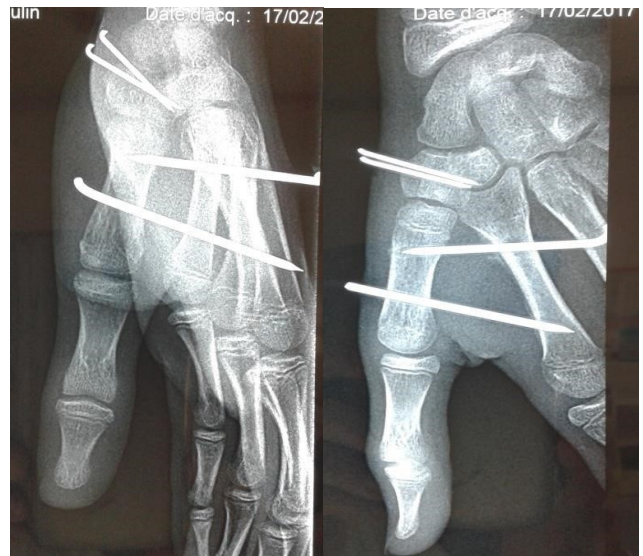


Figure 3: Wagner technique.



Figures 4 and 5: Fracture of the trapezium associated to trapezo metacarpal dislocation.



Figures 6 and 7: Percutaneous pinning of the trapezium associated to Iselin Technique

Discussion

Trapezio-metacarpal dislocations are rare injuries but deserve some attention [3, 4]. The trapezio-metacarpal joint is an articulation that Fick considers as saddle-rider [1]. Fracture of the trapezium is a frequent fracture of the second row of carpus [2]. The association with a Bennett fracture remains rare. Fractures of the trapezium are generally corporeal. They are articular and often vertical [4].

Four ligaments stabilize the trapezio-metacarpal joint. In case of dislocation, there will be a rupture of the dorso-radial ligament, whereas the oblique anterior ligament remains continuous with a sub periosteal tearing. The extension and the pronation of the thumb make it possible to extend it to facilitate its cicatrization [2, 3]. But if all the ligaments are ruptured, the articulation becomes completely unstable; early open repair is necessary, and the function of the dorso-radial ligament and oblique anterior ligament must be restored [2].

On the etiopathogenic level, several theories are advanced, but Monsche's theory remains and Manon's are the most common:

- Monsche theory: Following a commissural shear by the bicycle handlebars for example, the shear forces would lead to a fracture of the first metacarpal, a trapezius fracture and / or trapezo-metacarpal dislocation.
- Manon Theory: The radial styloid sinks like a wedge on the trapeze.
- Kindl's theory: This defends the idea that dislocation is due to axial compression on the first metacarpal retropulsion.
- Theory of Richard and Fèvre: exceptional [1]. It is often happening in axial compression [2].

In front of a thumb injured, it is necessary to obtain good x-rays. The effects of the wrist face and profile, made urgently, are not always explicit [3,8]. Kapandji incidences [9,10] are specific to the trapezio-metacarpal joint. Thus, the frontal image is well made if the projection of the sesamoid on the head of the first metacarpal with an image in the head of owl. The profile remains more delicate of practice and interpretation. The most classic mechanism is the hand in pronation position, the radial edge of the thumb in light flexion resting on all its length, the ulnar edge of the hand raised in a pronation of 20 ° [1]. Despite, MRI is better for showing ligamentous incarceration [6].

The main of surgical treatment is to ensure the stability of the trapezio-metacarpal joint. This osteosynthesis can be carried out with a closed focus under fluoroscopic control [3] or preferably in the open. In case of the fracture of the trapezium, fixation of the fragment can be achieved by Herbert screws [3], or by Kirshner pins [3]. Surgical restraint is performed with closed reduction or ligamentoplasty by the dorsal approach [2, 7]. Pinning can be trapezio metacarpal or inter metacarpal.

Trapezio-metacarpal racking involves performing a temporary arthrodesis. Two techniques have been described:

- Wagner technique in 1951.
- Wiggins technique [1,7] It consists after the maneuver of reduction to penetrate a pin at the neck of the first metacarpal.

After insertion, surgical restraint is protected by a plaster cuff for 4 weeks. Stiffness, osteoarthritis and arthritis are more theoretical than real complications [1].

Iselin's technique makes it possible to protect the commissural opening [1]. The compression screwing of the trapezium seems to us the best adapted since it makes it possible to ensure an anatomical and stable reduction allowing the early rehabilitation. On the other hand, fixation of the base of the first metacarpal is more difficult since the dorsal approach only allows a return screw, but this is more stable than the racking performed by several authors [4].

However, incarceration of capsular and ligamentous lesions is an indication for dorsal osteosynthesis. The short-term results of surgical treatment of this lesional association are encouraging [2]. However, none of recent publications has a follow-up of more than ten years, hence the absence of data on the incidence of long-term rhizarthrosis in this type of trauma [3].

Conclusion

Lateralized and hyper mobile, the trapezio-metacarpal joint is more vulnerable than the carpo-metacarpal joints of the long fingers. The dislocation-metacarpal dislocation is a rare lesion and is generally associated with a Bennett fracture and / or a trapezium fracture. Surgical treatment has often given good results in our experience every time that the racking was early, even in the case of significant associated lesions. Nowadays, the evolution towards rhizarthrosis of the thumb remains imprecise but it justifies a regular follow-up of these patients.

References

1. Shimi M, El Ibrahim A, El Mrini A. (2011). Luxation carpo-métacarpienne du pouce associée à une fracture du trapèze et de Bennett. *Chirurgie de la Main*, 30(2), 130–132. <https://doi.org/10.1016/j.main.2011.01.002>
2. Kukreti S, Harrington P. (2004). Carpometacarpal joint dislocation of the thumb associated with fracture of the trapezium: a case report. *European Journal of Orthopaedic Surgery and Traumatology*, 14, 38–39. <https://doi.org/10.1007/s00590-003-0113-2>
3. Boussemane N, Kasmaoui H, Galuia F, Lazrak K, Taobane H, Moulay I. (2000). Le Fractures du trapèze. *Acta Orthopédica Belgica*, 66(2), 154–162.
4. Castellanos J, Del Monte LV. (2009). Traumatic dislocation of the trapeziometacarpal joint. *Revista española de cirugía ortopédica y traumatología*, 53(5), 317-319. [10.1016/S1988-8856\(09\)70187-7](https://doi.org/10.1016/S1988-8856(09)70187-7).
5. McCarthy CM, Awan HM. (2014). Trapeziometacarpal dislocation without fracture. *Journal of Hand Surgery*, 39(11), 2292-2293. <https://doi.org/10.1016/j.jhssa.2014.08.029>
6. Connell DA, Pike J, Koulouris G, van Wettering N, Hoy G. (2004). MR imaging of thumb carpometacarpal joint ligament injuries. *Journal of Hand Surgery*, 29(1), 46-54. [https://doi.org/10.1016/S0266-7681\(03\)00170-0](https://doi.org/10.1016/S0266-7681(03)00170-0)
7. Karaman I, Eray Gunay A, Yildirim C. (2020). Traumatic isolated dislocation of the trapezio metacarpal joint: A rare case report. *Kuwait Medical Journal*, 52(2), 207-210.

Citation: Ben Amor Y “Trapezio-Metacarpal Dislocation: A Rare Lesion: About Two Cases”. *SVOA Orthopaedics* 2:2 (2022) Pages 35-38.

Copyright: © 2022 All rights reserved by Ben Amor Y., et al. This is an open access article distributed under the Creative Commons Attribution License, which permits unrestricted use, distribution, and reproduction in any medium, provided the original work is properly cited.