

Double Femoral Artery in the Right Lower Limb of Cadaveric Specimen. Anatomical Case Report

Olatayo Segun Okeniran^{1*}, Olufemi A. Alamu², Olawale Victor Olapoju³ and Emmanuel Imoleayo Olonijaye³

¹Department of Anatomy, Faculty of Basic Medical Sciences, Mc Pherson University Nigeria

²Department of Anatomy, Faculty of Basic Medical Sciences, Ladoké Akintola University of Technology Nigeria

³Department of Nursing, Faculty of Basic Medical Sciences, Mc Pherson University Nigeria

*Corresponding Author: Olatayo Segun Okeniran, Department of Anatomy, Faculty of Basic Medical Sciences, Mc Pherson University Nigeria

Received: June 21, 2022 Published: June 30, 2022

Abstract

In a single male cadaver, an anatomical variation was found in the femoral artery of the lower limb during routine gross anatomy dissection of 200 level undergraduate student in the department of nursing Mc Pherson University Nigeria in June 2022. In the right lower limb of the cadaver, there were double femoral arteries, which appear lateral to the femoral vein. The femoral nerve runs through the psoas major muscle and then traverses laterally to the distal part of the psoas major muscle. Moreover, the medial and the lateral circumflex femoral arteries arose directly from the profunda femoral artery and wrap around the anterior, lateral side of the femur, supplying some of the muscles on the lateral aspect of the thigh with the medial circumflex femoral artery to supply the head and neck of the femur. This is a rare case report among the previously reported vessels variations seen in the human cadaveric specimen because only one femoral artery is present in every individual which arises directly from the external iliac artery. This case report will augment our knowledge in gross and surgical anatomy and physical medicine because of the role which the femoral artery plays in the lower extremities.

Keywords: double femoral artery, cadaver, external iliac, lateral circumflex and medial circumflex femoral artery,

Introduction

The femoral artery happens to be the main artery in the thigh of the lower limb region that accompanies the femoral vein, beginning as the continuation of the external iliac artery (terminal branch of the abdominal aorta). The external iliac becomes the femoral artery when it crosses under the inguinal ligament and enters the femoral triangle. In the femoral triangle, the profunda femoris artery arises from the posterolateral aspect of the femoral artery. It travels posteriorly and distally, giving off three main branches namely: Perforating branches, Lateral femoral circumflex, and medial circumflex femoral artery.

The femoral artery is anterolateral to the femoral vein in the distal adductor canal. More proximally, in the canal and the distal femoral triangle, the artery lies lateral to the vein [1]. The Obturator artery is another artery found in the thigh but at the medial side to supply the medial thigh muscles, this artery arises from the internal iliac artery not from the femoral artery [2]

Lower limb arterial variations are rare and may affect endovascular or surgical options in patients suffering from peripheral artery disease (PAD). These double variations usually involve hypoplasia or aplasia related to the femoral artery (FA) in association with the occurrence of the sciatic artery [3]

The femoral artery can be cannulated just inferior to the midpoint of the inguinal ligament. In left cardia (cardiac) angiography, a long, slender catheter is inserted into the artery and passed up the external iliac artery, common iliac artery, and aorta to the left ventricle of the heart. This same approach is used to visualize the coronary arteries in coronary arteriography [1]. Blood may also be taken from the femoral artery for blood gas analysis (the determination of oxygen and carbon dioxide concentrations and pressures with the pH of the blood by laboratory tests).

The varying vascular anatomy of the femoral artery is of the utmost importance due to its involvement in vascular, orthopedic, and plastic and reconstructive surgery [3],[4],[5]. Variations of the normal pattern of the Profunda Femoral Artery have been described in the available literature [6], [7], [8] but the presence of a double femoral artery is yet to be reported hence the reason to present this rare case of a double femoral artery, where each separate branch followed the expected arterial pattern.

Case Report

While doing the routine dissection for Nursing students in June 2022, a rare variation of the femoral artery was found in the inferior extremities of a male cadaver in the Department of Anatomy, Faculty of Basic Medical Sciences, Mc Pherson University Nigeria. The cadaveric subject was about sixty years old. Dissection was done properly in both the lower limbs; structures were observed and relevant photographs were taken.

In the right lower limb, there were two femoral arteries appear lateral to the femoral vein in the lower part of the femoral triangle with the sartorius muscle marked as the lateral border, the adductor longus appears as the medial border, and the femoral nerve which is also the contents of the triangle. But it was noticed that the two femoral artery takes their origin from the external iliac artery in the upper part of the triangle, the two femoral artery runs downward individually to give rise to the profunda artery which later bifurcates into medial and lateral circumflex femoral artery with another branch mainly known as perforating artery perforates the adductor, Magnus, to supply muscles in the medial and posterior thigh (Figure 1, 2).

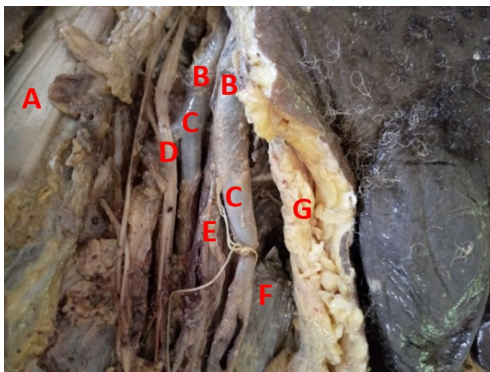


Figure 1: Right lower limb; The double femoral artery [B] gives rise to Profunda femoral artery [C], Sartorius muscle [A], Femoral nerve [D], Femoral vein [E], Adductor longus [F], Subcutaneous tissue with fat [G]

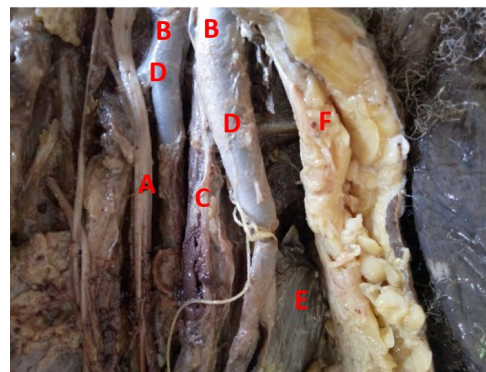


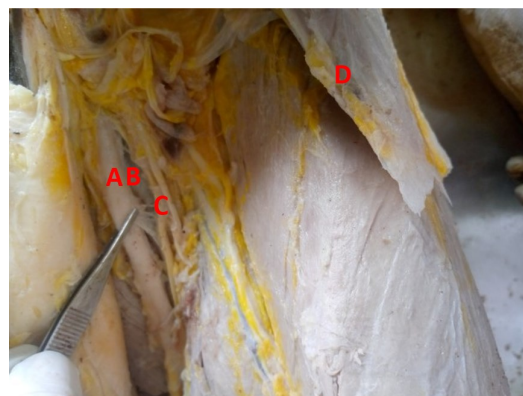Figure 2: After reflection of the sartorius muscles; The double femoral artery [B], Profunda femoral artery [D], Femoral nerve [A] Femoral vein [C] Subcutaneous tissue with fat [F], Adductor longus [E]

In the left lower limb, no such variation was found. The contents in the femoral triangle all appear normal with a single femoral artery and vein and the left-sided medial and the lateral circumflex femoral arteries arose directly from the profunda femoris artery. The medial circumflex passed medially deep to the double femoral veins and between the psoas major and pectineus muscles. The lateral circumflex passed between the divisions of the femoral nerve and posterior to the sartorius, rectus femoris muscles and Vastus lateralis to divide into ascending. The femoral vein passed medially to the femoral artery as its normal course to come to its medial side and the great saphenous veins received the posteromedial vein of the thigh and ran deep to the adductor longus muscle to drain into the medial femoral vein in the same limb) empty into it at the saphenofemoral junction. Near the apex of the femoral triangle, the femoral vein passed posteromedially to the femoral artery. Moreover, the long saphenous vein received the posteromedial vein of the thigh and ran deep to the adductor longus muscle to drain into the femoral vein in the same limb (Figure 3, 4).

Figure 3: Left lower limb; Sartorius muscle [A], Rectus femoris [B], Vastus lateralis [C]



Figure 4: Left lower limb; Femoral artery [A], Femoral vein [B], Femoral nerve [C], Reflected sartorius muscle [D]



Discussion

The femoral artery can appear double in part, or throughout its length. It may divide into two and encircle the femoral vein [9]. Although this is an uncommon case. Femoral artery variants most commonly include hypoplasia or aplasia of this artery in conjunction with a persistent sciatic artery [3]. The existence of a double femoral artery (FA) has been documented as early as the 1700s but remains an extremely rare anatomic variant with only a few prior case reports in recent decades [10], [4], [5].

Several case reports describe a single duplication that arises at the mid-segment of the FA and merges before the adductor canal [9]. Aksoy et al. reported on a case of a duplicated superficial femoral artery and popliteal artery in a 97-year-old patient [5]. Replicating within a single Femoral artery has not been reported. Furthermore, several cases described the finding of a duplicated superficial femoral artery (SFA) in patients with chronic limb-threatening ischemia (CLTI) or acute limb ischemia, the significance and natural history of a duplicated Superficial femoral artery (SFA) are unclear. [3], [5] Several cases describe the incidental finding of a duplicated SFA,[4], [9] while one case noted this anomaly in a patient with cramping pain in the leg. [11] Interestingly, it has also been noted that a duplicated SFA has been misinterpreted on ultrasound examination as collateral [3]. Given the diversity of cases, it is unknown if a duplicated SFA predisposes patients to atherosclerotic disease given the rarity of this anatomic variant unlike the aneurysmal complications associated with a persistent sciatic artery.

Moreover, Javerliat reported that collateral vessels were noted to arise around the duplicated FA and have been noted previously in the previous study, indicating that this variation can pose hemodynamic significance [9].

Interference management also remains unexplained in the setting of a duplicated SFA. Given the small diameter and unclear durability of the duplicated vessels, no endovascular intervention was performed in this case. Furthermore, A femoropopliteal bypass can be considered for this patient to avoid the duplicated system, although he sought conservative management with an exercise jurisdiction. Only one prior case reported an intervention on the duplicated vessel, which involved Fogarty catheter embolectomy for acute limb ischemia [5]. Concerning the previous reports on the femoral artery, the varying vascular anatomy of the femoral artery is of the utmost importance due to their involvement in vascular, orthopedic, and plastic and reconstructive surgery [[1],[7],[11]] concur with a case report on other vessels by [12] who reported that double femoral veins were found in 16 limbs (14.0%), among a total of 114 specimens of lower limbs, harvested from 60 adult cadavers by [6]. They concluded that it is reliable and safe to use the femoral vein as a vascular graft because of the existence of the great saphenous vein. [4].

However, during the embryonic stages of life, the sciatic artery always comes with microcirculation to the lower limb. At the onset of the eighth week of development, the sciatic artery starts to regress, Meanwhile, the femoral arteries develop as an extension of the external iliac artery [1]. Early femoral artery plexus composed of multiple networks which eventually combine and form the superficial femoral artery and profunda arteries [5].

Kim et al described a series of previously reported cases of a duplicated superficial femoral artery in 2021 and found out that duplication of the femoral artery likely arises due to the result of the failure of the multiple vascular route from the rete femoral [5]

In place of the aforementioned developmental process. The duplications of the femoral artery encountered in the present case may constitute a lack of fusion at multiple sites of the developmental vascular connections that are the precursors to the superficial femoral artery which makes this finding represents a secluded anatomic modification, as this case and others did not showcase any relationship with supplementary vascular abnormalities.

Conclusion

The present case report demonstrated the finding of a cadaveric specimen with two separate femoral arteries (FA) in the right thigh. Although it's a very rare case, recognition of a double FA is important to avoid difficulties and complications that may pose during open or endovascular procedures. Further reports are needed to describe the scenery associated with this rare anatomic variant.

Acknowledgment

We express our gratitude to Dr. Ishola, Head of the Department of Nursing, Mc Pherson University Seriki Sotayo Ogun state Nigeria, for her earnest support to complete the formalities of this case report. We are also grateful to all the members of the Department of Nursing and Mr. Adedeji for the picture editing.

Conflict of Interest

The authors declare no conflict of interest.

References

1. A. M. R. Moore, Keith L / Dalley, Arthur F / Agur, *Anatomia Orientada Para a Clínica - Moore 8^aed.* 2018.
2. A. M. R. A. Keith L. Moore, Arthur F. Dalley, "Clinically Oriented Anatomy - Keith L. Moore, Arthur F. Dalley, A. M. R. Agur - Google Books," *Clinically Oriented Anatomy*, 2013.
3. Javerliat, A. Rouanet, T. Bourguignon, A. Long, and P. Lermusiaux, "Duplication of Superficial Femoral Artery: An Uncommon Variation of the Lower Limb Arterial System," *Ann. Vasc. Surg.*, vol. 24, no. 3, pp. 415.e1-415.e3, 2010, doi: 10.1016/j.avsg.2009.09.010.
4. S. H. Yu, J. H. Hwang, J. H. Kim, S. Park, K. H. Lee, and S. T. Choi, "Duplication of superficial femoral artery: Imaging findings and literature review," *BMC Med. Imaging*, vol. 20, no. 1, pp. 1-4, 2020, doi: 10.1186/s12880-020-00500-4.
5. T. I. Kim, C. I. O. Chara, R. J. Guzman, and U. M. Fischer, "Multiple duplications of the superficial femoral artery – Case report and review of the literature," *Vascular*, vol. 29, no. 1, pp. 116-118, 2021, doi: 10.1177/1708538120943317.
6. G. Tsoucalas, E. Panagouli, A. Fiska, T. Troupis, and D. Venieratos, "A rare double profunda femoris artery in a female cadaver," *Anat. Cell Biol.*, vol. 51, no. 3, p. 212, 2018, doi: 10.5115/acb.2018.51.3.212.
7. G. Tzouma, N. A. Kopanakis, G. Tsakotos, P. N. Skandalakis, and D. Filippou, "Anatomic Variations of the Deep Femoral Artery and Its Branches: Clinical Implications on Anterolateral Thigh Harvesting," *Cureus*, vol. 12, no. 4, 2020, doi: 10.7759/cureus.7867.
8. M. Üzel, E. Tanyeli, and M. Yildirim, "An anatomical study of the origins of the lateral circumflex femoral artery in the Turkish population," *Folia Morphol. (Warsz.)*, vol. 67, no. 4, pp. 226-230, 2008.
9. S. Hapugoda, C. C.-T. Hsu, G. N. C. Kwan, T. W. Watkins, and J. A. Rophael, "Duplication of the superficial femoral artery: comprehensive review of imaging literature and insight into embryology," *Acta Radiol. Open*, vol. 5, no. 7, p. 205846011665909, 2016, doi: 10.1177/2058460116659098.
10. B. H. Jong and Y. Soga, "Double-Helix Stenting in 1 Superficial Femoral Artery," *JACC Cardiovasc. Interv.*, 2018, doi: 10.1016/j.jcin.2018.03.043.
11. T. Rastegar *et al.*, "A Case Report Study of Axillary Artery Variation in Iranian Female Cadaver," *J Morphol Anat*, vol. 1004, no. 112, p. 2, 2018.
12. C. SAMANTA, M. BANERJEE, S. SANGRAM, and S. MAJUMDAR, "Double femoral veins and other variations in the lower limbs of a single cadaver," *Int. J. Anat. Var.*, vol. 9, no. 1, pp. 25-28, 2016.

Citation: Okeniran OS, Alamu OA, Olapoju OV, Olonijaye EI. "Double Femoral Artery in the Right Lower Limb of Cadaveric Specimen. Anatomical Case Report" *SVOA Orthopaedics* 2022, 2:3, 73-76.

Copyright: © 2022 All rights reserved by Okeniran OS., et al. This is an open access article distributed under the Creative Commons Attribution License, which permits unrestricted use, distribution, and reproduction in any medium, provided the original work is properly cited.