

Sub Axial C-Spine Trauma; A Diagnostic and Treatment Challenge for Clinicians: Current Concepts

Javeria Junaid^{1*}, Saddam Mazar Baloch¹, Shahbaz Panhwar¹, M Sohail Rafi¹ and Imtiaz A Hashmi¹

¹Ziauddin University Hospital, Karachi, Pakistan.

*Corresponding Author: Javeria Junaid, Ziauddin University Hospital, Karachi, Pakistan.

Received: April 27, 2022 Published: June 30, 2022

Abstract

Cervical spine trauma is a challenging subject and its treatment has potentially life or limb threatening implications. This makes it a relevant field of study for all orthopedic, neurosurgery and emergency medicine clinicians. In the setting of significantly high energy trauma with cervical spine injuries, it has been found that almost 50% of all injuries are located between C5 and C7 segments. This review presents recommendations of imaging modalities for diagnosis and a comprehensive evaluation of current literature with updates on the latest treatment protocols. It also includes our experience as a tertiary care hospital as well as a spine center.

Keywords: C-Spine Trauma, Subaxial Injury Classification (SLIC), progressive neurological deficit

Introduction

Orthopedic emergencies include life and limb threatening trauma, sub axial trauma is a modality that can present with both.

Sub axial cervical spine consists of cervical spinal levels from C3 to C7. The incidence of trauma to this region is increasing with more high energy accidents. In this location of the spine, 44% to 62% of all injuries are found between the locality of C5 and C7 segments. (1)

Catastrophic events are associated with trauma to this region, these may include, respiratory and swallowing abnormalities, quadriplegia and severe permanent disability. (2) This is due to the inherent instability found as loss of bony and ligamentous architecture occurs during severe trauma. White and Punjabi 1987 described spinal instability as the loss of the spine's ability under physiological loads, to be able to maintain its normal patterns of displacement so as to avoid additional neurological deficit and incapacitating deformity or intractable pain. (3)

In the setting of trauma all patients after hemodynamic stabilization should be screened for C-spine injury. Two international recommendations are followed in this regard, are the nexus (4) Criteria and the Canadian C Spine Rule 2003 (5), these large multicenter studies on 8283 patients showed that for patients with trauma in a stable condition the Canadian C-spine rule is superior to the nexus criteria with respect to sensitivity and specificity (5) C spine injury should be suspected in any patient who does not have a Glasgow Coma Scale (GCS) of 15 x 15 at arrival in emergency department and the neck should then be stabilized with a spine board or a rigid Philadelphia(R) collar. Patients with any high risk factors such as age above 65, any evidence of neurological deficit, or paresthesia in the extremities or a dangerous mechanism of trauma, should undergo imaging for cervical spine trauma.

Imaging Modalities

Traditionally standard radiographic views which include anterior posterior lateral and open mouth views are used to evaluate the cervical spine from cranio-cervical junction to dorsal spine (D1). Clear visualization of the cervicothoracic junction is paramount as fracture of C7 or a fracture dislocation of C7/T1 accounts for nearly 17% of cervical spine injuries in the trauma setting. (6)

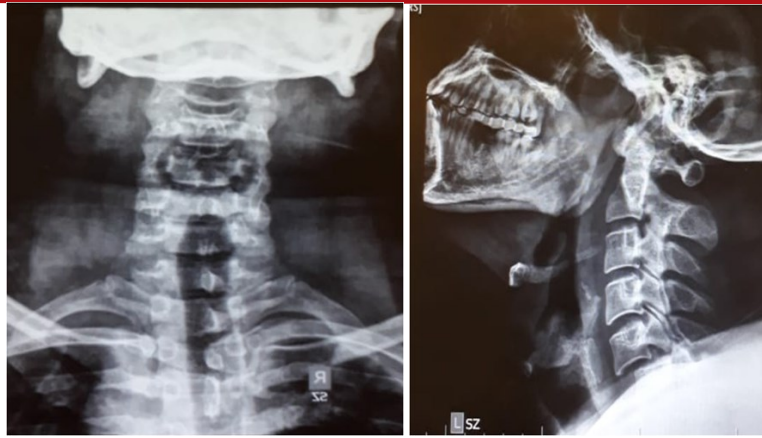


Figure 1: Anteroposterior X-ray views of C spine showing C5-C6 jump

CT scan screening for cervical injuries provides high sensitivity for injury detection as multiplanar CT scans have been found to be 99% sensitive and 100% specific (7)

Despite advantages and advances in imaging a thorough clinical assessment of the patient still remains a critical part of the evaluation for a trauma patient with a suspected C spine injury.

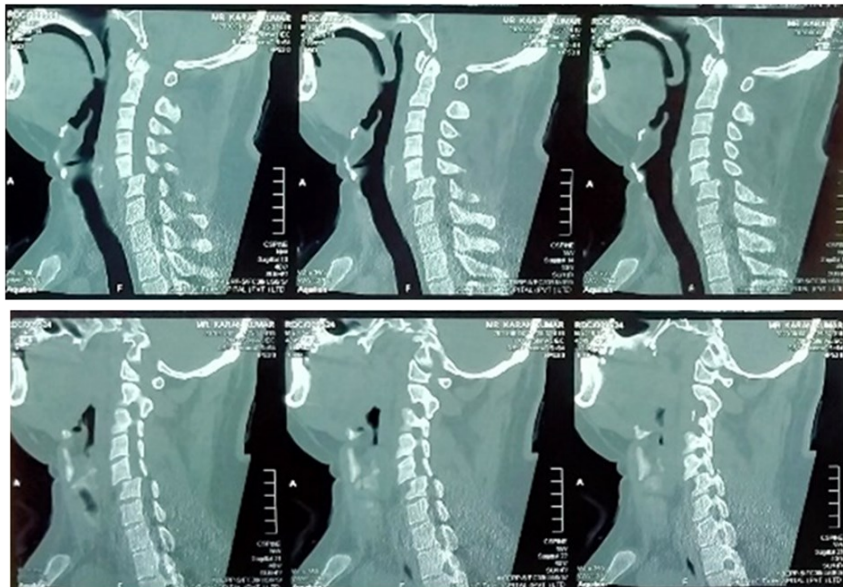


Figure 2: CT images corresponding to findings in fig 1

Magnetic Resonance Imaging is used in patients with cervical translation or destructive injuries once these have been identified on xrays/CT. MRI is used to identify ventral and dorsal compressive lesions that may be critical for determining the surgical approach. MRI has traditionally been used to assess the status of the disk or disco ligamentous complex (DLC). MR may additionally be used in the evaluation of soft tissue injuries and diagnosis of haematoma especially in neurologically injured patients with normal CT scan findings. (8)

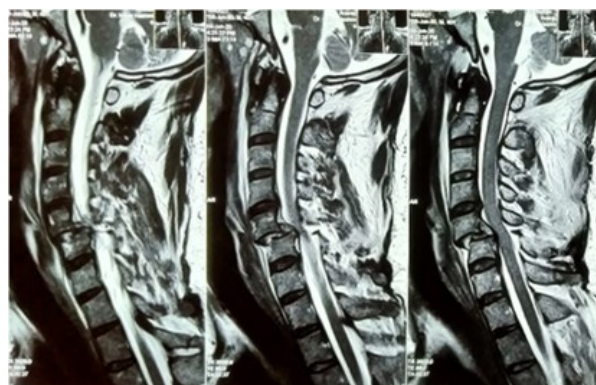

Figure 3: MRI findings for evaluation of the posterior structures and C5-C6 disc complex corresponding to the injury in fig 1 and fig 2

Classification

Many classification systems are in use for sub axial injuries, Nicoll et al (9) which is based on functional outcomes, Holsworth et al (10), Denis (11) based on the integrity of the PLC integrity, White and Punjabi (12) based on neurological and radiology findings, Allen et al (13) based on mechanism of injury, AO spine classification (14), and the Cervical Spine Injury Severity Score (15) have all been used in the past.

With the availability of so many different classifications, a need for a practical classification encompassing all the aspects of sub axial spinal injuries was required, this led to the Spine Trauma Study Group to develop a sub axial cervical spine injury classification SLIC (16) which is based on the four components of the injury which include, injury mechanism, morphology of the fracture and integrity of the posterior ligamentous complex, and neurological status of the patient. (17) This classification can also used to determine treatment modalities as discussed below. This is why it is the preferred method of classification at our set up.

SLIC Categories	Score
Morphology	
No abnormality	0
Compression	1
Burst	2
Distraction	3
Translation or rotation	4
Discoligamentous Complex	
Intact	0
Indeterminate	1
Disrupted	2
Neurologic Status	
Intact	0
Root injury	1
Complete cord injury	2
Incomplete cord injury	3
Incomplete cord injury with ongoing cord compression	4

SLIC Score	Management
3 or less	Non-surgical
4	Indeterminate
5 or more	Surgical

Injuries with an SLIC score of four or less are managed conservatively, fractures with a score of six or more are operated and injuries with a score of five maybe managed either surgically or nonoperatively at the surgeon’s discretion.

Treatment

Treatment in the emergency room starts with clinical stabilization following standard trauma protocols. The patient should be maintained in supine position with a rigid collar and lateral immobilization.

Methylprednisolone for spinal-cord injuries is controversial, as National Acute Spinal Cord Injuries Studies trials (NASCIS) I, II and III did not show any significant difference in motor, sensory, or functional outcomes in patients given Steroids. However post hoc analysis demonstrated that early administration of high dose methylprednisolone within eight hours of injury may provide significant recovery, in the setting of an acute cervical spine injury this should be considered when the potential risks are balanced with the potentially limited benefits of steroid use. (18)

Closed reduction with traction is an important part of early treatment, reduction can simplify surgical treatment as well as provide prompt decompression of neural tissues in neurologically impaired patients. Traction for closed reduction can be safely performed in the emergency department after patient admission to a definitive hospital bed or ICU. Usually, the weight necessary for this is 2.5 kgs per level of injury. This is to be performed in neutral flexion or extension position according to injury characteristics. Close clinical and radiological observations are mandatory hourly, in patients undergoing cyclical traction until definitive surgical stabilization is possible.

Injuries with SLIC score of less than three and sometimes four points are treated nonsurgically, they are generally stable injuries and do not need a cervical arthrosis, however a cervical collar may help in healing soft tissues and in the management of acute pain. There are no evidence-based guidelines available and generally patients are prescribed a rigid cervical collar for 6 to 12 weeks when stable fractures are present.

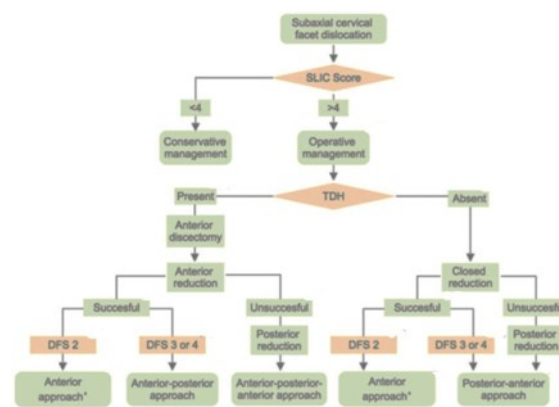
Surgical treatment for fractures deemed unstable or having the potential for neurological compromise in a patient who is fit for surgery should be treated with early operated intervention. Studies have demonstrated that early decompression is associated with an improved outcome, Surgical Timing in Acute Spinal Cord Injury Study (STASCIS) was a multicenter international prospective cohort study with patients aged from 16 to 80 with a C spine injury. Early surgery (<24 hours after injury) was performed in 182 patients and 131 patients underwent late surgery (48.3 ± 29.3 hours) In 19.8% of the patients in the early group, there was a ≥ 2 grade improvement in ASIA score and it was concluded that early decompression is a safe practice and is associated with improvement in neurologic outcome in C spine injuries (19)

Surgical intervention can be provided either through anterior or posterior approach or a combined, anterior posterior and anterior approach. This should be based on the pathology of the injury determined by the radiological and clinical assessment of the trauma patient.

Approach to the spine is based on the needs of cervical decompression, reconstruction and/or stabilization. Anterior approach has the advantage of having a patient in a supine position with minimal surgical trauma and allows decompression of the neural elements (20) one is also able to remove the ventral compressor structures from this approach.

Posterior approach is a good alternative for distraction translation injuries as reduction forces can be directly applied to realign the spine in this injury mechanism Brodke et al (21) evaluated the results of 52 patients with reduced and unstable spines and reported no significant differences in neurological recovery or long-term complications with regards to the approach chosen. Kwan et al performed a prospective randomized study for uni lateral facet injuries in 42 patients (22) there were no reported differences in patient outcome measures concluding what approach was appropriate to treat unilateral facet injuries.

For bilateral facet injuries with intact neurology, treatment again ranges from traction with cervical tongs application all the way till definitive surgery. For management protocols it is essential to evaluate the integrity of the cervical discs and the posterior longitudinal ligament (PLL). Traction with increasing weights is still the mainstay of treatment when there is no MRI available to assess cervical discs and the PLL. Recently advancements in treatment protocols recommend the following algorithm by Ozoner et al (23). This shows that an anterior posterior anterior approach is a good option in bilateral facet injuries with intact neurology, Ozoner et al in 2020 (23). This approach comes with its own technical challenges as the patient needs to be positioned twice while on the operating table this can potentially further harm an already contused cervical spinal cord and may potentially lead to further damage. Another RCT study of 52 cases of bilateral facet fracture dislocations (24) using this approach saw significant improvement in neurological status in patients despite its technical challenges.



SLIC: Sub axial Cervical Spine Injury Classification, TDH: Traumatic disc herniations, DFS: Distractive flexion stage Ozoner et al (23)

Conclusion

In conclusion The WFNS Spine Committee Recommendations from 2020 state the following Consensus (24).

- Subaxial Injury Classification (SLIC) system is safe and effective in guiding the treatment of subaxial cervical spine injury. There is a good agreement rate (> 90%) in the SLIC score (morphology, neurology, and DLC) and the treatment chosen.
- To achieve a more precise classification of subaxial fractures, we suggest the use of MRI as well.
- SLICS is easy for surgeons and residents to reproduce with relatively better interobserver reliability.

- SLICS should be used as the standard of care to guide further treatment and given preference over other present classification.
- For injuries with a SLIC score of less than 3, nonsurgical treatment with a rigid collar for 6 to 12 weeks is recommended.
- For injuries with a SLIC score of more than 4, early surgery is recommended.
- Surgery is indicated for the presence of progressive neurological deficit or stable incomplete deficit with significant spinal canal compromise.
- Anterior surgeries are recommended for significant anterior column injuries.
- Additional posterior surgeries should be considered for patients who require multilevel corpectomy, and for patients with severe dissociation (complex) injuries.
- Although posterior surgeries are suggested for patients with osteoporosis and ankylosing spondylitis, there is no consensus on that.
- In the management of locked facets, if a posterior approach is considered, preoperative MRI is recommended. (24)

References

1. Feuchtbaum E, Buchowski J, Zebala L. Subaxial cervical spine trauma. *Curr Rev Musculoskelet Med*. 2016;9(4):496–504. doi:10.1007/s12178-016-9377-0
2. White 3rd AA, Panjabi MM. Update on the evaluation of instability of the lower cervical spine. *Instructional course lectures*. 1987 Jan 1;36:513-20.
3. Ghelichkhani P, Shahsavarinia K, Gharekhani A, Taghizadieh A, Baratloo A, Fattah FH, Abbasi N, Gubari MI, Faridaalee G, Dinpanah H, Yekaninejad MS. Value of Canadian C-spine rule versus the NEXUS criteria in ruling out clinically important cervical spine injuries: derivation of modified Canadian C-spine rule. *La radiologia medica*. 2020 Sep 23:1-7.
4. Stiell IG, Clement CM, McKnight RD, Brison R, Schull MJ, Rowe BH, Worthington JR, Eisenhauer MA, Cass D, Greenberg G, MacPhail I. The Canadian C-spine rule versus the NEXUS low-risk criteria in patients with trauma. *New England Journal of Medicine*. 2003 Dec 25;349(26):2510-8.
5. Goldberg W, Mueller C, Panacek E, Tigges S, Hoffman JR, Mower WR, NEXUS Group. Distribution and patterns of blunt traumatic cervical spine injury. *Annals of emergency medicine*. 2001 Jul 1;38(1):17-21.
6. Bush L, Brookshire R, Roche B, Johnson A, Cole F, Karmy-Jones R, Long W, Martin MJ. Evaluation of cervical spine clearance by computed tomographic scan alone in intoxicated patients with blunt trauma. *JAMA surgery*. 2016 Sep 1;151(9):807-13.
7. McCracken B, Klineberg E, Pickard B, Wisner DH. Flexion and extension radiographic evaluation for the clearance of potential cervical spine injuries in trauma patients. *European spine journal*. 2013 Jul;22(7):1467-73.
8. van Middendorp JJ, Audigé L, Hanson B, Chapman JR, Hosman AJ. What should an ideal spinal injury classification system consist of? A methodological review and conceptual proposal for future classifications. *European spine journal*. 2010 Aug;19(8):1238-49.
9. Aarabi B, Oner C, Vaccaro AR, Schroeder GD, Akhtar-Danesh N. Application of AOSpine subaxial cervical spine injury classification in simple and complex cases. *Journal of orthopaedic trauma*. 2017 Sep 1;31:S24-32.
10. Moore TA, Vaccaro AR, Anderson PA. Classification of lower cervical spine injuries. *Spine*. 2006 May 15;31(11S):S37-43.
11. Patel AA, Hurlbert RJ, Bono CM, Bessey JT, Yang N, Vaccaro AR. Classification and surgical decision making in acute subaxial cervical spine trauma. *Spine*. 2010 Oct 1;35(21S):S228-34.
12. Kanagaraju V, Yelamarthy PK, Chhabra HS, Shetty AP, Nanda A, Sangondimath GM, Das KD, Bansal ML, Mohapatra B, Patel N, Abel R. Reliability of Allen Ferguson classification versus subaxial injury classification and severity scale for subaxial cervical spine injuries: a psychometrics study. *Spinal cord*. 2019 Jan;57(1):26-32.
13. Divi SN, Schroeder GD, Oner FC, Kandziora F, Schnake KJ, Dvorak MF, Benneker LM, Chapman JR, Vaccaro AR. AOSpine—Spine Trauma Classification System: The Value of Modifiers: A Narrative Review With Commentary on Evolving Descriptive Principles. *Global spine journal*. 2019 May;9(1_suppl):77S-88S.

14. Spitnale MJ, Grabowski G. Classification in Brief: Subaxial Cervical Spine Injury Classification and Severity Score System. *Clinical Orthopaedics and Related Research*. 2020 Oct 1;478(10):2390-8.
15. Samuel S, Lin JL, Smith MM, Hartin NL, Vasili C, Ruff SJ, et al. Subaxial injury classification scoring system treatment recommendations: external agreement study based on retrospective review of 185 patients. *Spine (Phila Pa 1976)* 2015;40(3):137-42.
16. Mascarenhas D, Dreizin D, Bodanapally UK, Stein DM. Parsing the utility of CT and MRI in the subaxial cervical spine injury classification (SLIC) system: is CT SLIC enough?. *American Journal of Roentgenology*. 2016 Jun;206(6):1292-7.
17. Nesathurai S. Steroids and spinal cord injury: revisiting the NASCIS 2 and NASCIS 3 trials. *Journal of Trauma and Acute Care Surgery*. 1998 Dec 1;45(6):1088-93.
18. Fehlings MG, Vaccaro A, Wilson JR, Singh A, Cadotte DW, Harrop JS, Aarabi B, Shaffrey C, Dvorak M, Fisher C, Arnold P. Early versus delayed decompression for traumatic cervical spinal cord injury: results of the Surgical Timing in Acute Spinal Cord Injury Study (STASCIS). *PloS one*. 2012 Feb 23;7(2):e32037.
19. Furlan JC, Craven BC, Massicotte EM, Fehlings MG. Early versus delayed surgical decompression of spinal cord after traumatic cervical spinal cord injury: a cost-utility analysis. *World neurosurgery*. 2016 Apr 1;88:166-74.
20. Lawrence BD, Hilibrand AS, Brodt ED, Dettori JR, Brodke DS. Predicting the risk of adjacent segment pathology in the cervical spine: a systematic review. *Spine*. 2012 Oct 15;37:S52-64.
21. Kwon BK, Fisher CG, Boyd MC, Cobb J, Jebson H, Noonan V, Wing P, Dvorak MF. A prospective randomized controlled trial of anterior compared with posterior stabilization for unilateral facet injuries of the cervical spine. *Journal of Neurosurgery: Spine*. 2007 Jul 1;7(1):1-2.
22. Özöner B, Aydın L, Can SM, Müslüman AM, Yılmaz A. Facet Dislocation Fractures of Subaxial Cervical Spine: A Treatment Algorithm for Surgical Approach Decision. DOI: 10.4274/BMB.galenos.2020.06.26
23. Jiang X, Yao Y, Yu M, Cao Y, Yang H. Surgical treatment for subaxial cervical facet dislocations with incomplete or without neurological deficit: a prospective study of 52 cases. *Medical science monitor: international medical journal of experimental and clinical research*. 2017;23:732.
24. Sharif S, Ali MYJ, Sih IMY, Parthiban J, Alves ÓL. Subaxial Cervical Spine Injuries: WFNS Spine Committee Recommendations. *Neurospine*. 2020 Dec;17(4):737-758. doi: 10.14245/ns.2040368.184. Epub 2020 Dec 31. PMID: 33401854; PMCID: PMC7788423.

Citation: Junaid J, Baloch SM, Panhwar S, Rafi MS, Hashmi IA. "Sub Axial C-Spine Trauma; A Diagnostic and Treatment Challenge for Clinicians: Current Concepts". *SVOA Orthopaedics* 2022, 2:3, 77-82.

Copyright: © 2022 All rights reserved by Junaid J., et al. This is an open access article distributed under the Creative Commons Attribution License, which permits unrestricted use, distribution, and reproduction in any medium, provided the original work is properly cited.