

Ilizarov Distraction Osteogenesis Technique as An Alternative Method Correction for The Rare Cozen Phenomenon

Nuno Vieira da Silva^{1*}, Ana Esteves¹, Pedro Gomes¹, Cláudia Gonçalves¹, Pedro Ribeiro¹, Tiago Costa¹ and João das Dores Carvalho¹

¹Orthopaedics and Traumatology Department, Centro Hospitalar do Tâmega e Sousa, Portugal, +351255711382

*Corresponding Author: Nuno Vieira da Silva, Orthopaedics and Traumatology Department, Centro Hospitalar do Tâmega e Sousa, Portugal, +351255711382

Received: November 09, 2022 Published: November 29, 2022

Abstract

Post-traumatic tibial valgus is a rare but recognized Cozen phenomenon following proximal metaphyseal fractures in children. We report a Cozen deformity in the sequence of a tibia proximal Salter-Harris type 2 fracture due to non-ossifying fibroma local fragility. This case-based literature review study aims to recall the existence of this rare identity and propose Ilizarov distraction osteogenesis as an innovative alternative method correction. Proper limb realignment was achieved two months after the assembly of a hexapodal device for gradual correction. The proposed Ilizarov distraction osteogenesis technique showed his numerous advantages over the usual treatments hemi-epiphysiodesis and osteotomy of the proximal tibia, proving to be a reliable alternative option for Cozen phenomenon correction and representing an excellent application of the Ilizarov method.

Keywords: Cozen phenomenon; post-traumatic deformity; Ilizarov technique; distraction osteogenesis

Introduction

Post-traumatic tibial valgus is a rare but recognized Cozen phenomenon following proximal metaphyseal fractures in children usually between 3 and 6 years old. Tibial valgus can occur despite optimal initial fracture management, creating a dilemma for the Orthopaedic surgeon, faced with progressive and persistent deformity. [1,2]

There is no consensus on how long to maintain the conservative attitude of surveillance and when to opt for surgical treatment. Hemi-epiphysiodesis or osteotomy of the proximal tibia are the usual treatments according to the patients age. [3]

This case-based literature review study aims to recall the existence of this rare identity and propose Ilizarov distraction osteogenesis as an innovative alternative method correction for it.

According to the lack of existing literature, it seems to be the first time that this surgical technique has been used in this pathology so far.

Case Report

A 13-year-old boy forwarded for consultation due to a painful right knee and impaired gait. He was in the third-year follow-up period after having a tibia proximal metaphysis fracture (Salter-Harris type 2) due to non-ossifying fibroma local fragility. (Figure 1) Exam images showed an immature skeleton and a 18° valgus anatomic axis alignment (5° valgus on the contralateral lower limb) with the Center of Rotation of Angulation (CORA) located in the proximal tibia (10° angle). (Figure 2)

Results & Discussions

It was performed a double osteotomy of tibia and fibula at CORA and suprasyndesmotom level respectively (after syndesmosis screw fixation) and assembly of a hexapodal device for gradual correction. (Figure 3)

Patient was allowed to immediate weight bearing and free knee mobilization. Proper limb realignment was achieved after 2 months of Ilizarov gradual distraction osteogenesis correction close monitoring. The hexapodal device and syndesmotom screw were extracted after a total of 3 months. (Figure 4, 5)

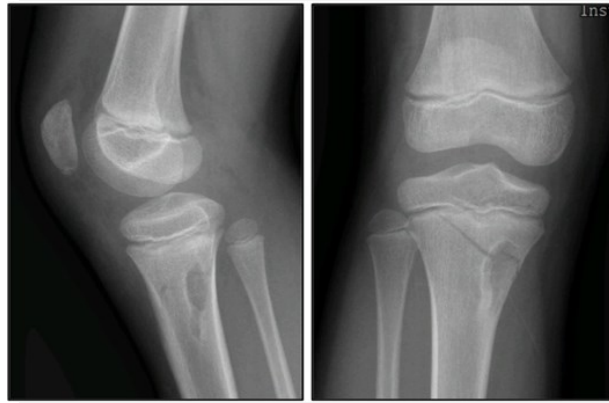

Figure 1: Tibia proximal metaphysis fracture (non-ossifying fibroma local fragility)

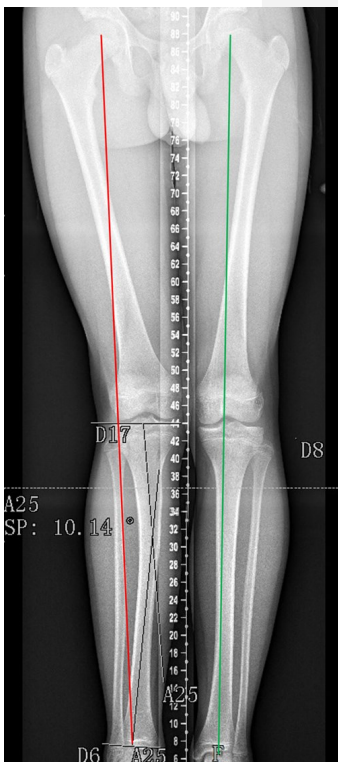


Figure 2: Lower limb alignment and CORA angle

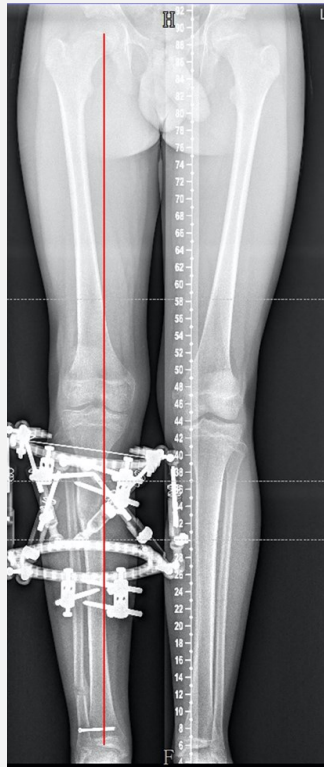


Figure 3: Hexapodal device assembly and syndesmosis fixation

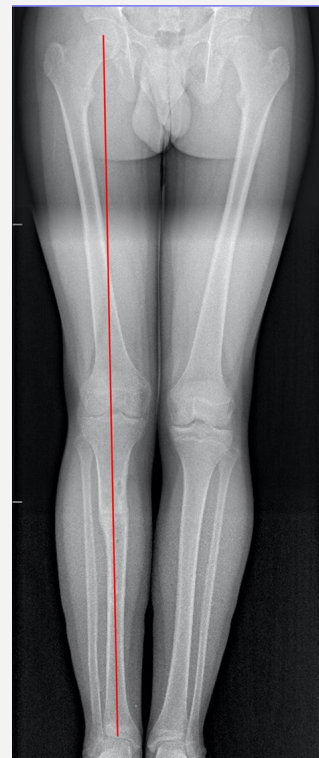

Figure 4: Final proper limb realignment (mechanical axis)

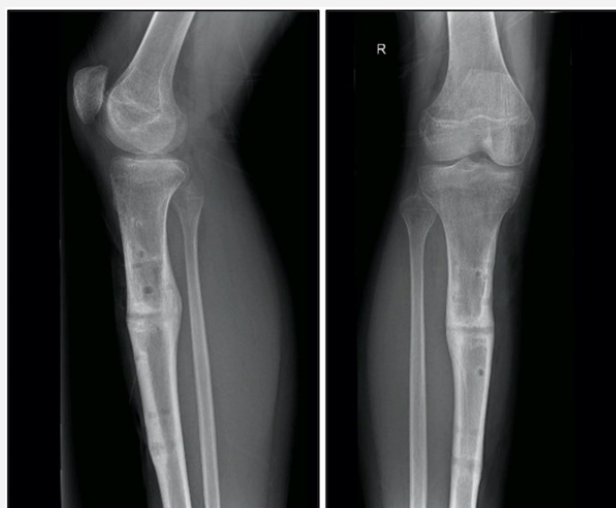

Figure 5: Final distraction osteogenesis at CORA level

At one-year follow-up, patient actually exhibits a great clinical and radiological outcome, being able to play sports without limitations.

Cozen deformity spontaneous remodeling has been reported in the first year period but this is not predictable and probably then will be a surgery decision moment. Proximal tibial osteotomies imply invasive surgery and are generally contraindicated due to the high rate of complications, including neurovascular injury, compartment syndrome and high likelihood of recurrence. Hemi-epiphysiodesis is the traditional solution and has evidence of good results but its ability to correct is more unpredictable and can only be applied if there is sufficient growth remaining. [4,5]

The proposed Ilizarov distraction osteogenesis technique has numerous advantages as reduces the complications associated with acute correction, allows immediate loading and free mobilization, corrects dysmetria and multiplanar deformities and implies less bone resection and periosteal injury, thus resulting in a better consolidation rate. Furthermore, adjustment of the correction is possible without any additional surgical intervention. However, superficial pin tract infections and device discomfort are some disadvantages of this method that should be discussed with the patient. [6,7]

Conclusion

It is important to recognize and appropriately treat this distinct deformity to prevent further instability, degenerative changes, and joint function limitation. The proposed distraction osteogenesis technique proved to be a reliable alternative option for Cozen phenomenon correction and represents an excellent application of the Ilizarov method.

Conflict of Interest

The authors declare no conflict of interest.

References

1. Yang BW, Shore BJ, Rademacher E, May C, Watkins CJ, Glotzbecker MP. Prevalence of Cozen's Phenomenon of the Proximal Tibia. *J Pediatr Orthop*. 2019;39(6):e417-e421. doi:10.1097/BPO.0000000000001354
2. Rockwood and Wilkins' fractures in children. (2020). Philadelphia: Lippincott Williams & Wilkins
3. Dorman S, Jariwala A, Campbell D. Cozen's phenomenon: a reminder. *Scott Med J*. 2013;58(3):e10-e13. doi:10.1177/0036933013496922
4. Burton A, Hennrikus W. Cozen's phenomenon revisited. *J Pediatr Orthop B*. 2016;25(6):551-555. doi:10.1097/BPB.0000000000000327
5. Morin M, Klatt J, Stevens PM. Cozen's deformity: resolved by guided growth. *Strategies Trauma Limb Reconstr*. 2018;13(2):87-93. doi:10.1007/s11751-018-0309-y
6. The Basic Principles of External Skeletal Fixation Using the Ilizarov and Other Devices. (2012). Springer Milano: Leonid Solomin.
7. Sailhan F. Bone lengthening (distraction osteogenesis): a literature review. *Osteoporos Int*. 2011;22(6):2011-2015. doi:10.1007/s00198-011-1613-2

Citation: da Silva NV, Esteves A, Gomes P, Gonçalves C, Ribeiro P, Costa T, Carvalho JDP. "Ilizarov Distraction Osteogenesis Technique as An Alternative Method Correction for The Rare Cozen Phenomenon" *SVOA Orthopaedics* 2022, 2:6, 130-132.

Copyright: © 2022 All rights reserved by da Silva NV., et al. This is an open access article distributed under the Creative Commons Attribution License, which permits unrestricted use, distribution, and reproduction in any medium, provided the original work is properly cited.