

# Multimodality IONM Case Report During Spinal Fusion

Syed Imran<sup>1\*</sup> and Cynthia Addai<sup>2</sup>

<sup>1</sup> Senior Physiologist, Neurophysiology Department, The Wellington Hospital, London, United Kingdom.

<sup>2</sup> Manager Neurophysiology Department, The Wellington Hospital, London, United Kingdom.

\***Corresponding Author:** Syed Imran, Senior Physiologist, Neurophysiology Department, The Wellington Hospital, London, United Kingdom.

DOI: <https://doi.org/10.58624/SVOAOR.2023.03.050>

**Received:** July 28, 2023 **Published:** August 14, 2023

## Abstract

Spinal surgery involves a wide spectrum of procedures during which the spinal cord, nerve roots, and key blood vessels are frequently placed at risk for injury. Neuromonitoring provides an opportunity to assess the functional integrity of susceptible neural elements during surgery. Multimodality neuromonitoring relies on the strengths of different types of neurophysiological modalities to maximize the diagnostic efficacy in regard to sensitivity and specificity in the detection of impending neural injury. Thorough knowledge of the benefits and limitations of each modality helps in optimizing the diagnostic value of intraoperative monitoring during spinal procedures. This case presentation will demonstrate the significance of multimodality IONM.

**Keywords:** Spine Surgery, Somatosensory evoked potentials, Motor evoked potentials, Spinal cord

## Introduction

The development of neurological deficit following spinal surgery is a devastating complication. Some of these complications are known to occur without any recognizable adverse event during surgery. Recently, multimodality intraoperative neurophysiological monitoring (IONM), including somatosensory-evoked potentials (SSEPs), motor-evoked potentials (MEPs), and electromyography (EMG) has been utilized and has been proven effective for preventing neurological injury during spinal surgery (1-3).

Multimodality Intraoperative Neuromonitoring (IONM) is now routinely used to provide immediate monitoring of spinal cord function. This combined approach can improve sensitivity and specificity for detecting neurological damage during spine surgeries (4).

## IONM Technique

IONM was performed by a senior clinical physiologist with CNIM certification using a 16 channel Nihon Kohden IOM constant current system. Patients underwent multimodal monitoring, recording of cortical SSEP, FEMG, TcMEP, TOF and EEG. SSEP were recorded from cortex and responses were evoked by cathodal delivery of 0.2ms duration, square-wave impulses at range of 4.1-5.1 Hz to bilateral posterior tibial nerves and median nerves using pair of adhesive electrodes. The stimulation intensity was 45mA to posterior tibial nerve and 20mA to median nerve. Cortical SSEP were recorded from corkscrew electrodes placed in scalp at CPz-CP3/CP4 (Tibial SEP derivations) and CP3/CP4-CPz (Median SEP derivations).

MEPs were recorded bilaterally as CMAP from tibialis anterior (TA) and abductor hallucis (AH) muscles in lower extremities and from abductor pollicis brevis (APB) in the upper extremities. Bilateral APB responses were used as control to differentiate between surgical and non-surgical loss of limb responses. MEPs were elicited periodically by delivering an anodal pulse train of 4-6 pulses of 0.5ms duration and ISI of 4ms at stimulus intensities of 150-200mA. The stimulating electrodes were positioned over the motor cortex at M1, M2, M3 and M4.

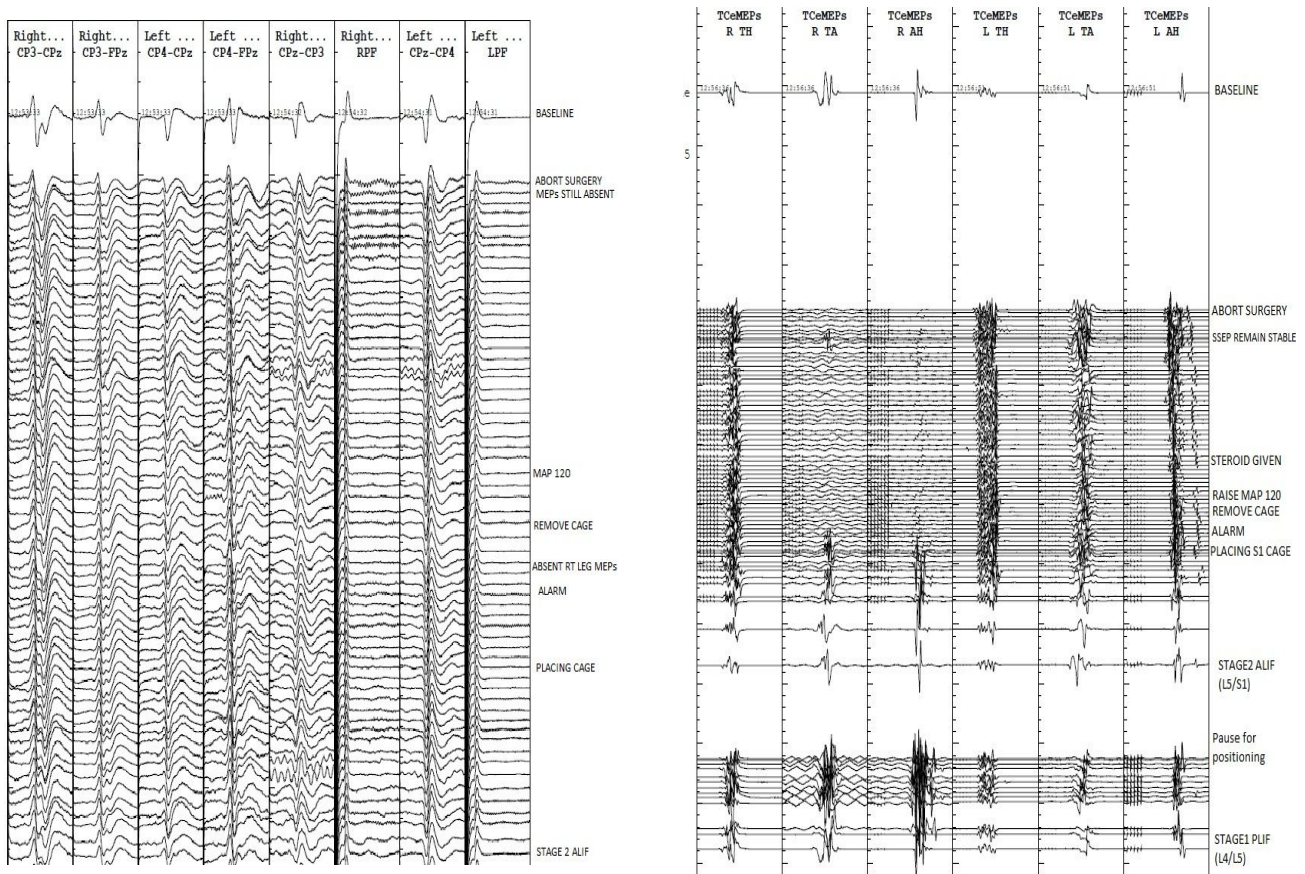
Alarm criteria was taken when (1) Cortical SSEP amplitudes drop to >50% with or without corresponding increase in latency >10% of baseline responses. (2) MEP evoked CMAP responses in any muscle were lost and remained absent. Any sudden drop in amplitude of MEP >80% of baseline trace was reported and investigated.

### First Case Report

70 years old female presented with lower back pain and walking difficulty. MRI revealed L5/S1 spondylolisthesis. Surgery was planned in two stages, Stage1= Posterior Lumbar Interbody Fusion (PLIF) & Stage2= Anterior Lumbar Interbody Fusion (ALIF). PLIF surgery consisted of posterior L4/5 decompression and instrumented fusion with the patient prone position. After the completion of stage one, the patient was moved to supine position. No complication was noticed in stage 1 procedure. During stage two, the patient underwent anterior L4-S1 Interbody cage placement.

During the placement of cage in L5/S1, the right leg MEP was completely disappeared while SSEPs remain unchanged. There was no change in left leg MEPs and bilateral upper limb control monitoring MEPs. Surgeon was alarmed and surgery was paused immediately. The mean arterial pressure (MAP) was increased to more than 90mmHg as well as stimulus parameter were changed to utilize MEPs recovery includes increase in pulse train from 4 to 6 ms, Pulse duration from 0.5sec to 0.7 sec and steroid bolus (Dexamethasone) was given. No improvement in MEP signals was noticed and surgeon decided to remove the cage, however no displacement of cage was shown in X-ray. Surgeon decided to pause the surgery until the recovery of MEP signals and then decided to abort the procedure when no MEP recovery was noticed.

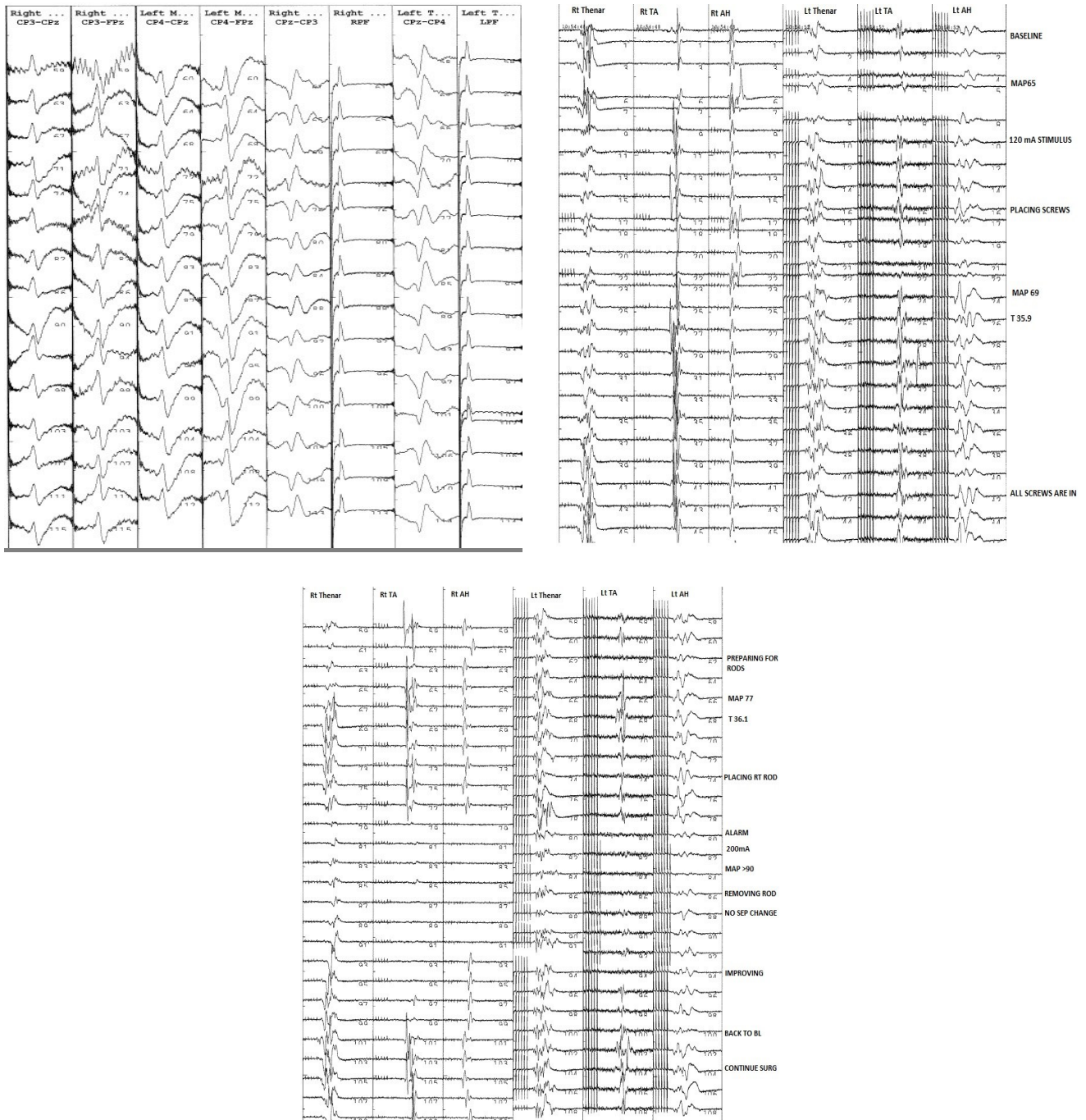
Post Op Neuro examination revealed significant weakness in right foot dorsiflexion and planter flexion, however no sensory deficit was present. Within 24 hours, patient gain full muscle strength in right foot without any neurological deficit.



**Fig 1:** Persistent MEP loss. SSEP tracings indicating no change in dorsal column of spinal cord and keeping intact, while TcMEP showed persistent TcMEP loss, status post L5/S1 cage placement.

### Second Case Report

23 years old female with idiopathic scoliosis admitted for correction and fusion at T9-L3 levels. Multimodality IONM was utilized including SSEPs, TcMEPs, FEMG, EEG and TOF monitoring. Baseline were taken prior to incision. During the rod placement in right, sudden loss of MEP signal was alarmed while no change in SSEP was noticed. Blood pressure was increased to mean >90mmHg and then rod was removed. MEPs were improved significantly and surgeon continued correction. Post Operative neurological exam did not reveal any neurological deficit.



**Fig 2:** Scoliosis surgery. Bilateral leg MEPs deterioration followed rod placement; No SSEP change. Restoration of MEP after blood pressure elevation and rod removal. Surgery was continued and all potentials were present at closure.

**Discussion**

There is a growing body of evidence supporting the effectiveness of IONM in detecting adverse outcomes during spinal surgery. A thorough appreciation of the strengths and weaknesses of each monitoring modality is critical for the optimal use of IONM. Preoperative discussion between the surgeon, anesthesiologist, and neurophysiologist is an essential component of safe IONM usage (1-2)

In this case presentation of patients undergoing deformity corrections, unilateral and bilateral changes in the transcranial MEP occurred. The unilateral changes occurred following direct trauma to the spinal cord, whereas, the bilateral changes were associated with perfusion deficits to the spinal cord. Restoring the perfusion locally through release of the traction, release of the rod, or systemically through increasing the blood pressure and/or reversing the anemia through blood transfusion, successfully addressed these changes in all patients allowing for the safe correction of the deformity and completion of the cases (3-4)



Unilateral changes associated with direct trauma to the spinal cord were relieved by reversing the causative agent and allowing time for recovery. Repeat bilateral loss of MEP signal was the result of inadequately addressing the spinal cord perfusion deficiencies prior to obtaining the desired correction.

The use of TcMEPs is sensitive and specific to change in neural function (4). TcMEPs may contribute to calling attention to the need for intraoperative corrections including widening decompressions, improving perfusion, and limiting deformity correction so that more severe neural compromise may be prevented.

An overview and update were presented by McDonald et.al (2006) describing spinal cord signal changes with potential neuronal injury / spinal cord ischemia.

## Conclusion

Multimodality IONM is recommended in procedures where there is a risk of neurological injury. The ability of IONM to detect such complications has improved, predominantly as multimodal monitoring techniques have been introduced. SSEP record specifically the ascending dorsal tract of the cord and provide no information on the integrity of the descending anterior tracts. However, Combined IONM techniques SSEPs and MEPs have good diagnostic characteristics to detect neurological injury.

## Conflict of Interest

The authors declare no conflict of interest.

## References

1. Macdonald DB, Skinner S, Shils J, Yingling C; American Society of Neurophysiological Monitoring. Intraoperative motor evoked potential monitoring - a position statement by the American Society of Neurophysiological Monitoring. *Clin Neurophysiol*. 2013 Dec;124(12):2291-316. doi: 10.1016/j.clinph.2013.07.025. Epub 2013 Sep 18. PMID: 24055297.
2. MacDonald DB. Safety of intraoperative transcranial electrical stimulation motor evoked potential monitoring. *J Clin Neurophysiol*. 2002 Oct;19(5):416-29. doi: 10.1097/00004691-200210000-00005. PMID: 12477987.
3. Quraishi NA, Lewis SJ, Kelleher MO, Sarjeant R, Rampersaud YR, Fehlings MG. Intraoperative multimodality monitoring in adult spinal deformity: analysis of a prospective series of one hundred two cases with independent evaluation. *Spine (Phila Pa 1976)*. 2009 Jun 15;34(14):1504-12. doi: 10.1097/BRS.0b013e3181a87b66. PMID: 19483667.
4. Lewis SJ, Wong IHY, Strantzas S, Holmes LM, Vreugdenhil I, Bensky H, Nielsen CJ, Zeller R, Lebel DE, de Kleuver M, Germscheid N, Alanay A, Berven S, Cheung KMC, Ito M, Polly DW, Shaffrey CI, Qiu Y, Lenke LG. Responding to Intraoperative Neuromonitoring Changes During Pediatric Coronal Spinal Deformity Surgery. *Global Spine J*. 2019 May;9(1 Suppl):15S-21S. doi: 10.1177/2192568219836993. Epub 2019 May 8. PMID: 31157143; PMCID: PMC6512195.
5. Samartzis D, Germscheid NM, Fehlings MG, Fisher CG, de Kleuver M, Öner FC, Yoon ST, Vialle LR. AOSpine Knowledge Forums: Research in Motion. *Global Spine J*. 2019 May;9(1 Suppl):5S-7S. doi: 10.1177/2192568219845647. Epub 2019 May 8. PMID: 31157147; PMCID: PMC6512198.

**Citation:** Imran S, Addai C. Multimodality IONM Case Report During Spinal Fusion. *SVOA Orthopaedics* 2023, 3:4, 98-101.

**Copyright:** © 2023 All rights reserved by Imran S. This is an open access article distributed under the Creative Commons Attribution License, which permits unrestricted use, distribution, and reproduction in any medium, provided the original work is properly cited.