

Surgical Fasciotomies for Pediatric Acute Compartment Syndrome, and Overview

Nguyen Ngoc Hung, MD^{1*}, Hoang Hai Duc, MD, PhD², Le Tuan Anh, MD², Phung Cong Sang, MD² and Nguyen Vu Hoang, MD²

¹ Hong Phat General Hospital, 219 LeDuan Street, HaiBaTrung Distric, Hanoi city, Vietnam.

² National Hospital for Pediatrics, Hanoi city Vietnam.

*Corresponding Author: Nguyen Ngoc Hung, MD, Hong Phat General Hospital, 219 LeDuan Street, HaiBaTrung Distric, Hanoi city, Vietnam.

DOI: <https://doi.org/10.58624/SVOAOR.2023.03.056>

Received: October 16, 2023 Published: November 02, 2023

Abstract

Introduction: The goal of treatment is firstly to save the patient's life and secondly to save the damaged limb. Fasciectomy is the only accepted treatment for compartment syndrome and should be performed promptly after the diagnosis is made. The results after fasciectomy are best when there is no delay in treatment.

Method: Clinically determined according to the "5 P's" and measured Intracompartmental Pressure (ICP) with $P \geq 30$ mmHg. Perform traditional Fasciotomies surgery on all patients.

Results: There were four patients; Mean age: 54 months \pm 31.749; Girl: 03; Boy: 01; Fall from height: 2; Sport trauma: 01; Pedestrian in a car accident: 01; Mean - Intracompartmental Pressure (ICP): 53.75 mmHg. The most common mechanisms of injury are pedestrians struck by motor vehicles, falls, sports, and vehicle occupants in motor vehicle crashes. Forearm fractures are the most common cause in the upper extremity, and fractures of the tibia and/or fibula are most common in the lower extremity.

Conclusions: Fractures significantly increase the risk of developing compartment syndrome in both forearm and leg fractures. The patients were transferred directly from the emergency room to the operating room, suggesting that the remaining developed compartment syndrome after admission or late diagnosis.

Keywords: Acute compartment syndrome, open forearm fracture, fasciotomy, Accident, Sport football.

Introduction

The sequelae of outpatient compartment syndrome were first described by Volkmann in 1881. His landmark paper details the ischemia of a limb that when left untreated within a few hours it will lead to paralytic contractions [1]. The prevailing theory at the time was that tight bandaging caused ischemia. Bywaters and Beall further identified compartment syndrome in a case series of World War II victims in England in 1941. Initially labeled a crush due injury to impaired renal function, the author describes a swollen limb leading to shock, weak pulse in the injured limb, risk of limb necrosis, progressive kidney failure, and ultimately death. This was further elucidated and better described by Carter et al [2] in 1949 when muscle resulted injury in increased pressure within the muscle compartment impairing the blood supply, leading to necrosis.

Compartment syndrome occurs when pressure within a specific compartment increases beyond a critical pressure threshold, thereby reducing perfusion pressure to that compartment [3]. Intracompartmental bleeding leads to increased intracompartmental pressure, which increases venous capillary pressure. Capillary collapse occurs when compartment pressure exceeds capillary perfusion pressure, leading to ischemia and cell necrosis. Interstitial edema develops due to tissue necrosis and worsens the swelling of the interstitial spaces [4].

Compartment syndrome can occur in any area of the body that has a closed compartment. The area below the knee is the area most likely to develop acute compartment syndrome, followed by the forearm, thigh, arm and Hand [5]. The specific location of the lesion is important in predicting the development of compartment syndrome. In a study evaluating their experience with compartment syndrome, Gonzalez et al [6] showed that no patient with penetrating trauma from the distal end below the knee developed compartment syndrome, whereas Twenty-seven percent of patients with penetrating proximal injuries below the knee eventually require treatment. Fasciectomy. Similarly, Meskey et al [7] demonstrated that proximal tibia and fibula fractures had a significantly higher incidence of associated compartment syndrome than medial or distal fractures. Abdominal compartment syndrome is also quite common and has been well described. Syndromes in the buttocks, arms, legs, paravertebral body, and mediastinal space may also occur and should be monitored [8].

The causes of compartment syndrome are diverse. Trauma is the most likely factor, with limb fractures leading to the largest number of cases of compartment syndrome [9]. Among trauma patients, the incidence of compartment syndrome varies by mechanism. In the largest single center review, Branco and evaluated trauma patients who developed compartment syndrome in terms of both mechanism and type of injury. Gunshot wounds, followed by stab wounds, motor vehicle collisions, and pedestrians being hit by cars are the most likely mechanisms leading to compartment syndrome [5]. Patients with combined arterial and venous injuries have a 41.8% risk of compartment syndrome, while the likelihood is 5.9% for open fractures and 2.2% for fractures. closed bones [5]. Exertion and drug overdose leading to sustained pressure in a limb are also well-documented causes of compartment syndrome. Additionally, compartment syndrome may develop in an untreated limb due to widespread systemic inflammatory response and capillary leak. Although rare, group A streptococcal infection is associated with exotoxin release and tissue swelling that can also cause compartment syndrome [4].

The objective of this study was to review our institution's experience with acute compartment syndrome in children, overviewing the etiology, pathology, and fasciectomy technique.

Patients and Methods

There were 4 children aged 3 and 8 years old who were treated from January 1990 to January 2010 at the National Children's Hospital. Four patients who developed ACS in any anatomic region were included in this retrospective study (1 male subject and 3 female subjects). The average age was 54 months (Table 1&2).

All members have confirmed consensus. The study was approved by our Institute's Ethical Review Committee and was conducted in accordance with the tenets of the Declaration of Helsinki.

Patient records were analyzed for demographic data (sex, age, length of admission, and cause of compartment syndrome), information on diagnostic procedures, interventions, and other treatment procedures (measuring tissue pressure, time from injury to fasciectomy, wound management, number of treatments. surgery until definitive closure of the fasciectomy), complications and clinical outcomes. Intracompartmental pressure (ICP) measurements were performed invasively using a Stryker® S.T.I.C. Pressure monitoring system (Stryker Corporation, Kalamazoo, MI, USA). Median follow-up was 39 months (range: 28-72 months).

Management

The first priority in treating underlying PACS is to recognize the lesions and clinical situations that may lead to the development of PACS and to avoid external sources of pressure. When initially immobilizing a limb at risk for significant swelling and PACS, noncompliant circumferential dressings should be avoided.

If a cast is applied, it should be made in two pieces and lined with cotton (as opposed to synthetic material) [10]. Peeling and separating the 0.5 cm cast has been shown to reduce pressure by 47% in the anterior compartment and 33% in the deep posterior compartment [11].

Orthopedic surgeons should be cautious when applying traction to tibial shaft fractures as this may increase stress (a plantarflexion position of 0° to 37° is protective) [11]. When monitoring a patient at high risk for developing PACS, serial clinical examination should be considered.

If there is concern that PACS is developing in a child, it is important to ensure that the patient has normal blood pressure (hypotension increases the risk by reducing perfusion pressure to tissues) and to remove any abnormalities. Any circumferential bandaging, keeping the limb at heart level (significant elevation reduces the arteriovenous pressure gradient) and providing supplemental oxygen. These measures will increase blood flow to the limb at risk.

Diagnose

The classic signs of acute compartment syndrome include the six 'Ps': pain, paresthesia, hypothermia, pallor, paralysis and pulselessness. Pain is often the initial symptom and can cause acute compartment syndrome. All at-risk patients should have early and frequent repeated physical examinations to assess pain in the muscle compartments. Clinical diagnosis of compartment syndrome may be followed by prompt surgical decompression; however, the diagnosis is often unclear and pressure monitoring is often required. Due to its subjective nature, although unlikely, the absence of pain does not eliminate the possibility of compartment syndrome. Some case reports describe patients with acute compartment syndrome who never experienced pain [12]. Paralysis, pulselessness, and paresthesia appear late in the disease process, often after irreversible nerve and muscle damage, and should not be included in the routine diagnostic criteria for acute compartment syndrome.

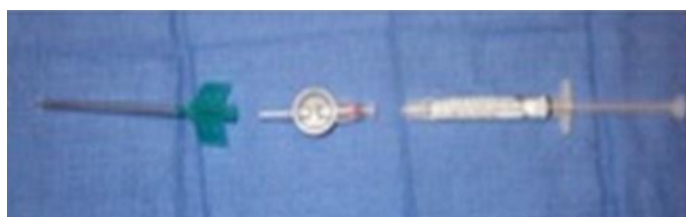Traditionally, intramuscular compartment pressure >30 mm Hg has been used as the diagnostic threshold for diagnosing compartment syndrome, although the absolute pressure value remains controversial. However, the accuracy of using single-compartment pressure data points remains questionable.

Tissue perfusion pressure, or delta pressure, calculated as diastolic blood pressure minus compartment pressure, has been studied as an alternative trigger for compartment release. Because this value takes into account each patient's dynamic blood pressure, it is considered a more accurate value for diagnostic use. In a prospective study, McQueen et al examined the use of differential pressure as a diagnostic criterion for acute compartment syndrome. They showed that there were no missed diagnoses of compartment syndrome when perfusion pressure less than 30 mm Hg was used as the criterion for decompressive surgery.

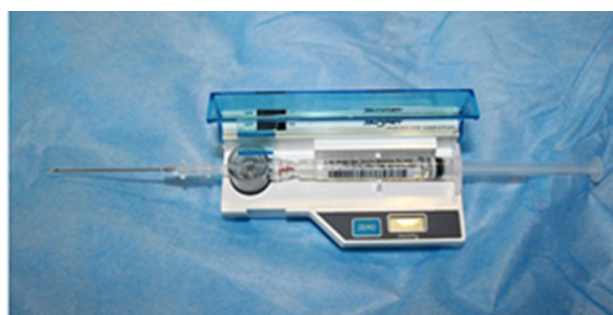Delay in the diagnosis of acute compartment syndrome can have devastating consequences for the patient. Fasciectomy performed more than 8 hours after injury carries a significantly higher risk of infection. There is no doubt that regular screening should be performed for patients at risk of compartment syndrome. To this end, several groups have advocated screening procedures. One group established a compartment syndrome screening system for high-risk trauma patients, including those with Swan-Ganz catheter-guided resuscitation, open or closed tibial fractures, injury to great vessels below the aortic bifurcation, abdominal compartment syndrome, or crush injury to the abdomen or pelvis. The procedure includes physical examination and compartment pressure, when indicated, every 4 hours for the first 48 hours. Their study showed a high incidence of acute lower extremity compartment syndrome, 20%, in the group of screened patients. Despite the high injury severity score and great resuscitation potential, no patient in the screening protocol had limb loss [13].

How to use Intracompartment Measurement Device

1. Turn monitor on, identify necessary equipment including the pre-filled-syringe of sterile normal saline, 18G needle, and tapered chamber stem (Image 1).



2. Place need firmly on the tapered chamber stem. Remove cap on pre-filled syringe and secure to the remaining chamber stem.
3. Open the monitor's cover and place the needle, stem and syringe into the unit as show in imaging 2 close cover to secure the device (Image 2)



4. Plush fluid from the syringe through the stem and needle until fluid is seen exiting the tip of the needle.
5. Hold the unit at the intended angle against the skin prior to insertion. Press the zero button and wait 2 seconds until the display reads 00.
6. Insert needle into body. Slowly inject less than 3/10 cc of saline into the compartment. Wait for the display to reach equilibrium before reading pressure. Then repeat for all compartments.

Pressure Monitoring

In adults, an accurate clinical examination leading to a certain diagnosis is often the most reliable indicator of the development of ACS. However, in PACS, many situations occur in which clinical examination does not yield a definitive diagnosis, especially with preverbal children who are confused, agitated, or drowsy; therefore, it is necessary to seek objective data when monitoring ICP. Although there are many studies to determine what value of ICP is an indication for fasciotomy, the standard of node care still exists, especially in children.

An absolute value of 30 mm Hg in any compartment is generally considered an indication for fasciotomy, whereas other sources suggest a delta P value, 20 mm Hg from diastolic blood pressure level, 30 mm Hg from Mean blood pressure is more appropriate [14].

Children have higher normal resting pressures than adults (13.3 to 16.6 mm Hg and 5.2 to 9.7 mm Hg, respectively), and children may be more sensitive to increased pressure due to lower resting blood pressure, representing fasciotomy thresholds that may be different in adults [15]. However, to our knowledge, differences in weight loss thresholds have not been demonstrated in the literature. Mars and Hadley [18] found that children were able to tolerate an absolute pressure of 0.30 mm Hg without clinical sequelae, as long as they were not within 30 mm Hg of mean blood pressure.

Two clinical situations, neonatal and vascular PACS, require special attention to ICP monitoring. Normal ICP in neonates has not been established; therefore, the usefulness of measuring ICP in neonates remains questionable.

Badawy et al [16] suggested that the decision to perform fasciotomy in infants with suspected PACS should be based on clinical decision rather than compartment pressure. PACS with a vascular cause also requires cautious use of ICP measurements. Post-ischemic muscle is much more vulnerable and rapidly damaged due to increased interstitial pressure. Basic science research by Bernot et al [17] showed that post-ischemic tissues with Pvalue delta, 40 mm Hg have metabolic changes due to hypoxia. Therefore, these vascular patients require a lower decompressive fasciotomy threshold.

Treatment

Fasciotomy / Treatment

Acute compartment syndrome is an emergency condition. Less time should be spent on confirming the diagnosis, as delay in treatment may result in limb loss.[18]

- Immediate surgical consultation
- Provide supplemental oxygen.
- Remove any casts, bandages or restrictive bandages to relieve pressure.
- Keep the limb at heart level to avoid hypoperfusion.
- Prevent hypotension and support blood pressure in hypotensive patients.
- If ICP is greater than or equal to 30 mmHg or delta pressure is less than or equal to 30 mmHg, fasciotomy should be performed.

For patients who do not meet diagnostic criteria for acute compartment syndrome but are at high risk based on history and physical examination findings, or for patients with compartment pressure between 15 and 20 mmHg, the pressure in the serial cavity should be measured. Patients with ICP between 20-30 mmHg should be hospitalized and need to consult with a surgeon. For patients with intracompartmental pressures greater than 30 mmHg or delta pressures less than 30 mmHg, fasciotomy should be performed.

Acute compartment syndrome is a surgical emergency, so prompt diagnosis and treatment are important. Once the diagnosis is confirmed, immediate fasciotomy is required to relieve intracompartmental pressure. The ideal time frame for fasciotomy is within six hours of injury, and fasciotomy should not be performed more than 36 hours after injury. As tissue pressures remain elevated over that period of time, irreversible damage may occur and fasciotomy may not be beneficial in this situation.

If necrosis occurs before a fasciectomy is performed, there is a high likelihood of infection and amputation may be required. If infection occurs, excision is necessary to prevent systemic spread or other complications.

After a fasciectomy has been performed and swelling has subsided, a skin graft is often used to close the incision. Patients must be closely monitored for complications including infection, acute renal failure, and rhabdomyolysis. [19]

Fasciotomy

Fasciectomy is an emergency procedure used to treat acute compartment syndrome. Compartment syndrome is when pressure builds up in the inelastic fascial compartment and causes ischemia leading to muscle and nerve necrosis. It occurs most commonly in the medial compartment of the forearm, the deep posterior compartment, or the anterior compartment of the leg. However, it can occur in any enclosed space where there is muscle surrounded by significant fascia, i.e. the hands, feet, thighs or buttocks. Compartment syndrome is classified as acute or chronic. Acute compartment syndrome often occurs after high-energy trauma, fractures, circumferential burns, compression injuries, or even too-tight casts. Chronic compartment syndrome develops when muscles are overused and commonly occurs in the legs of runners, soldiers, or the forearms of weightlifters and rowers. Sometimes acute exertional compartment syndrome can be seen after overexertion.

Fasciectomy is a procedure used to decompress acute compartment syndrome. Most commonly, acute compartment syndrome occurs in the legs and forearms in the setting of acute trauma. This activity highlights the precise steps needed to perform 2 common fasciectomy surgeries. A high index of suspicion is required for early detection of compartment syndrome and a low threshold for intervention by a trained health care professional is required.

Indication

The classic features of compartment syndrome are ischemia, pain disproportionate to the lesion, paresthesia, pallor, paralysis, and pain with passive movement, especially distention of the involved compartment. The two-point distinction may be useful to identify neurologic ischemia. Depending on your level of consciousness, sensory status, and ability to communicate, these signs and symptoms may be difficult to assess. In these cases, monitoring compartment pressure may be helpful.

Compartment pressure can be measured through a variety of methods, none of which has strong supporting evidence. There is no general agreement regarding the indications for emergency fasciectomy. Some institutions operate if the difference between compartment pressure and diastolic pressure is less than 20 mmHg. While some surgeons will operate if compartment pressure is greater than 30 mmHg with correlation to clinical signs [20].

Leg Fasciotomy

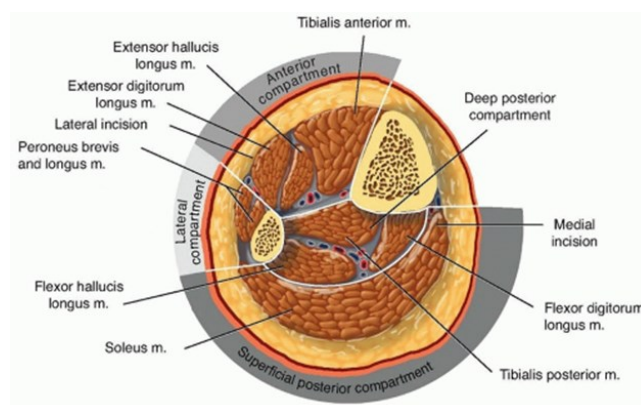


Figure 1. Anatomy of the leg and two incisions.

Single-Incision Fasciotomy of the Leg (Davey, Rorabeck, and Fowler Technique)

- Make a skin incision beginning at the lateral malleolus and extending proximally along the fibula for the full length of the compartment.
- Develop the subcutaneous plane anteriorly to expose the fascial layer. Be aware of damage to the superficial peroneal nerve at this stage.
- Make a longitudinal incision in the anterior and lateral fascial compartments.
- Develop the subcutaneous plane posteriorly and perform a longitudinal incision into the superficial posterior compartment.
- Identify the soleus in the superficial posterior compartment and begin to develop the plane between the distal third of the soleus and the lateral compartment.
- Remove the soleus and the deeper flexor hallucis longus from the posterior fibula. Be aware the peroneal neurovascular bundle will be immediately medial to the fibula.
- Retract the peroneal vessels posteriorly to expose the fascial attachment of the tibialis posterior to the fibula and make a longitudinal incision.
- Apply appropriate wound dressing.

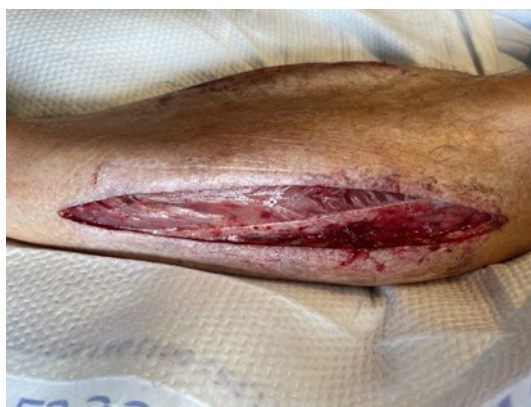

Figure 2. Single-Incision Fasciotomy of the Leg.

Double Incision Fasciotomy of the Leg (Mubarak and Harges Technique) (Figures 1&3)

- Anterolateral incision
 - Make a 20 cm anterior skin incision centered between the crest of the tibia and the fibula.
 - Identify the anterior intramuscular septum and make a longitudinal incision on either side into the anterior and lateral compartments.
- Posteromedial incision
 - Make a second skin incision starting 2 cm proximal and 2 cm superior to the medial malleolus of the tibia, extending proximally in line with the tibia longitudinally.
 - Carefully use blunt dissection to identify the fascial layer, the long saphenous vein, and the saphenous nerve; retract these anteriorly.
 - Make an incision along the length of the posterior fascial compartment.
 - Make another fascial incision over the flexor digitorum longus muscle immediately posterior and medial to the tibia to release the posterior compartment.

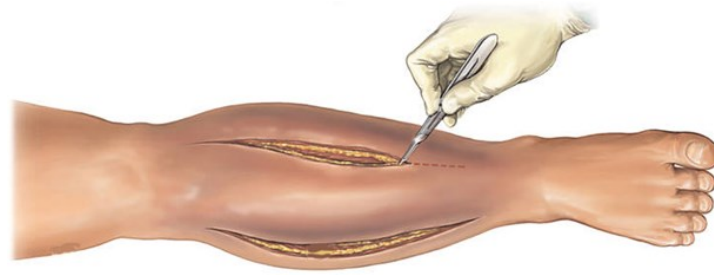


Figure 3. Double Incision Fasciotomy of the Leg.

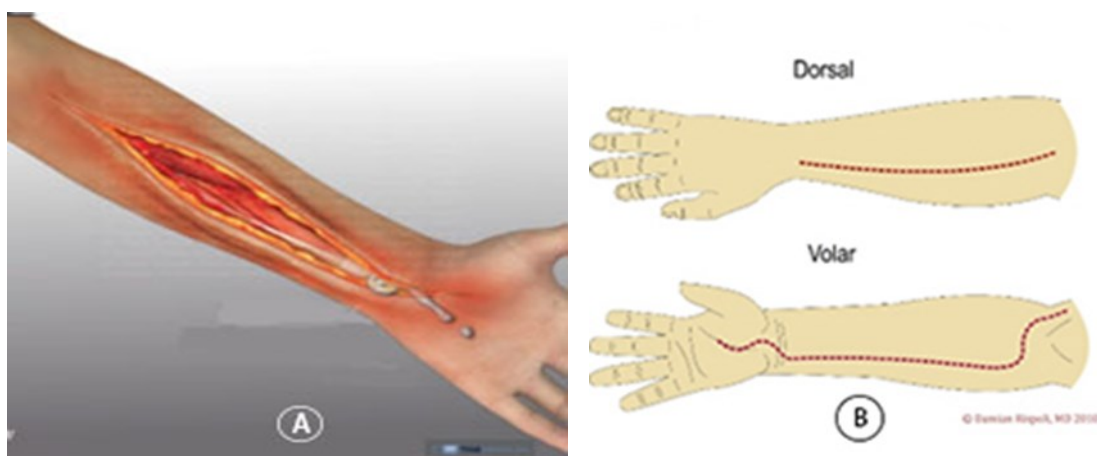Forearm Fasciotomy (Figure. 4)

• **Volar Incision**

- Make a large skin incision starting just radial to the flexor carpi ulnaris and extending proximally to the medial epicondyle.
- Extend the incision distally to the wrist crease, cross the wrist crease diagonally towards the hypothenar eminence and into the palm to facilitate a carpal tunnel release.
- Make a longitudinal incision into the superficial fascial compartment.
- Retract the flexor carpi ulnaris and the ulnar neurovascular bundle medially.
- Retract the flexor digitorum superficialis medially. This exposes the deep fascial compartment.
- Make a fascial incision onto the flexor digitorum profundus.
- Extend both fascial incisions to the transverse carpal ligament.

• **Dorsal Incision**

- Make a 10-cm incision in the skin between the extensor digitorum communis and extensor carpi radialis brevis starting 2 cm distal to the lateral epicondyle. This incision allows the release of the fascia over the mobile wad immediately.
- Develop the subcutaneous plane posteriorly to expose the extensor retinaculum and release the fascia to decompress the posterior compartment.



Figures 4 A-B. A. Volar, and B. Dorsal Forearm fasciotomies.

Hand Fasciotomy (Figures 5)

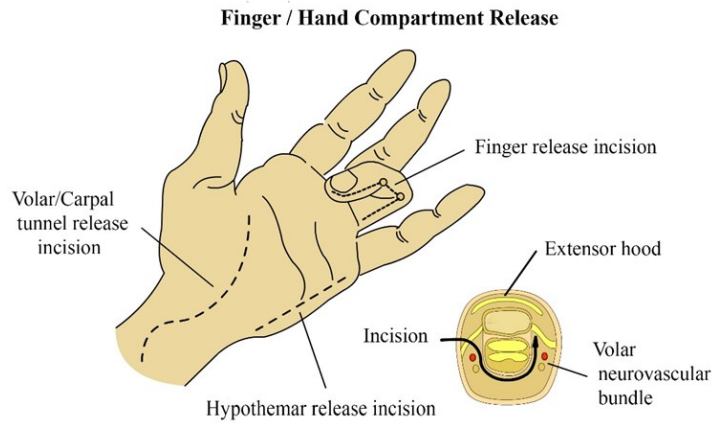
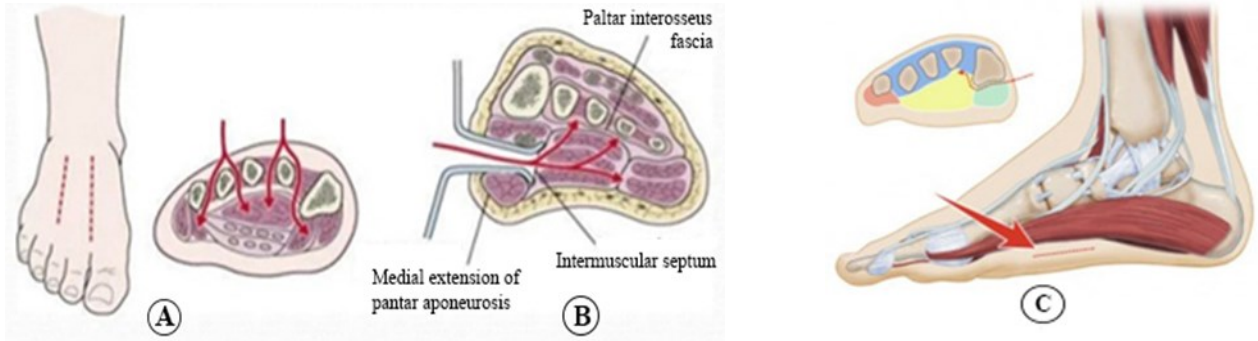


Figure 5. Hand fasciotomies

- Two longitudinal incisions over 2nd and 4th metacarpals – Palmar / dorsal interosseus
- Longitudinal incision radial side of 1st metacarpal – thenar compartment
- Longitudinal incision over ulnar side of 5th metacarpal – hypothenar compartment
- Carpal tunnel release

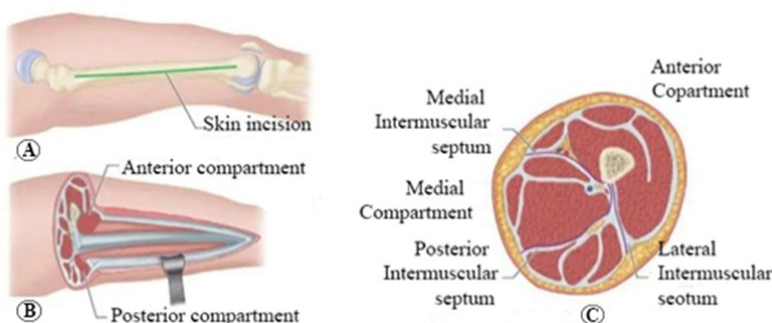
Foot Fasciotomy (Figures 6)



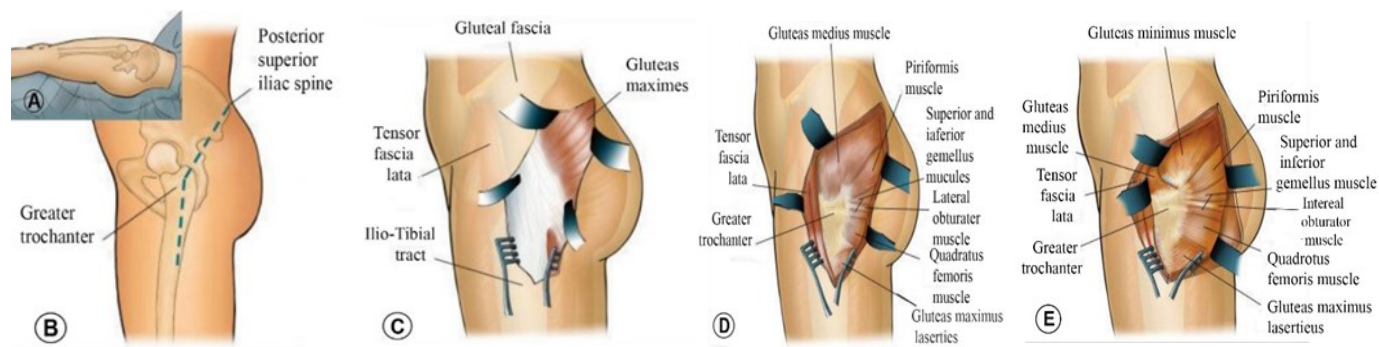
Figures 6 A-C. Foot fasciotomies. **A.** Dorsal incision overlying the second and fourth metatarsals for interosseous compartments and the central. **B-C.** Medial and lateral compartments can be accessed around the deep surfaces of the first and fifth metatarsal, respectively.

Thigh Fasciotomy (Figures 7)

Lateral skin incision – Anterior and posterior compartment



Figures 7 A-C. Decompression of thigh compartments. **A.** Incision from intertrochanteric line to lateral epicondyle. **B.** Anterior compartment is opened by incising fascia lata, and vastus lateralis is retracted medially to expose. **C.** Drawing of thigh compartment and appropriate incision.

Gluteal Fasciotomy (Figures 8)

Figures 8. Surgical fasciotomy of gluteal. A. Patient position. B. Incision. C. Expose fascialata. D. Fasciotomy and expose gluteus medius muscle. E. Expose some muscles.

The gluteal region contains 3 distinct myofascial compartments at risk for development of compartment syndrome. Although rare, the most commonly cited etiology is prolonged immobilization or as a complication of intraoperative positioning. Classic symptoms including localized swelling and pain with passive stretch are common presenting symptoms and distal neurological deficits can be seen in approximately half of the patients. Best practice guidelines are based exclusively on a handful of case series and case reports available.

Postoperative Management

The damaged portion of the body is elevated approximately 18 inches above the level of the heart to improve venous and lymphatic drainage while maintaining adequate arterial blood flow. Additional injuries are managed accordingly. Patients are typically returned to the operating room 48–72 hours after the procedure. The viability of the musculature in all four compartments was reassessed and resected accordingly. The type of fasciectomy wound closure is individualized but is primarily based on the degree of residual swelling in the limb, which in turn depends largely on the severity of the injury and the severity of the associated compartment syndrome. The timing of wound closure is usually performed when no further evidence of myonecrosis can be identified. Infrequent, complete delayed closure is possible and is performed using Allgower–Donati sutures [21].

More commonly, a portion of the proximal and/or distal portion of the fasciectomy is primarily closed, and split-thickness skin grafting is necessary for the majority of wound closure. VAC was used routinely after subsequent debridements until the wound was closed. In patients requiring skin grafting, VAC is placed on the grafted skin for 3–5 days to maximize adhesion of the graft to the recipient bed.

Once the fasciectomy wound is closed, the limb is managed with a supervised physical therapy program to maximize ankle, hindfoot, metatarsal motion, and muscle strength. Patients with significant muscle weakness in 1 compartment or more are treated with a brace to maintain a tree-like foot with active, supported, and passive range of motion of the ankle and joints of the foot. to predict muscle function recovery.

Follow-up

Management of the fasciectomy wound begins with a 48-hour examination. If the spaces are soft, this closure is achieved by primary wound closure, secondary wound healing, or split-thickness skin grafting. Approximately 50% of wounds require split-thickness grafting. Delaying the main closing is also possible.

Use a train loop eyelet stitch. The use of a negative pressure wound management device is another option.

Complications

Wound complications are as follows: [22]

- Needs skin grafting
- Scared
- Tie tendons
- Muscle hernia
- Recurrent ulcers
- Swollen limbs
- Change in sensation

- Wound discoloration
- Itchy
- Dry, scaly skin

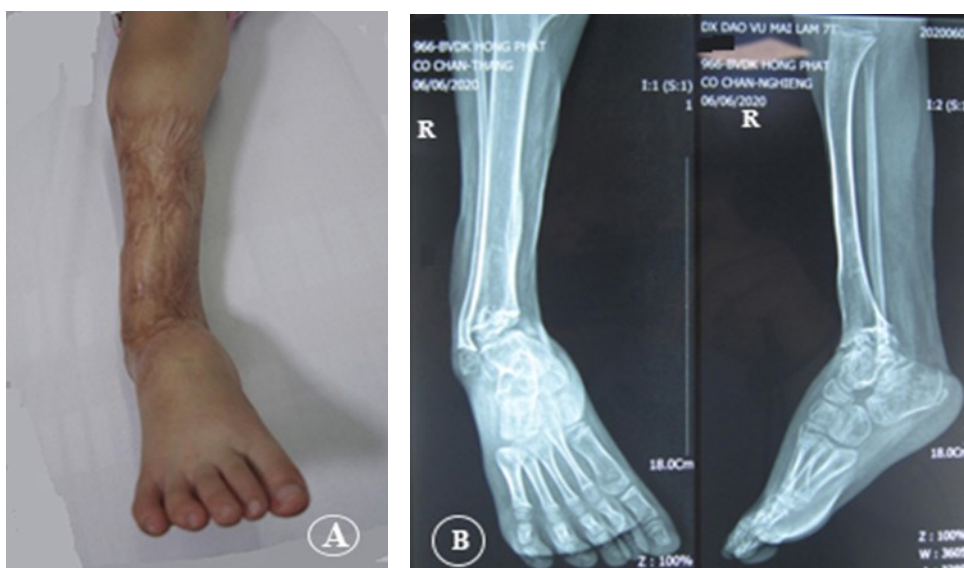Results

Patient Report

An 8-year-old boy soccer player fractured his right tibia and had to wear a cast. After 48 hours, his leg started to hurt. The pain was initially resolved with massage and ice, then his pain became more intense. That night, he couldn't walk and had to be transferred to an outside emergency department. The severe pain continued for the next 2 days and did not improve at all. On the third day of symptoms, he saw his family physician, who was concerned about compartment syndrome and sent him to our emergency department for orthopedic evaluation.

On examination, the patient had pain due to passive stretching of the anterior compartment and the legs were swollen and tense. Compartmental pressures were 39 mm Hg in the anterior compartment, 30 mm Hg in the lateral compartment, 14 mm Hg in the superficial posterior compartment, and 10 mm Hg in the deep posterior compartment.

Diastolic blood pressure is 60 mm Hg. Because of concerning test results and elevated pressures, he was taken for emergency anterior and lateral fasciectomy. In the operating room, he was found to have a gray area of muscle and significant loss of responsiveness in the tibialis anterior muscle. No hematoma was identified. His posterior cavities are soft and therefore not compressed. No muscle was excised in his first surgery, and in subsequent lavages, muscle survival improved and no myectomy was required. He underwent four surgeries to facilitate primary wound closure and delayed skin grafting. He went home on his 12th day in the hospital. At last follow-up, he remained neurologically intact, with limited mobility. Deformities adduction of foot and restriction of ankle joint movement. and X-ray image shows ankylosing talo-tibia, and Dislocation of Inferior Tibio-Fibular joint (Figures 9).



Deformities adductor foot and Restriction of ankle joint movement.

X-ray image shows ankylosing talo-tibia, and Dislocation of Inferior Tibio-Fibular joint.

Figures 9 A-B. Patient number 3. Lates result on postoperative 48 months (leg fasciotomy and skin graft). **A.** Deformities adduction of foot and restriction of ankle joint movement. and **B.** X-ray image shows ankylosing talo-tibia, and Dislocation of Inferior Tibio-Fibular joint.

Table 1. Patient's data.

No	Age (Mo)	Gender	Mechanism Of injury	Location of injury	Diagnostics	Time from Onset to Operation (h)	Type of fasciotomy	Postoperative Wound close. (n)
1	36	Girl	Fall from height	L. Hand	Clinical	15	SIF	2
2	24	Girl	Faull from bile	R. Forearm	Clinical	6	SIF	1
3	96	Boy	Sport trauma (play football)	R. Leg	Clinical	48	SIF	3
4	60	Girl	Pedestrian in a car accident	L. Leg	Clinical	18	SIF	2

SIF: Singer Intra-Fasciotomy.

Table 2. Patient's data (continuous).

	Intracompartmental Pressure (ICP)	Presenting symptom or sign (Y=yes; N= no)					
		Pain	Weakness	Paresthesia	Swelling	Pulselessness	Obtunded
1	60 mm Intraoperative	Y	Y	N	Y	N	N
2	40 mm Preoperative	Y	Y	Y	Y	Y	N
3	80 mm Preoperative	Y	Y	N	Y	Y	N
4	35 mm Intraoperative	Y	Y	N	Y	Y	N

Y: Yes; N: No

There were four patients; Mean age: 54 months \pm 31.749; Girl: 03; Boy: 01; Fall from height: 2; Sport trauma: 01; Pedestrian in a car accident: 01; Mean - Intracompartmental Pressure (ICP): 53.75 mmHg (SD \pm 20.524)

Discussion

Compartment syndrome can affect children of any age. In children <10 years of age who develop compartment syndrome, the etiology is usually due to a vascular injury or infection, while in children >14 years of age, the etiology is usually due to trauma or surgical positioning [23]. Compartment syndrome occurs more commonly in males, especially adolescent males, and is associated with a higher rate of high-energy traumatic injuries in these patients who have a larger muscle mass.

Epidemiology

PACS can have many different causes. [24] Similar to ACS in adults, the most common cause of PACS is trauma (with or without fracture). Additionally, PACS can arise due to vascular injury, surgical position (in surgery on or distal to the affected limb), overexertion, infection, neonatal phenomena, or being bitten by a snake or insect. insect bites. PACS is more common in men, especially during adolescence [24].

Although PACS affects children of all ages (average age, 8 to 12 years), cases arising from trauma, overexertion, and surgical positions occur more frequently in adolescents' older adults (age \geq 14 years), while cases arising from vascular damage and infection occur more frequently. Common in children younger than 10 years old [24].

Pathophysiology

PACS has a similar pathophysiology to adult ACS. ACS occurs when interstitial pressure increases within the closed fascial compartment, leading to microvascular damage due to changes in the arteriovenous gradient. This hypoperfusion causes tissue ischemia, leading to nerve damage and muscle death.

It has been shown that tissue damage begins after 4 hours of ischemia and can be permanent after 8 hours.

In PACS, myofascial anatomy may contribute to the development of high pressure in certain groups of children, with adolescent boys at a particularly high risk of developing PACS after exercise, trauma and surgery [24]. Some clinicians suggest that this increased risk results from a change in the ratio between rapidly growing muscle within a relatively restrictive and inelastic sheath [24].

NPTR by design collects data on the most severely injured children and adolescents because it only includes trauma victims who require hospitalization. Most pediatric patients with forearm and leg fractures do not require hospitalization. Therefore, the incidence of compartment syndrome for forearm and leg fractures is that of the most severely injured patients. In general, the incidence of compartment syndrome is lower for forearm and leg fractures. Fractures caused most compartment syndromes in this series, a result that was expected based on the source of the data. Other series have further illustrated the causes of compartment syndrome in children and adolescents. Mubarak and Carroll [25] reported 55 cases of compartment syndromes were collected at a pediatric trauma center over a 20-year period. The most common causes are femur fractures treated with skin traction, supracondylar humerus fractures, and forearm fractures. Matsen and Veith [10] reviewed 24 cases of compartment syndrome collected from several hospitals over a 10-year period. The most common causes are fractures, vascular injuries, and tibial osteotomy. Bae et al [12] reported 33 cases of compartment syndrome from a single institution and 75% were sequelae of fractures with 15% secondary to soft tissue trauma.

Compartment syndrome can be due to external causes that put pressure on the compartments or internal factors that increase the volume within the fascial envelope. These causes include casts or compression bandages, pneumatic shock suits, septic arthritis, intravenous fluids, venom, venous access, burns, intramuscular hematomas, hereditary bleeding disorders and viral diseases [12].

Advances in pediatric fracture care have reduced the incidence of compartment syndrome associated with fracture management. Previous supracondylar humerus fractures carry a risk of compartment syndrome. Immobilization of the swollen elbow in hyperflexion to maintain decreased circulation compromises, causing ischemia in the forearm. More recent trends in percutaneous stabilization have allowed immobilization to less than 90° of flexion, thereby reducing the incidence of this post-traumatic compartment syndrome [12].

Likewise, increased awareness of the pitfalls of skin traction has reduced the incidence of compartment syndrome as a result of treating femoral fractures. Bryant traction, especially in older patients, is a well-recognized cause of circulatory disorders leading to compartment syndrome or even amputation [33]. Mubarak and Carroll [25] suggested that the traction of the skin when lifting the limb onto the Bradford frame is the cause of shallow posterior compartment syndrome. The advent of modern techniques such as immediate casting and surgical stabilization explains the lower incidence of compartment syndrome due to femoral fractures in this series [12].

Compartment syndrome must be treated quickly when recognized. In early cases, treatment may require correction of extrinsic factors such as bandage removal or circumferential casting [12]. However, identified cases require emergency fasciectomy. Forty percent of the patients in this series did not come directly to the operating room from the emergency room, suggesting that the syndrome developed late or was initially unrecognized. This is similar to the findings of Royle [26], who reported that compartment syndrome developed on average 41 hours after injury. One patient developed compartment syndrome nearly 4 days after injury. Bae et al [12] reported that compartment syndrome occurs at different times after injury. Decompression surgery was performed an average of 30 hours after injury, although the longest delays were in patients with causes other than fractures. For this reason, one must be vigilant in re-evaluating trauma patients after hospitalization. Six patients in this study did not have fasciectomy to reduce compartment pressure but were probably followed clinically for improvement. Once the diagnosis is confirmed or strongly suspected, prompt surgical decompression should be performed.

Measurement of compartment pressure can be performed with a slit catheter, a wick catheter, a needle manometer, an electronic pressure transducer (arterial line), or a catheter in a solid-state transducer compartment. The threshold required for fasciectomy is controversial. Mars and Hadley [27] felt they could safely observe children and adolescents with pressures more than 30 mm Hg below mean arterial pressure using a commercial intracavitary measuring device. Royle used an intracompartmental pressure of 40 mm Hg as the threshold for fasciectomy. Others have used pressures within 20 mm Hg above diastolic blood pressure to indicate fasciectomy. The fixed value for diagnosing compartment syndrome is higher used in unconscious patients. In the awake patient with a reliable examination, the entire clinical picture including compartment pressures must be considered to determine whether fasciectomy is necessary.

Some believe that hypotension plays an important role in the development of compartment syndrome. Decreased perfusion pressure due to hypotension lowers the threshold at which elevated compartment pressures can lead to ischemia. Hypotension does not appear to play a role in this cohort.

No patient had hypotension on admission, but we cannot rule out the possibility that post-hospital hypotension played a role in the development of late compartment syndrome cases.

Compartment syndrome in pediatric trauma patients is more common in boys. Fractures of the leg and forearm are the most common cause, with open wounds having a significantly increased risk. Because many cases of compartment syndrome develop late, continued careful evaluation after hospitalization is required.

Etiology

Trauma is the cause of the majority of cases of compartment syndrome. Although all children with fractures should be monitored for signs and symptoms of compartment syndrome, certain injuries carry a higher risk of compartment syndrome.

Supracondylar humeral Fracture.

Compartment syndrome may develop in 0.1% to 0.3% of children with supracondylar humerus fractures (Battaglia, 2002. [28.]) (Ramachandran, 2008 [29]). Elbow casts exceeding 90 degrees and vascular damage increase the risk. Mubarak et al reported 9 cases of forearm compartment syndrome. Most are associated with elbow flexion exceeding 90 degrees after closed reduction (Mubarak, 1979 [25]). Battaglia et al measured compartment pressures in 29 children with supracondylar humerus fractures and reported highest pressures in the deep palmar compartment proximal to the fracture site. They also reported increased pressure when the elbow was bent more than 90 degrees (Battaglia, 2002 [28]). Although compartment syndrome associated with supracondylar humeral fractures is mostly seen in the medial compartment of the forearm, compartment syndrome of the mobile pad, anterior humeral compartment, and posterior humeral compartment has also been reported. in children (Diesselhort, 2014 [30]; Mai, 2011 [31]). Choi et al reported two cases of compartment syndrome in patients with avascular and poorly perfused hands. There were no cases of compartment syndrome in children with avascular but well-perfused ("pink, pulseless") hands (Choi, 2010 [32]). Recent reports indicate that the time from injury to surgery does not alter the incidence of compartment syndrome in type III supracondylar fractures (Gupta, 2004 [33]; Iyengar, 1999 [34]; Leet, 2002 [35]; Mehlman, 2001 [36]). However, most patients in these studies were neurologically intact and it should be emphasized that the authors do not recommend intentionally delaying treatment in patients with severe trauma, including bruising and Excessive swelling, sunken skin, neurological deficits, or loss of radial pulses. Compartment syndrome has been reported in patients with low-energy injuries and intact radial circuits, but with severe swelling and a median delay of 22 hours (range 6-64) before surgery (Ramachandran, 2008). . Based on available data and expert consensus, we recommend urgent or emergent treatment of children with supracondylar humeral fractures with multiple bruising and swelling, skin dimpling, neurological deficits or absent radial pulses. Patients should be closely monitored for signs of compartment syndrome before and after surgery.

Forearm fractures

Compartment syndrome is extremely rare in children with forearm fractures treated with closed manipulation and casting or splinting. However, it is more common in children with open forearm fractures and fractures treated with closed reduction and intramedullary nailing (Haasbeek, 1995 [37]; Flynn, 2011 [38]; Blackman, 2014 [39]). Prolonged manipulation of fractured bones during surgery is associated with an increased risk of compartment syndrome (Yuan, 2004 [40]). A low open reduction threshold should be used when nailing forearm fractures to avoid excessive swelling from prolonged manipulation. We recommend close monitoring of all children treated surgically for forearm fractures.

Tibia fracture

Children with tibia fractures, especially those in motor vehicle accidents, are at risk for compartment syndrome. Hope et al reported compartment syndrome in 4 (4%) of 92 children with open tibial fractures (Hope, 1992 [41]). A recent report of compartment syndrome in children found a mean delay of 20.5 hours from injury to diagnosis, which may indicate slow development of compartment syndrome in children. more difficult or difficult to diagnose (Flynn, 2011 [38]). Tibial fractures are at higher risk due to the potential injury associated with the anterior recurrent tibial artery (Pandya, 2012 [14]). We recommend close monitoring of children who present with high-grade tibial fractures or tibial tuberosity fractures. Mubarak reported 6 patients with distal tibia fractures who presented with severe pain and swelling of the ankle, decreased sensation in the first membranous space, weakness of the extensor hallucis longus and extensor toe muscles, and pain when passively flexing the toes (Mubarak, 2002 [25]). Intramuscular pressure measured more than 40 mmHg below the extensor retinaculum and less than 20 mmHg in the anterior chamber in each of these patients. All provided rapid pain relief, improved sensation and strength within 24 hours of superior extensor retinaculum release and stabilization of the fractured bone.

Femoral fracture

Compartment syndrome following a femoral fracture is uncommon. Volkmann's compartment syndrome and ischemic contracture have been reported after 90/90 spica casting for the treatment of femoral shaft fractures in children (Mubarak, 2006 [31]). The authors recommend against using a 90/90 cast for femoral fractures, advocating a technique that includes 45° hip flexion and 45° knee flexion, wrapping the torso and leg of the cast below the knee simultaneously, and avoid traction that puts pressure on the popliteal fossa.

Other and non-traumatic causes of compartment syndrome: Compartment syndrome in infants is rare and difficult to diagnose. It can be caused by a combination of low blood pressure in the newborn and birth trauma (Macer, 2006 [42]). Ragland et al reported 24 cases of neonatal compartment syndrome and the diagnosis was made within 24 hours in only 1 patient (Ragland, 2005 [43]). They describe a “focus

skin” lesion on the forearm of these patients as the only initial sign of the compartment syndrome. Late diagnosis may result in contractures and growth arrest of the involved extremity. In their series, only 1 patient had a fasciotomy within 24 hours and resulted in a good functional outcome. Function was impaired in the other 23 cases. High clinical suspicion is the key to early diagnosis and treatment for these patients.

Medical problems that cause bleeding in the compartment (liver failure, kidney failure, hemophilia, or leukemia) can cause compartment syndrome (Alioglu, 2006 [44]; Lee, 2011 [45]). Limb ischemia and subsequent reperfusion can also cause compartment syndrome. Correction of coagulation defects may be preferred to surgical treatment in these cases, although this decision should be made on a case-by-case basis (Alioglu, 2006 [44]).

Snake bites can cause compartment syndrome in children, especially if the fangs penetrate the fascia. Shaw and colleagues reported the successful use of antivenom in preventing surgical treatment in 16 of 19 patients bitten by rattlesnakes (Shaw, 2002 [46]). In their report, two patients had limited tissue resection and only one patient had fasciectomy due to compartment syndrome. The authors recommend the use of antivenom for snakebites in children to prevent compartment syndrome (Shaw, 2002 [46]).

Special considerations

While we have focused much of our attention on describing how to monitor patients at high risk of developing compartment syndrome secondary to trauma, several other groups of orthopedic patients deserve mention because of their potential develop compartment syndrome. Although compartment syndrome after total knee and hip arthroplasty is relatively rare, it has been reported in the literature. Lasanianos et al. reviewed 41 cases of compartment syndrome after arthroplasty, half from total hip arthroplasty and half from total knee arthroplasty. Although the incidence is low in arthroplasty patients, the small number of patients with acute compartment syndrome will be at high risk for delayed diagnosis because they are more likely to receive high-dose epidural analgesia than others. with trauma patients. Gluteal compartment syndrome is a potential risk after total hip replacement surgery and is often caused by body habits and prolonged lying positions. In a study of 28 patients with gluteal compartment syndrome, half had body weight involvement and 21% were found on the contralateral, “down” side of patients undergoing THA. These findings are especially common in cases of prolonged revision. Gluteal compartment syndrome has also been reported following trauma, iatrogenic vascular injury, pelvic fracture, lateral decubitus or lithotomy in the operating room, overuse or exertion, and intravenous analgesics. Epidural pain with motor blockade. Sequelae of gluteal cavity syndrome may include sciatic nerve palsy, rhabdomyolysis, and renal failure. Physical examination to diagnose gluteal compartment syndrome can be particularly difficult secondary to anatomic considerations. We therefore advocate the liberal use of internal measurements in these cases.

Compartment syndrome of the foot is most commonly seen following crush injuries, falls from heights, and motor vehicle accidents [48]. Compartment syndrome of the foot can also complicate up to 10% of calcaneal fractures. Diagnosis and treatment can be difficult and there is little consensus in the literature. A recent review article by Dodd and Le recommends urgently performing three fascial incisions at the time of diagnosis. We found that sequelae of compartment syndrome including but not limited to contractures, fibrosis, stiffness, and sensory disturbances are more commonly accepted by patients than sequelae of fasciectomy, which may include includes free tissue transfer. Regardless of treatment, we strongly believe that patients need to clearly understand the risks, benefits and sequelae of both surgical and non-surgical treatments and should be included in the decision-making process.

Neonatal

Case reports of forearm compartment syndrome in infants have appeared in the literature under a variety of names, often depending on author bias. Cantaboni and Taveggia [49] believed that this was a form of cutaneous aplasia and Lightwood [50] called it infantile scleroderma; Hensinger [51] Tsur et al. [52], Caouette-Laberge et al. [53], Leauté-Labrèze et al. [54]

Henssge and Linka [55] Perricone and Granata [56], Silfen et al. [57], Kline and Russell Moore [58], Tsujino and Hooper [59], and Cham et al [60] have recognized vascular injury and compartment syndrome as the basis for soft tissue conditions. Rombouts et al [61] reported these neurological findings and related them to compression paralysis. The total number of cases among these 13 researchers is 17. Skin lesions or open wounds are unusual findings in newborns but when found on the forearm, skin lesions may be a sign of compartment syndrome. Concomitant neonatal and tissue ischemia. The degree of presentation varies and can range from localized skin lesions to forearm swelling to distant necrosis. Skin lesions were present in most reported cases and in all of our cases, but the association between skin lesions and underlying compartment syndrome is often underappreciated and fasciectomy urgency is rarely done. Skin lesions are very obvious and are often the focus of treatment in young children. This injury, when young, usually heals with minimal treatment and has negligible long-term consequences. However, if primary compartment syndrome is not treated, it will progress to Volkmann contracture with a combination of extrinsic muscle infarction, intrinsic muscle paralysis, and loss of sensation in the hand. Treatment of terminal ischemic contractures will include salvage reconstructive procedures. Because damage occurs at such an early age, body involvement can result in altered limb development.

Iatrogenic Considerations

Orthopedic surgeons should also be aware of the potential for iatrogenic compartment syndrome. Tibial nailing is known to be associated with the development of postoperative compartment syndrome. Although manual reduction of intramedullary nailing of tibial shaft fractures causes a temporary increase in anterior compartment pressure of the lower leg during surgery, two large studies have found that the pressure will returned to baseline levels after nail insertion [62]. Based on these findings, we do not recommend intraoperative cavity measurement, but physicians should be vigilant with examination and documentation in the early postoperative period.

Another potential cause of compartment syndrome is the use of a tourniquet. Tourniquet syndrome, representing reperfusion injury, may occur if tourniquet time exceeds 120 minutes and includes pallor, swelling, and stiffness. Signs and symptoms are usually limited to 1 week and may be prevented by limiting the time spent applying the tourniquet in the operating room or resting 30 minutes after tourniquet application in long-term cases to allow for reperfusion interrupted [63].

Improper positioning of the patient in the operating room is another unfortunate cause of iatrogenic compartment syndrome. There have been case reports describing such events resulting from the use of traction tables, specifically injuries to the non-operative side due to compression on the support post and elevation leading to hypoperfusion. Compartment syndrome due to prolonged compression of the lower leg in the lateral position or of either leg in the lithotomy position has also been described in the literature. A full review of such cases is beyond the scope of this article; however, practitioners need to understand that intraoperative positioning needs to be performed with caution.

Finally, ill-fitting casts, bandages, or compression stockings can also lead to compartment syndrome in orthopedic patients [64]. To minimize risk at our facility, we use a splint or two-piece cast for all patients with significant swelling or injuries related to compartment syndrome. These examples of iatrogenic compartment syndrome are largely preventable and easily avoided by paying closer attention to proper positioning, padding, and tourniquet use. With increased awareness, we can reduce the incidence of these cases of compartment syndrome.

Close the wound

When performing the index operation, if you encounter a muscle that can no longer survive, it needs to be removed. Any questionable muscles can be re-examined at a planned second review surgery within 24 hours of the index surgery.

Many techniques can be used to close or bandage a fasciectomy wound. Immediately after fasciectomy, a wide, non-constrictive bandage should be used to allow for complete muscle relaxation, especially if continuous resuscitation is being performed. Kerlix or gauze moistened with sterile normal saline should be placed on the wound, covered with an abdominal pad, and lightly covered with additional kerlix. After the index operation, both traditional wet-to-dry dressings and tension dressings, such as the shoelace technique or vacuum-assisted closure, can be used. The goal of any fasciotomy dressing is to facilitate delayed primary wound closure.

Weaver et al examine modeled fasciotomy practice in two level one urban trauma centers. Overall, 18% of patients in their study were able to receive primary closure on their first return to the operating room, and 40% received split-thickness skin grafting. Only 3% of patients had primary closure on the second return to the operating room. Among the 38% of patients who underwent more than two wound irrigations and wound debridement's, no patient was able to delay primary wound closure.

When patients were classified into early or late fasciectomy, defined as less than or greater than 8 hours from injury to fasciectomy, the final primary closure rate was significantly higher. reported in patients undergoing early fasciectomy [65].

There is evidence that the use of vacuum-assisted wound closure dressings is associated with significantly higher rates of primary wound closure compared with traditional dressings. In contrast, Kakagia et al found that patients using vacuum-supported wound closure had significantly longer wound closure times than patients using the shoelace technique. Vacuum taping also costs significantly more than shoe lacing techniques [43]. Patients who receive split-thickness skin grafting early in treatment have a significantly shorter hospital stay than patients treated with traditional dressings. Clearly due to the lack of consensus on the data, at this time much of the decision regarding wound dressing will depend on the culture of the institution and the preferences of the individual surgeon.

Complications

Unfortunately, complications after fasciectomy are not uncommon. Nearly one-third of patients undergoing fasciectomy will experience postoperative complications: soft tissue necrosis, wound dehiscence, skin graft infection or necrosis, or the need for tissue excision. Underlying vascular injuries leading to fasciectomy are associated with significantly higher complication rates compared with patients without vascular injuries.

When Feliciano et al [66] evaluated a series of compartment syndromes leading to amputation, 75% were associated with delays in appropriate treatment.

One of the biggest pitfalls surrounding fasciectomy for compartment syndrome is missing or improper opening of a compartment. Loss of the compartment is a serious technical error because irreversible nerve and muscle damage can occur. In a study of military patients, Ritenour et al [67] showed that the need for revision fasciectomy was associated with a significantly higher rate of myonecrosis and increased mortality. four times. After surgery, patients must be examined regularly and creatine kinase (CK) levels monitored. Failure to remove CK or any other concern for missed cavity should trigger immediate re-exploration.

Rhabdomyolysis may result from muscle necrosis secondary to compartment syndrome, with ischemic cellular components spilling into the circulation. The released myoglobin can lead to acute kidney injury and kidney failure. Because the cytokine release associated with rhabdomyolysis causes inflammation, it can also promote and worsen compartment syndrome. In some cases, rhabdomyolysis is a precipitating factor in causing compartment syndrome. The reported incidence of rhabdomyolysis after acute compartment syndrome is 44.2%. Among patients with rhabdomyolysis, 14.4% to 39.1% develop acute kidney injury (AKI). Risk factors for rhabdomyolysis include the patient's use of drugs and alcohol and the presence of pulselessness in the affected limb. Among patients who developed AKI associated with traumatic compartment syndrome, the need for dialysis was high, in one series reported to be 44.4%.

Limb loss is considered the most serious complication of compartment syndrome. The reported rate of amputation after compartment syndrome is 5.7% to 12.9%. Risk factors for amputation include male gender and associated vascular injury. Delays in fasciectomy have also been associated with the need for amputation [18]. Patients who do not require amputation may still have severe disability. Up to 18.2% of patients had plantar valgus, 10.2% to 84.6% had chronic lower extremity pain, and in one series only 69.2% returned to work. Patients who reported problems with their limb appearance had significantly poorer overall quality of life than patients who did not find their fasciectomy scars to be a problem [49]. Mortality after compartment syndrome has been reported to be as high as 15% in case series, although a causal association remains unclear. In this study, one patient received skin grafting, had an adductor foot deformity, and had a subluxation of the tibiofibular joint (Figure 9).

Prognosis

The prognosis after treatment for compartment syndrome depends largely on how quickly the disease is diagnosed and treated. When fasciectomy is performed within 6 hours, limb function will recover almost 100%. After 6 hours, there may be residual nerve damage. Data show that when fasciectomy is performed within 12 hours, only two-thirds of patients have normal limb function. In very delayed cases, the limb may require amputation.

The outcome of posterior compartment syndrome of the leg is worse than that of anterior compartment syndrome of the leg because of the difficulty of performing incomplete decompression of the posterior compartment. Long-term studies of survivors show residual pain, Volkmann contracture, mild neurological deficits, and marked cosmetic defects in the affected limb. Recurrent compartment syndrome has been known to occur in athletes due to scarring. Some people may die from acute compartment syndrome. Often these cases are caused by infection, which eventually leads to sepsis and multi-organ failure. [68]

Conclusion

Diagnosing ACS in children can be difficult because cooperation is difficult. The classic symptoms of compartment syndrome (the five Ps) may not be present. Additional diagnostic tests such as invasive ICP measurements may help guide treatment. However, the entire clinical picture must be considered especially in neonates. Early weight loss is very important. In our study, patients underwent fasciectomy in a median of 27.5 hours (range: 2.5–99). Therefore, when ACS is present, the indication for fasciotomy is clear even in infants. This is a surgical emergency in which the surgeon must make rapid treatment decisions including when to perform a fasciectomy. Thanks to timely and adequate treatment in most cases, complications can be avoided.

Limitation

Limitations of this study include its retrospective design, small sample size, and lack of a comparison conservative treatment group. The lack of preoperative functional assessment is another limitation of this study. However, surgical treatment of acute compartment syndrome has improved. In future studies, it is necessary to evaluate more cases and improve objectivity by tracking changes in functional outcomes over time rather than performing a one-time assessment.

Conflict of Interest

The authors declare no conflict of interest.

References

1. König F, Richter E, Volkmann R. Die ischaemischen Muskellahmungen und Kontrakturen. *Centralblatt für Chirurgie* 1881;51:801–3.
2. Carter AB, Richards RL, Zachary RB. The anterior tibial syndrome. *Lancet* 1949;2:928–34.
3. Donaldson J, Haddad B, Khan WS. The pathophysiology, diagnosis and current management of acute compartment syndrome. *Open Orthop J* 2014;8:185–93.
4. Hargens AR, Romine JS, Sipe JC, Evans KL, Mubarak SJ, Akeson WH. Peripheral nerve-conduction block by high muscle-compartment pressure. *J Bone Joint Surg Am* 1979;61:192–200.
5. Branco BC, Inaba K, Barmparas G, Schnüriger B, Lustenberger T, Talving P, Lam L, Demetriades D. Incidence and predictors for the need for fasciotomy after extremity trauma: a 10-year review in a mature level I trauma centre. *Injury* 2011;42:1157–63.
6. Gonzalez RP, Scott W, Wright A, Phelan HA, Rodning CB. Anatomic location of penetrating lower-extremity trauma predicts compartment syndrome development. *Am J Surg* 2009;197:371–5.
7. Meskey T, Hardcastle J, O’Toole RV. Are certain fractures at increased risk for compartment syndrome after civilian ballistic injury? *J Trauma* 2011;71:1385–9.
8. Balogh ZJ, Butcher NE. Compartment syndromes from head to toe. *Crit Care Med* 2010;38(9 Suppl):S445–51.
9. McQueen MM, Gaston P, Court-Brown CM. Acute compartment syndrome. Who is at risk? *J Bone Joint Surg Br* 2000;82:200–3.
10. Roberts A, Shaw KA, Boomsma SE, Cameron CD: Effect of casting material on the cast pressure after sequential cast splitting. *J Pediatr Orthop* 2017;37(1):74–77.
11. Weiner G, Styf J, Nakhostine M, Gershuni DH: Effect of ankle position and a plaster cast on intramuscular pressure in the human leg. *J Bone Joint Surg Am* 1994;76 (10):1476–1481.
12. Badhe S, Baiju D, Elliot R, Rowles J, Calthorpe D. The ‘silent’ compartment syndrome. *Injury* 2009;40:220–2.
13. Kosir R, Moore FA, Selby JH, Cocanour CS, Kozar RA, Gonzalez EA, Todd SR. Acute lower extremity compartment syndrome (ALECS) screening protocol in critically ill trauma patients. *J Trauma* 2007;63:268–75.
14. Pandya NK, Edmonds EW, Mubarak SJ: The incidence of compartment syndrome after flexible nailing of pediatric tibial shaft fractures. *J Child Orthop* 2011;5(6): 439–447.
15. Mars M, Hadley GP: Raised compartmental pressure in children: A basis for management. *Injury* 1998;29(3): 183–185.

16. Badawy SM, Gust MJ, Liem RI, Ball MK, Gosain AK, Sharathkumar AA: Neonatal compartment syndrome associated with disseminated intravascular coagulation. *Ann Plast Surg* 2016;76(2):256-258.
17. Bernot M, Gupta R, Dobrasz J, Chance B, Heppenstall RB, Sapega A: The effect of antecedent ischemia on the tolerance of skeletal muscle to increased interstitial pressure. *J Orthop Trauma* 1996;10(8): 555-559.
18. Velmahos GC, Theodorou D, Demetriades D, Chan L, Berne TV, Asensio J, Cornwell EE, Belzberg H, Stewart BM. Complications and nonclosure rates of fasciotomy for trauma and related risk factors. *World J Surg.* 1997 Mar-Apr;21(3):247-52; discussion 253.
19. Gordon WT, Talbot M, Shero JC, Osier CJ, Johnson AE, Balsamo LH, Stockinger ZT. Acute Extremity Compartment Syndrome and the Role of Fasciotomy in Extremity War Wounds. *Mil Med.* 2018 Sep 01;183(suppl_2):108-111.
20. Whitesides TE, Haney TC, Morimoto K, Harada H. Tissue pressure measurements as a determinant for the need of fasciotomy. *Clin Orthop Relat Res.* 1975 Nov-Dec;(113):43-51.
21. Sagi HC, Papp S, Dipasquale T. The effect of suture pattern and tension on cutaneous blood flow as assessed by laser Doppler flowmetry in a pig model. *J Orthop Trauma.* 2008; 22: 171-175.
22. Fitzgerald AM, Gaston P, Wilson Y, Quaba A, McQueen MM. Long-term sequelae of fasciotomy wounds. *Br J Plast Surg.* 2000 Dec;53(8):690-3.
23. Livingston K, Glotzbecker M, Miller PE, Hresko MT, Hedequist D, Shore BJ. Pediatric nonfracture acute compartment syndrome: a review of 39 cases. *J Pediatr Orthop.* 2016;36:685-90.
24. Livingston K, Glotzbecker M, Miller PE, Hresko MT, Hedequist D, Shore BJ: Pediatric nonfracture acute compartment syndrome: A review of 39 cases. *J Pediatr Orthop* 2016;36(7):685-690.
25. Mubarak SJ, Carroll NC. Volkmann's contracture in children: aetiology and prevention. *J Bone Joint Surg* 1979;61-B:285-93.
26. Royle SG. Compartment syndrome following forearm fracture in children. *Injury* 1990;21:73-6.
27. Mars M, Hadley GP. Raised compartmental pressure in children: a basis for management. *Injury* 1998;29:183-5.
28. Battaglia, T.C., D.G. Armstrong, and R.M. Schwend, Factors affecting forearm compartment pressures in children with supracondylar fractures of the humerus. *J Pediatr Orthop*, 2002. 22(4): p. 431:9.
29. Ramachandran, M., et al., Delaying treatment of supracondylar fractures in children: has the pendulum swung too far? *J Bone Joint Surg Br*, 2008. 90(9): p. 1228:33.
30. Diesselhorst, M.M., J.W. Deck, and J.P. Davey, Compartment Syndrome of the Upper Arm After Closed Reduction and Percutaneous Pinning of a Supracondylar Humerus Fracture. *J Pediatr Orthop.* 2014 Mar;34(2):e1-4.
31. Mai, M.C., et al., Posterior arm compartment syndrome after a combined supracondylar humeral and capitellar fractures in an adolescent: a case report. *J Pediatr Orthop.* 2011. 31(3): p. e16:9.
32. Choi, P.D., R. Melikian, and D.L. Skaggs, Risk factors for vascular repair and compartment syndrome in the pulseless supracondylar humerus fracture in children. *J Pediatr Orthop.* 2010. 30(1): p. 50:6.
33. Gupta, N., et al., Effect of surgical delay on perioperative complications and need for open reduction in supracondylar humerus fractures in children. *J Pediatr Orthop*, 2004. 24(3): p. 245:8.
34. Iyengar, S.R., S.A. Hoffinger, and D.R. Townsend, Early versus delayed reduction and pinning of type III displaced supracondylar fractures of the humerus in children: a comparative study. *J Orthop Trauma*, 1999. 13(1): p. 51:5.
35. Leet, A.I., J. Frisancho, and E. Ebramzadeh, Delayed treatment of type 3 supracondylar humerus fractures in children. *J Pediatr Orthop*, 2002. 22(2): p. 203:7.
36. Mehlman, C.T., et al., The effect of surgical timing on the perioperative complications of treatment of supracondylar humeral fractures in children. *J Bone Joint Surg Am*, 2001. 83BA(3): p. 323:7.
37. Haasbeek, J.F. and W.G. Cole, Open fractures of the arm in children. *J Bone Joint Surg Br*, 1995. 77(4): p. 576:81.
38. Flynn JM, Bashyal RK, Yeger-McKeever M, Garner MR, Launay F, Sponseller PD: Acute traumatic compartment syndrome of the leg in children: Diagnosis and outcome. *J Bone Joint Surg Am* 2011;93(10): 937-941.

39. Blackman, A.J., et al., Acute Compartment Syndrome After Intramedullary Nailing of Isolated Radius and Ulna Fractures in Children. *J Pediatr Orthop*. 2014. 34(1):50-4.
40. Yuan, P.S., et al., Compartment syndrome following intramedullary fixation of pediatric forearm fractures. *J Pediatr Orthop*, 2004. 24(4): p. 370:5.
41. Hope, P.G. and W.G. Cole, Open fractures of the tibia in children. *J Bone Joint Surg Br*, 1992. 74(4): p. 546:53.
42. Macer, G.A., Jr., Forearm compartment syndrome in the newborn. *J Hand Surg Am*, 2006. 31(9): p. 1550.
43. Ragland, R., 3rd, et al., Forearm compartment syndrome in the newborn: report of 24 cases. *J Hand Surg Am*, 2005. 30(5): p. 997:1003.
44. Alioglu, B., et al., Successful use of recombinant factor VIIa (NovoSeven) in children with compartment syndrome: two case reports. *J Pediatr Orthop*, 2006. 26(6): p. 815:7.
45. Lee, D.K., et al., Multiple compartment syndrome in a pediatric patient with CML. *J Pediatr Orthop*. 2011. 31(8): p. 889:92.
46. Shaw, B.A. and H.S. Hosalkar, Rattlesnake bites in children: antivenin treatment and surgical indications. *J Bone Joint Surg Am*, 2002. 84(9): p. 1624:9.
47. Ojike NI, Roberts CS, Giannoudis PV. Foot compartment syndrome: A systematic review of the literature. *Acta Orthop Belg*. 2009; 5: 573-580.
48. Ojike NI, Roberts CS, Giannoudis PV. Foot compartment syndrome: A systematic review of the literature. *Acta Orthop Belg*. 2009; 5: 573-580.
49. Cantaboni A, Taveggia F. Aplasia cutis congenital of the upper extremity: presentation of two cases. *Folia Hered Pathol* 1966;15:101.
50. Lightwood R. Radial nerve palsy associated with localized subcutaneous fat necrosis in the newborn. *Arch Dis Child* 1951;26:436 – 437.
51. Hensinger RN. Gangrene of the newborn. A case report. *J Bone Joint Surg* 1975;57A:121–123.
52. Tsur H, Yaffe B, Engel Y. Impending Volkmann’s contracture in a newborn. *Ann Plast Surg* 1980;5:317–320.
53. Caouette-Laberge L, Bartoluzzi P, Egerszegi EP, Marton D. Neonatal Volkmann’s ischemic contracture of the forearm: a report of five cases. *Plast Reconstr Surg* 1992;90:621– 628.
54. Leauté-Labrère C, Depaire-Duclos F, Sarlangue J, Fontan D, Sandler B, Maleville J, et al. Congenital cutaneous defects as complications in surviving co-twins. Aplasia cutis congenita and neonatal Volkmann’s ischemic contracture of the forearm. *Arch Dermatol* 1998;134:1121–1124.
55. Henssge J, Linka F. Volkmann’s contracture and constricting bandage. *Beitr Orthop Traumatol* 1968;15:27–28.
56. Perricone G, Granata C. Volkmann’s syndrome of the forearm in a newborn infant. *Chir Organi Mov* 1982;68:121–125.
57. Silfen R, Amir A, Sirota L, Hauben DJ. Congenital Volkmann–Lesser ischemic contracture of the upper limb. *Ann Plast Surg* 2000;45:313–317.
58. Kline SC, Russell Moore J. Neonatal compartment syndrome. *J Hand Surg* 1992;17A:256 –259.
59. Tsujino A, Hooper G. Neonatal compression ischaemia of the forearm. *J Hand Surg* 1997;22B: 612– 614.
60. Cham P, Drolet B, Segura A, Esterly N. Congenital Volkmann ischaemic contracture: a case report and review. *Br J Dermatol* 2004;150:357–363.
61. Rombouts JJ, Debauche C, Verellen G, Lyon G. Congenital paralysis due to compression. Apropos of four cases. *Ann Chir Main Memb Super* 1993;12:39 – 44.
62. Nassif JM, Gorczyca JT, Cole JK, Pugh KJ, Pienkowski D. Effect of acute reamed versus unreamed intramedullary nailing on compartment pressure when treating closed tibial shaft fractures: A randomized prospective study. *J Orthop Trauma*. 2000; 8: 554-55.
63. Townsend HS, Goodman SB, Schurman DJ, Hackel A, BrockUtne JG. Tourniquet release: Systemic and metabolic effects. *Acta Anaesthesiol Scand*. 1996; 10: 1234-1237.

64. Danner R, Partanen K, Partanen J, Kettunen K. Iatrogenic compartment syndrome, A follow-up of four cases caused by elastic bandage. *Clin Neurol Neurosurg*. 1989; 1: 37-43.
65. Campano D, Robaina JA, Kusnezov N, Dunn JC, Waterman BR. Surgical Management for Chronic Exertional Compartment Syndrome of the Leg: A Systematic Review of the Literature. *Arthroscopy*. 2016 Jul;32(7):1478-86.
66. Feliciano DV, Cruse PA, Spjut-Patrinely V, Burch JM, Mattox KL. Fasciotomy after trauma to the extremities. *Am J Surg* 1988;156:533-6
67. Ritenour AE, Dorlac WC, Fang R, Woods T, Jenkins DH, Flaherty SF, Wade CE, Holcomb JB. Complications after fasciotomy revision and delayed compartment release in combat patients. *J Trauma* 2008;64(2 Suppl):S153-S162
68. Elliott KG, Johnstone AJ. Diagnosing acute compartment syndrome. *J Bone Joint Surg Br*. 2003 Jul;85(5):625-32.

Citation: Hung NN, Duc HH, Anh LT, Sang PC, Hoang NV. Surgical Fasciotomies for Pediatric Acute Compartment Syndrome, and Overview . *SVOA Orthopaedics* 2023, 3:6, 148-167.

Copyright: © 2023 All rights reserved by Hung NN., et al. This is an open access article distributed under the Creative Commons Attribution License, which permits unrestricted use, distribution, and reproduction in any medium, provided the original work is properly cited.