

# Posterolateral Fusion Surgery with Decompression: An Effective Treatment Option for Lumbar Spinal Stenosis

Yousif Sharaf<sup>1\*</sup>, Baha Taha<sup>2</sup>, Yakub Sayyad<sup>3</sup> and Zahra R. Alzaimoor<sup>4</sup>

<sup>1</sup>Orthopedic & Spine Consultant, Alsharaf orthopedic and spine Center, Bahrain.

<sup>2</sup>Anesthesiology, Campbellton Regional Hospital, Campbellton, NB, Canada-E3N 0C7, Campbellton, NB-Canada.

<sup>3</sup>Clinical Research, Shifa Clinic, Chikhli, Ramdasnagar, Pcmc, Pune-412114, Maharashtra- India.

<sup>4</sup>MD, General practitioner, Manama, Bahrain.

\*Corresponding Author: Dr. Yousif Sharaf, Orthopedic & Spine Consultant, Alsharaf orthopedic and spine Center, Bahrain.

DOI: <https://doi.org/10.58624/SVOAOR.2023.03.036>

Received: January 13, 2023 Published: January 30, 2023

## Abstract

**Objective:** The purpose of this study was to provide a comprehensive description of our experience in treating lumbar spinal stenosis (LSS) patients and the clinical outcomes and postoperative complications of surgical decompression and non-instrumented posterolateral fusion.

**Methods:** It's an observational descriptive cross-sectional study conducted on 124 consecutive patients operated for the first time for lumbar spinal stenosis.

**Results:** A total of 124 patients operated for the first time for lumbar spinal stenosis during the study period. The mean age was  $63.8 \pm 11.6$  years. Women were slightly predominant compared to men (52.4% vs. 47.6%). The mean Oswestry disability index differed statistically significantly between time points ( $F(1.93, 237.798) = 6995.59, P < 0.0001$ ) between all the periods (Figure 1). Similarly for Zurich Claudication Questionnaire score over time, the mean also was significantly different between time points ( $F(2, 246) = 70.828, P < 0.0001$ ).

**Conclusion:** Posterolateral fusion surgery with decompression was found to be an effective treatment for lumbar spinal stenosis. This approach involves fusion without instrumentation, which reduces both operating time and intraoperative complications. It also leads to faster post-operative mobilization and less pain. Therefore, it is suggested that posterolateral noninstrumented fusion surgery with decompression be considered as a primary treatment option for lumbar spinal stenosis.

**Keywords:** Lumbar spinal stenosis (LSS); lumbar decompression; minimally invasive surgery.

## Introduction

Lumbar spinal stenosis (LSS) is a condition in which the dural tract and the nerve roots are compressed due to the degeneration of the intervertebral disk, and facet joints. This leads to the thickening/buckling of ligamentum flavum (1). The first clinical description was attributed to Verbiest in 1954. The degenerative spinal stenosis can occur with other conditions including degenerative spondylolisthesis or degenerative scoliosis (2). LSS prevalence is still unknown but it is mainly reported in the aging population and causes significant discomfort and limitations to daily chores and results in severe disability (3,4). The patients complain mostly of low back pain (LBP), sciatica and intermittent claudication (1). Other symptoms include leg numbness, imbalance and lower extremity weakness. A detailed patient history, physical examination and radiographic images are considered for diagnosing patients with LSS. The most important findings representing LSS are age, neurogenic claudication, classic pain radiating to the leg or buttock (which is exacerbated during lumbar extension and relieved on seating or lumbar flexion), and wide-based gait, anatomic narrowing observed in radiographic images. Even the electromyography results and nerve root block is utilized for patient diagnosis (4).

Many different classifications have been reported with the most utilized have been described by Arnoldi et al. categorizing LSS into congenital and acquired. Congenital LSS is further classified into idiopathic and achondroplastic LSS; on the other hand, acquired LSS is classified into degenerative, combined, iatrogenic, spondylolisthesis, post-traumatic and miscellaneous (5). Patients with symptomatic LSS begin firstly with conservative treatments. Analgesics, NSAIDs, opioids and muscle relaxants are used but this poses a threat to the older population. A comprehensive rehabilitation program of manual therapy, stretching and strengthening exercises for the lumbar spine and hip region have been advocated to LSS patients (6). LSS accounts for 30% of all epidural injections; however the results for epidural corticosteroids have shown limited benefit (2). For patients who do not show any improvement with conservative management or who have severe symptoms and thecal sac compression on examination, surgical intervention is generally recommended. There are many surgical approaches for treating LSS which include open, minimally invasive and endoscopic procedures (7). The most widely used surgical techniques are based on the principle of decompression alone or decompression and fusion, with or without instrumentation. Success rates of 26-100% have been reported for different surgical interventions (8). Usually, decompression surgery is recommended for patients suffering lower limb pain and gait disturbance, whereas fusion surgery is performed when there is scoliosis, low back pain, spondylolisthesis, and lumbar instability (9,10).

The purpose of this study was to provide a comprehensive description of our experience in treating lumbar spinal stenosis (LSS) patients and the clinical outcomes and postoperative complications of surgical decompression.

## Materials and Methods

### *Study design and Participants*

It's an observational descriptive cross-sectional study conducted on 124 consecutive patients operated for the first time for lumbar spinal stenosis between 2019 and 2022. The indication for surgery was leg pain, back pain and neurogenic claudication. The presence or absence of instability was defined by flexion and extension x-ray.

The eligibility criteria were all adults suffering from symptomatic LSS (radiologically confirmed) with radiculopathy neurogenic claudication, caused by degenerative changes, and canal stenosis at a maximum of 2-3 levels. Primary exclusion criteria included having previous lumbar surgeries at the same level, having spondylolisthesis of any grade or degenerative scoliosis, having evidence of instability on dynamic radiographs, and having to undergo a concomitant fusion or instrumentation placement.

### *Data collection*

LSS patients who underwent surgery had to respond to several questionnaires at different time points, including.

- ⇒ Socio-demographic information (age, gender) and clinical information (number of levels, cause),
- ⇒ Oswestry Disability Index (ODI) at preoperatively, after 3, 6, and 12 months post operatively,
- ⇒ And a validated outcomes measurement specific to lumbar spinal stenosis, the Zurich Claudication Questionnaire (ZCQ) after 1, 3, and 6 months post operatively.

The ODI auto-questionnaire is used to evaluate function of daily activities for patients with acute or chronic back pain, whereas the ZCQ is another self-administered that aims to assess symptom severity, physical function, and surgery satisfaction in LSS.

### *Statistical analysis*

All statistical analyses were conducted using SPSS version 24.0. Descriptive results are presented as means  $\pm$  standard deviations for continuous variables, and numbers (percentages) for categorical variables. We used two-tailed tests with an alpha error of 0.05 and considered P-values less than 0.05 to be statistically significant. We used repeated measures ANOVA with a Greenhouse-Geisser correction when necessary to compare the Zurich Claudication Questionnaire and Oswestry Disability Index at different time points.

## Results

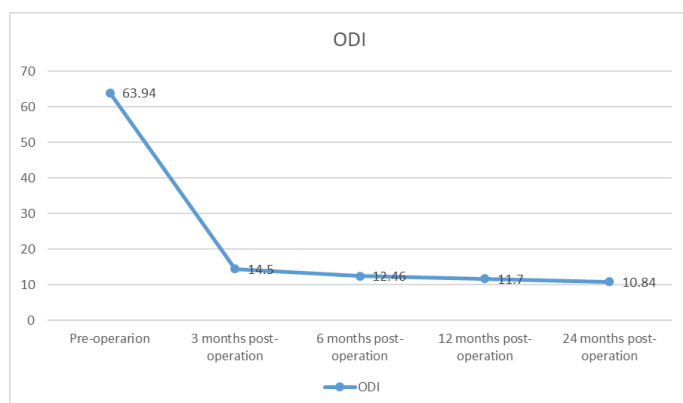
A total of 124 patients underwent decompression with posterolateral fusion surgery for the first time during the study period to treat lumbar spinal stenosis. The patients' clinical and demographic characteristics are summarized in Table 1. The participants ranged in age from 27 to 90 years old, with a mean age of  $63.8 \pm 11.6$  years. The average follow-up time was 24 months. There were slightly more women than men (52.4% vs. 47.6%). A total of 64.5% underwent decompression at one level, 25% at two levels, and 9.7% at three levels. The perioperative complication rate included 0.02 % patients with dural tears and 0.05% patients with superficial wound infections.

No revision surgery was required. Walking distance improved from 200 meters to 1000-1500 meters, and pain improved as measured by a decrease in visual analog scale scores from 8 to 2. The overall satisfaction score on the ZCQ scale was 2 at follow-up, and the Oswestry Disability Index improved from 65 preoperatively to 12 postoperatively.

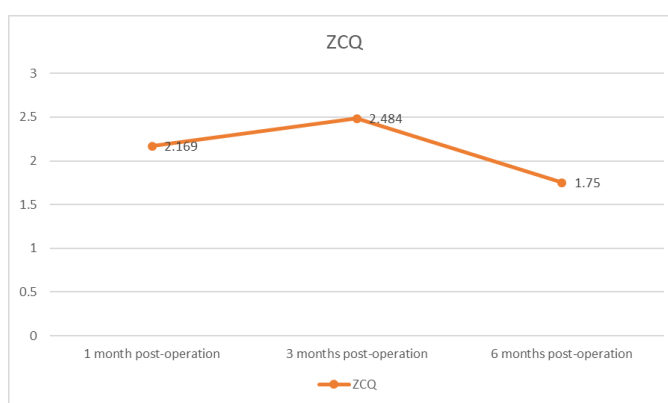
An analysis of repeated measures using ANOVA and the Greenhouse-Geisser correction showed that there was a significant difference in the mean Oswestry Disability Index at different time points ( $F(1.93, 237.798)=6995.59, P<0.0001$ ). Further analysis using the Bonferroni adjustment revealed that the Oswestry Disability Index decreased significantly between all-time points (Figure 1). The mean Zurich Claudication Questionnaire score also showed a significant difference between time points ( $F(2, 246)=70.828, P<0.0001$ ) with a significant difference seen in the post-intervention points in the post hoc analysis (Figure 2).

**Table 1:** Patients characteristics N=124.

	Frequency	Percentage
<b>Age (mean±SD)</b>	63.8±11.6 (Min:27 Max:90)	
<b>Gender</b>		
Male	59	47.6 %
Female	65	52.4 %
<b>Name of operation</b>		
Decompression with posterolateral fusion	124	100%
<b>Level number</b>		
1	80	64.5 %
2	31	25 %
3	12	9.7 %
4	1	0.8 %



**Figure 1:** Oswestry disability index ODI over time ( $p$ -values  $<0.0001$ )



**Figure 2:** The Zurich Claudication Questionnaire ZCQ over time ( $p$ -values  $<0.0001$ )

## Discussion

Decompression is resulted when some of the posterior spinal elements such as ligaments, facets, synovial cysts and others are removed by surgery thus increasing the space in the spinal canal. Yet, these elements when removed can worsen or create instability after decompression (11). LSS is generally prevalent in older population which was comparable to our sample where mean age was 63.8±11.6 years. A previous study, Framingham Study, found that in patients aged between 60 and 69 years old, the relative LSS was 47.2% and the absolute was 19.4% (12). Another Japanese study on 4,400 subjects also reported that the incidence of LSS increases by age (13).

Outcomes of surgical decompression for lumbar spinal stenosis vary depending on the specific condition of the patient and the type of surgery performed. In general, studies have shown that surgical decompression can provide significant relief of symptoms such as leg pain, weakness, and numbness caused by the stenosis. Many patients report improvement in their ability to walk and perform daily activities (14,15).

Furthermore, we report a significant improvement of ODI that evaluates daily functions and the ZCQ is that assess symptom severity, physical function, and surgery satisfaction following decompression for symptomatic lumbar spinal stenosis. When comparing surgical decompression and conservative treatment a study conducted over 10 years reported better results and Oswestry Disability Index (ODI) for the patients randomized for surgical treatment (16,17).

On other hand, a recent meta-analysis of randomised controlled trials (RCTs) comparing surgical versus non-operative treatments in participants with lumbar spinal stenosis using the Oswestry Disability Index (pain-related disability) reported no significant differences after 6 months or 1 year yet favoured decompression at 24 months. A small-sample study indicated no significant difference at 2 months in the Oswestry Disability Index for minimally invasive mild decompression when compared to epidural steroid injections. Nevertheless, Zurich Claudication Questionnaire (ZCQ) improvements were better in the epidural injection group after 2 months at six weeks (Mean Difference -0.60), and visual analogue scale (VAS) results were better in the mild decompression group (Mean Difference 2.40) (11). The difference in findings might be because of studies included in the meta-analysis were of low quality.

However, as with any surgery, there are risks and potential complications, including infection, bleeding, and nerve damage. Additionally, not all patients will experience the same level of improvement or relief of symptoms, and some may require additional surgery or other treatments. It's important to note that the success of the surgery also depend on the preoperative state of the patient, the level of stenosis, the associated comorbidities, and the surgical technique used (18,19). Also, it is important to discuss the potential risks, benefits, and alternatives with your surgeon before undergoing any surgery.

Our descriptive study has some limitations such as the cross-sectional design, which is less potent than a cohort study. For example, a follow-up longitudinal study can assess the pain before and after the treatment. In addition, the information has been gathered from a single centre so the results cannot be generalizable.

In general, decompression surgery is considered as a last resort when non-surgical treatments such as physical therapy, pain management, and medications have failed to provide relief.

## Conclusion

Open interlaminar lumbar decompression with non-instrumented posterolateral fusion is an effective technique that provides sufficient canal decompression, reduces instability, improves patient comfort in the postoperative period, enhances walking ability, and reduces pain. Our patient demonstrated significant improvements in quality of life in both the short and long term follow-up periods. Based on these results, we conclude that decompression with posterolateral fusion surgery is a good long-term treatment option.

## Conflict of Interest

The authors declare no conflict of interest.

## References

1. Taiji R, Iwasaki H, Hashizume H, Yukawa Y, Minamide A, Nakagawa Y, et al. Improving effect of microendoscopic decompression surgery on low back pain in patients with lumbar spinal stenosis and predictive factors of postoperative residual low back pain: a single-center retrospective study. *BMC Musculoskeletal Disorders*. 2021 Nov 15;22(1):954.
2. Genevay S, Atlas SJ. Lumbar Spinal Stenosis. *Best Pract Res Clin Rheumatol*. 2010 Apr;24(2):253–65.
3. Srinivas S, Paquet J, Bailey C, Nataraj A, Stratton A, Johnson M, et al. Effect of spinal decompression on back pain in lumbar spinal stenosis: a Canadian Spine Outcomes Research Network (CSORN) study. *The Spine Journal*. 2019 Jun 1;19(6):1001–8.
4. Wu AM, Zou F, Cao Y, Xia DD, He W, Zhu B, et al. Lumbar spinal stenosis: an update on the epidemiology, diagnosis and treatment. *AME Medical Journal [Internet]*. 2017 May 26 [cited 2022 Nov 23];2(5). Available from: <https://amj.amegroups.com/article/view/3837>
5. Arnoldi CC, Brodsky AE, Cauchoix J, Crock HV, Dommissse GF, Edgar MA, et al. Lumbar spinal stenosis and nerve root entrapment syndromes. Definition and classification. *Clin Orthop Relat Res*. 1976;(115):4–5.

6. Rittenberg JD, Ross AE. Functional rehabilitation for degenerative lumbar spinal stenosis. *Phys Med Rehabil Clin N Am*. 2003 Feb;14(1):111-20.
7. Bagley C, MacAllister M, Dosselman L, Moreno J, Aoun SG, El Ahmadi TY. Current concepts and recent advances in understanding and managing lumbar spine stenosis. *F1000Res*. 2019 Jan 31;8:F1000 Faculty Rev-137.
8. Gelalis ID, Stafilas KS, Korompilias AV, Zacharis KC, Beris AE, Xenakis TA. Decompressive surgery for degenerative lumbar spinal stenosis: long-term results. *Int Orthop*. 2006 Feb;30(1):59-63.
9. Aalto TJ, Malmivaara A, Kovacs F, Herno A, Alen M, Salmi L, et al. Preoperative Predictors for Postoperative Clinical Outcome in Lumbar Spinal Stenosis: Systematic Review. *Spine*. 2006 Aug 15;31(18):E648.
10. Omidi-Kashani F, Hasankhani EG, Ashjazadeh A. Lumbar Spinal Stenosis: Who Should Be Fused? An Updated Review. *Asian Spine J*. 2014 Aug 19;8(4):521-30.
11. Zaina F, Tomkins-Lane C, Carragee E, Negrini S. Surgical versus non-surgical treatment for lumbar spinal stenosis. *Cochrane Database Syst Rev*. 2016 Jan 29;2016(1):CD010264.
12. Kalichman L, Cole R, Kim DH, Li L, Suri P, Guermazi A, et al. Spinal stenosis prevalence and association with symptoms: the Framingham Study. *Spine J*. 2009 Jul;9(7):545-50.
13. Yabuki S, Fukumori N, Takegami M, Onishi Y, Otani K, Sekiguchi M, et al. Prevalence of lumbar spinal stenosis, using the diagnostic support tool, and correlated factors in Japan: a population-based study. *J Orthop Sci*. 2013 Nov;18(6):893-900.
14. Lurie J, Tomkins-Lane C. Management of lumbar spinal stenosis. *BMJ*. 2016 Jan 4;352:h6234.
15. Jain S, Deer T, Sayed D, Chopra P, Wahezi S, Jassal N, et al. Minimally invasive lumbar decompression: a review of indications, techniques, efficacy and safety. *Pain Management*. 2020 Sep;10(5):331-48.
16. Amundsen T, Weber H, Nordal HJ, Magnaes B, Abdelnoor M, Lilleås F. Lumbar spinal stenosis: conservative or surgical management?: A prospective 10-year study. *Spine (Phila Pa 1976)*. 2000 Jun 1;25(11):1424-35; discussion 1435-1436.
17. Malmivaara A, Slätis P, Heliövaara M, Sainio P, Kinnunen H, Kankare J, et al. Surgical or nonoperative treatment for lumbar spinal stenosis? A randomized controlled trial. *Spine (Phila Pa 1976)*. 2007 Jan 1;32(1):1-8.
18. Cheung JPY, Luk KDK. Complications of Anterior and Posterior Cervical Spine Surgery. *Asian Spine J*. 2016 Apr;10(2):385-400.
19. Lumbar decompression surgery - Risks [Internet]. nhs.uk. 2017 [cited 2023 Jan 12]. Available from: <https://www.nhs.uk/conditions/lumbar-decompression-surgery/risks/>

**Citation:** Sharaf Y, Taha B, Sayyad Y, Alzaimoor ZR. Posterolateral Fusion Surgery with Decompression: An Effective Treatment Option for Lumbar Spinal Stenosis. *SVOA Orthopaedics* 2023, 3:1, 07-11.

**Copyright:** © 2023 All rights reserved by Sharaf Y., et al. This is an open access article distributed under the Creative Commons Attribution License, which permits unrestricted use, distribution, and reproduction in any medium, provided the original work is properly cited.