

Giant Cell Tumor within the Tibialis Anterior Tendon: A Case Report

Fahad Hussain^{1*}, Saad Islam¹, Sai Vemula¹ and Matthew Regulski²

¹ Resident Physician, Foot and Ankle Surgery, Community Medical Center- RWJ Barnabas Health, Toms River, New Jersey, USA.

² Attending Physician, Ocean County Foot & Ankle Surgical Associates, P.C., Toms River, New Jersey, USA.

*Corresponding Author: Fahad Hussain, DPM, Department of Foot and Ankle Surgery, 99 NJ-37, Toms River, NJ 08753; fahadhussaindpm@gmail.com

DOI: <https://doi.org/10.58624/SVOAOR.2024.04.070>

Received: February 29, 2024 Published: May 10, 2024

Abstract

Giant cell tumors of tendon sheath (GCT-TS) also characterized as giant cell tumors of low malignant potential (GCT-TS LMP) are extremely rare entities found most frequently in the extremities. It appears as an enlarging painless mass and has a synovial origin. GCT-TS is approximately 1.6% of all soft tissue tumors.¹ The GCT-TS of the tibialis anterior tendon is very rare, and recurrence has not been reported in the literature. The authors present a rare case of a 71-year-old male with a GCT-TS within the Anterior Tibialis tendon. The soft tissue mass is characterized by a mix of giant cell reaction & gouty tophus occurring within the Tibialis Anterior Tendon.

Keywords: Giant Cell Tumors; Tendon Sheath; Tibialis Anterior Tendon, Rare Case, Gout, Tophi

Introduction

Tenosynovial giant cell tumor, also termed giant cell tumor of the tendon sheath (GCT-TS), is a benign, slow growing tumor that normally originates from the tendon sheath or bursa. It can be intraarticular or extraarticular. It's a type of tumor that is more commonly documented in the hands. The foot and ankle account for only 3-5% of all GCT-TS in the body.²

Literature regarding treatment strategies for GCT-TS in the foot and ankle is limited due to a scarcity of patients with this tumor type. Other tumors that mimic GCT-TS radiographically include but are not limited to pigmented villonodular synovitis, fibroma of the tendon sheath, synovial chondromatosis, foreign body granuloma, and chronic tophaceous gout. Advanced imaging is recommended for appropriate diagnosis and treatment plans.

Histologically, GCT-TS resemble their counterpart, giant cell tumor of bone, in which they are characterized by multinucleated giant cells against a background of mononuclear spindle-shaped stromal cells.³

Here we report a rare case of a soft tissue mass characterized by a mix of giant cell reaction & gouty tophus occurring within the Tibialis Anterior Tendon.

Case Presentation

A 71-year-old male with a medical history of Hypertension, Hyperlipidemia, Idiopathic Chronic Gout (currently on long term allopurinol), Radiculopathy of the cervical region, Osteoarthritis, and Left Ankle Open Reduction Internal Fixation due to previous trauma, presented with a progressively enlarging, soft tissue mass to the anteromedial aspect of the Left Ankle, proximal to the ankle joint. The soft tissue mass was causing discomfort with dorsiflexion of the Left Ankle and with shoe wear. To note, the patient was admitted to previously having Left Ankle surgery secondary to trauma in 2010, with no hardware noted in the site of soft tissue mass. The mass had been present for over 1 year as per the patient. In the past year, the mass developed in size and caused increasing discomfort with ambulation and shoe wear.

On examination, the mass was approximately 4.2 x 2.0 cm in size, firm in consistency, non-tender, and non-reducible (Figure 1). Radiographic evaluation (Figures 2.1 and 2.2) only revealed an increase in soft tissue volume and density on the anterior aspect of the ankle with no bony erosions or involvement appreciated. Due to the growing size of the mass, magnetic resonance imaging studies were performed which revealed that the tumor was located in front of the tibiotalar joint surface which is hypointense on T1 weighted imaging (Figure 3.1 and 3.2) and mild hyperintensity on T2 weighted imaging (Figure 3.3) with severe fusiform thickening of the tibialis anterior tendon suggesting giant cell tumor of the tendon sheath and/or tenosynovitis of the tibialis anterior tendon sheath. There was no significant osseous erosion in the adjoining bone. Limited evaluation due to previous ORIF artifact (Figure 3.1). All risks, benefits, and complications of surgical intervention were verbalized to the patient, and the patient elected to proceed with excision of the soft tissue mass.

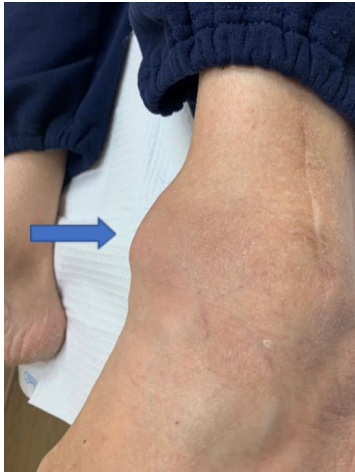

Figure 1: Preoperative photograph of Left Ankle, demonstrating mass (arrow) on the anteromedial aspect.

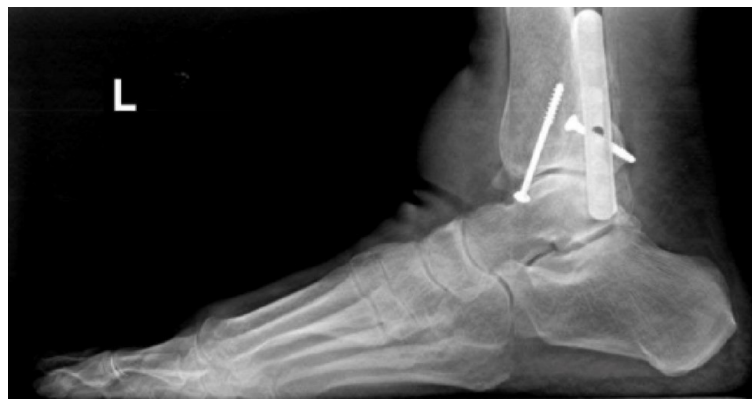

Figure 2.1: Lateral view radiograph showing increase in soft tissue volume & density anterior to the tibio-talar joint in the area of soft tissue mass.

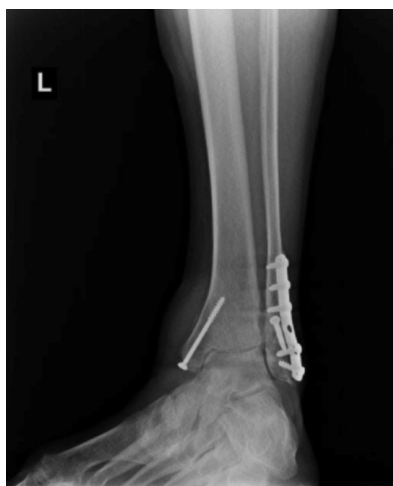

Figure 2.2: Ankle mortise view radiograph showing increase in soft tissue density without bone involvement.

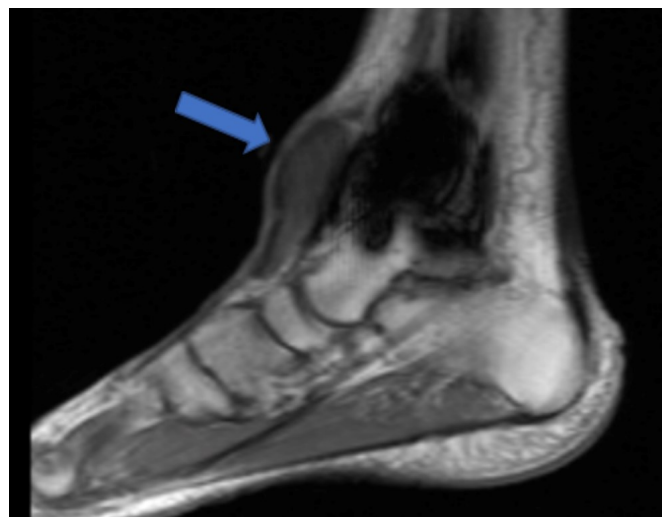


Figure 3.1: MRI of Left Lower Extremity Sagittal T1 - hypointense signal (arrow) within the tumor with ankle artifact secondary to previous ORIF seen.

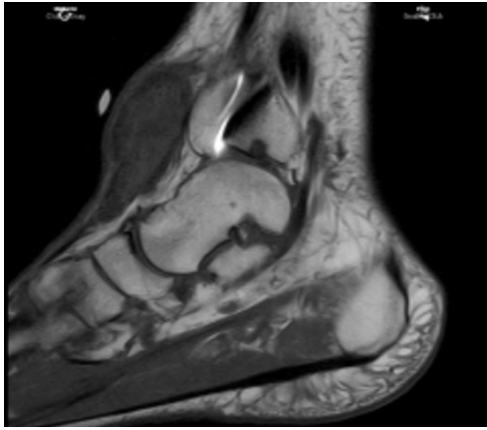


Figure 3.2: MRI of Left Lower Extremity Sagittal T1 - hypointense signal within the tumor.

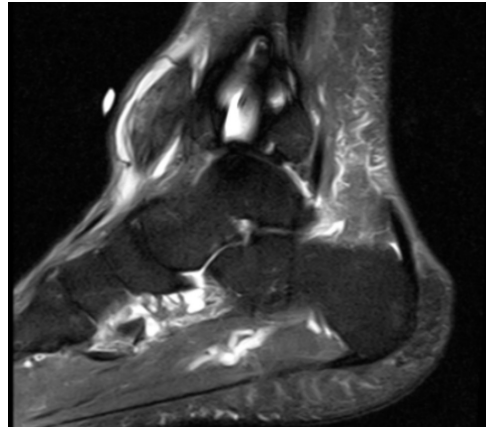


Figure 3.3: MRI of Left Lower Extremity Sagittal T2 view - lesion measures up to 2.0 x 2.0 x 4.1cm (AP X ML X CC), with large amounts of fluid in the tibialis anterior tendon sheath.

Operative Technique

The patient was placed in the supine position and underwent IV sedation with a regional ankle block performed. The left lower extremity was prepped and draped in a normal sterile fashion. A high ankle tourniquet was applied, however, was not inflated. A 9-centimeter linear incision was made over the pole of the Tibialis Anterior tendon with careful, layered dissection both medially and laterally down to the tendon sheath. Upon further dissection, the tendon sheath encompassing the Tibialis Anterior tendon was found to be very hypertrophic and thickened with its appearance being red in color. After careful dissection and preservation of the tendon sheath, a gelatinous-like substance was encountered (Figure 4.) which was removed and sent to the laboratory for pathological identification. The soft tissue mass was then noted to be within the Tibialis Anterior tendon (Figure 5.) and removed with extensive debridement and debulking of the tendon.

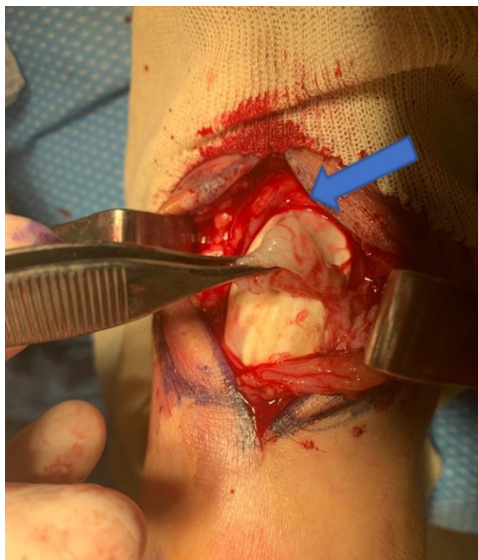

Figure 4: Intraoperative photograph of gelatinous-like substance (arrow) seen upon dissection of Tibialis Anterior tendon sheath.

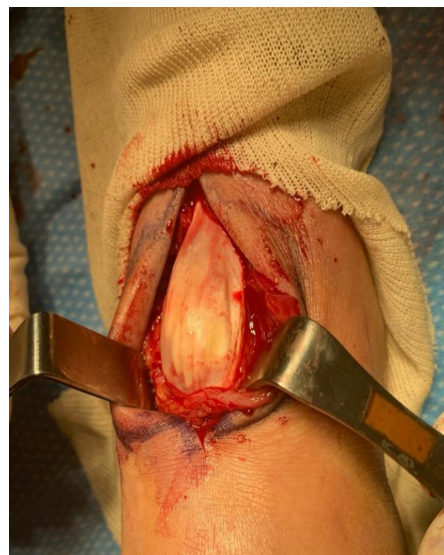

Figure 5: Intraoperative photograph of soft tissue mass within the Tibialis Anterior tendon.

No definitive signs of infection such as pus drainage or malodor were noted. After removal of the mass, along with debulking and tubularization of the Tibialis Anterior tendon, the operative site was closed primarily. Postoperatively, the patient was placed in a short-leg fiberglass cast with the maintenance of the foot and ankle at 90 degrees with strict non-weight-bearing to the Left Lower extremity.

The resected tumor measuring 4.2cm x 2.0cm x 1.3cm and tendon sheath measuring 2.6cm x 2.0cm x 1.2cm were sent to Dianon Department of Pathology for histological evaluation. The dermis contains sheaves of needle-shaped crystals which are surrounded by a considerable histiocytic reaction (Figure 6). The tumor and tendon sheath resulted in fibrovascular connective tissue and synovial tissue with gouty tophus and giant cell reaction.

The patient remained non-weight-bearing to the Left Lower extremity in a fiberglass cast for 4 weeks with frequent post-operative follow-ups. The patient was transitioned to weight-bearing as tolerated thereafter. Pain and discomfort with dorsiflexion of the Left Ankle and with shoe wear was alleviated post-operatively. There were no noted wound complications or re-occurrence noted.

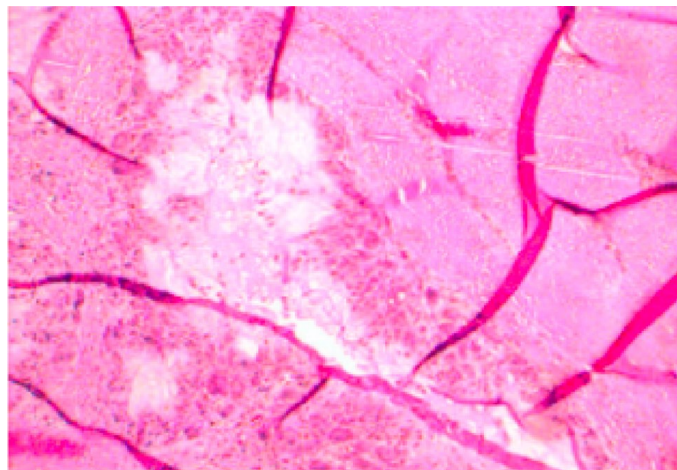


Figure 6: Needle-shaped crystals surrounded by histiocytic reactions is visualized.

Discussion

GCTTS is a benign, slow-growing tumor that originates from the tendon sheath or bursa.⁵ GCTTS is a tumor that is often found in the hand. Previously, it has been reported that only 3-5% of GCTTS is found in the foot and ankle.⁵ Symptoms of GCTTS include pain, joint swelling and limitation of movement.⁶ GCTSS can be aggressive as they can erode adjacent bones by pressure.⁷ Strong diagnosis of GCTSS is advised for better outcomes. Radiographs can show abnormal features such as cortical erosion of bone or intraosseous involvement.^{8,9} Ultrasonography can be used to provide information on tumor vascularity, tumor size, and relationship to the surrounding tissue. It will appear as a solid homogenous hypoechoic mass.^{5,10} In addition, MRI can help with diagnosis. GCTTS can be identified as both low-signal intensity on T1 and T2 weighted images.⁵ Excision of the mass has seen a high recurrence rate, especially when there is bone involvement. Optimal treatment of GCTTS involving adjacent structures including cartilage and bone is controversial. In the foot and ankle, one study reported a local recurrence to be 20% after excision.⁵ Pan et al suggested in their review of patients with GCTTS in the lower extremity that articular structures should be exposed.¹¹ They advised that these structures require excision and that adjuvant radiotherapy treatment to prevent reoccurrence.¹¹ One study involving localized GCTTS in the thumb, conducted radiotherapy treatment with a favorable outcome.¹¹

Gout arises from the deposition of uric acid crystals in joints most typically occurring in the big toe joint causing redness, swelling, and severe pain.¹⁴ Unlike most other rheumatological diseases, gout is unique in that it can be managed and often cured with the right treatments.¹² Gout is caused by either overproduction of uric acid, which is seen in 10% of patients, or a renal underexcretion, which is seen in the 90% majority.¹⁴ Uric Acid is the end product of purine metabolism and normal levels within the human body is 6.8mg/dL.¹⁴ Levels exceeding this have a higher prominence of gout flare ups in patients.¹³ The crystals tend to precipitate faster at lower temperatures, which is why the extremities like the toes tend to have more frequent flareups.¹³ Gout can either be asymptomatic, acute, intercritical, or chronic.¹⁴

Acute gout is rapidly developing inflammation, and a period between acute flareups is known as the intercritical period.¹⁴ Chronic gout is characterized by long term inflammation from several acute attacks, leading to gouty tophi present in the joint.¹²

During acute gout attacks, NSAIDs or steroids such as prednisone are generally the first line of treatment as inflammation control is the primary goal.¹⁴ Colchicine can also be supplemented to prevent crystal deposition during the acute phase.¹³ Probenecid, which is a uricosuric, is often combined with an NSAID during a flare up especially in certain patients with impaired clearance.¹³ Prophylactically, many chronic under excretors suffering from recurrent attacks are treated with allopurinol, which is a xanthine oxidase inhibitor preventing uric acid buildup.¹² Allopurinol is recognized as the first line treatment of chronic gout and has shown favorable outcomes in controlling gout flare ups.¹³

Tophaceous gout characterizes the chronic phase of disease and in rare instances present in tendons of hands and knees.³ Only one other case has been reported about gouty tophi in the quadriceps tendon in a patient who had a history of gout.⁴ No previous record of presentation below the leg and specifically in the tibialis anterior tendon has been reported. Gout can mimic GCT in tendons by forming tumor-like masses and be misdiagnosed as an infection or a neoplasm. Given the deceptive nature of presentation of GCT vs gout, the histology, radiographic imaging and clinical presentation have to be taken into account to determine the treatment of choice.

This case demonstrates that a gouty tophus may mimic a soft-tissue neoplasm although not obvious from initial radiographs. Given that there were no calcifications or bone involvement, there was a low suspicion of gout initially. Because of known clinical history and recurrence rate of gout, aspiration was not the first line of treatment in this case. The initial clinical and radiological diagnoses were that of a giant cell tumor of tendon sheath. GCTTS has a low malignant potential, however the etiology remains unclear.

Conclusion

We reported a rare case of a soft tissue mass characterized by a mix of giant cell reaction & gouty tophus occurring within the Tibialis Anterior Tendon. No previous record of presentation below the leg and specifically in the tibialis anterior tendon has been reported. In future cases, GCTTS should be in the working differential for soft tissue masses in the foot and ankle.

Patient Consent

The patient gave consent in writing for data concerning this case to be submitted for publication.

Conflict of Interest

The authors declare they have no conflict of interest.

Funding

There is no funding source.

References

1. LaRussa LR, Labs K, Schmidt RG, Schwamm HA, Schoenhaus HD. Giant cell tumor of tendon sheath. *J Foot Ankle Surg.* 1995;34(6):541-546. doi:10.1016/S1067-2516(09)80075-6
2. Gibbons CL, Khwaja HA, Cole AS, Cooke PH, Athanasou NA. Giant-cell tumour of the tendon sheath in the foot and ankle. *J Bone Joint Surg Br.* 2002;84(7):1000-1003. doi:10.1302/0301-620x.84b7.13115
3. Falasca GF. Metabolic diseases: gout. *Clin Dermatol.* 2006;24(6):498-508. doi:10.1016/j.clindermatol.2006.07.015
4. Bond JR, Sim FH, Sundaram M. Radiologic case study. Gouty tophus involving the distal quadriceps tendon. *Orthopedics.* 2004;27(1):18-92. doi:10.3928/0147-7447-20040101-12
5. Zhang Y, Huang J, Ma X, Wang X, Zhang C, Chen L. Giant cell tumor of the tendon sheath in the foot and ankle: case series and review of the literature. *J Foot Ankle Surg.* 2013;52(1):24-27. doi:10.1053/j.jfas.2012.09.008
6. Bruns J, Yazigee O, Habermann CR. Pigmented villonodular synovitis and teno-synovial giant-cell tumors. *Z Orthop Unfall.* 2008, 146: 663-680.

7. Reilly KE, Stern PJ, Dale JA. Recurrent giant cell tumors of the tendon sheath. *J Hand Surg Am.* 1999;24(6):1298-1302. doi:10.1053/jhsu.1999.1298
8. Uriburu IJ, Levy VD. Intraosseous growth of giant cell tumors of the tendon sheath (localized nodular tenosynovitis) of the digits: report of 15 cases. *J Hand Surg Am.* 1998;23(4):732-736. doi:10.1016/S0363-5023(98)80062-2
9. Karasick D, Karasick S. Giant cell tumor of tendon sheath: spectrum of radiologic findings. *Skeletal Radiol.* 1992;21(4):219-224. doi:10.1007/BF00243061
10. Middleton WD, Patel V, Teefey SA, Boyer MI. Giant cell tumors of the tendon sheath: analysis of sonographic findings. *AJR Am J Roentgenol.* 2004;183(2):337-339. doi:10.2214/ajr.183.2.1830337
11. Goda JS, Patil P, Krishnappan C, Elangovan D. Giant cell tumor of the tendon sheath treated by brachytherapy (surface mold) technique-A technical illustration. *Brachytherapy.* 2009;8(1):79-83. doi:10.1016/j.brachy.2008.07.008
12. Gelber AC. Treatment Guidelines in Gout. *Rheum Dis Clin North Am.* 2022;48(3):659-678. doi:10.1016/j.rdc.2022.04.003
13. Lorenzo JPP, Sollano MHMZ, Salido EO, et al. 2021 Asia-Pacific League of Associations for Rheumatology clinical practice guideline for treatment of gout. *Int J Rheum Dis.* 2022;25(1):7-20. doi:10.1111/1756-185X.14266
14. Stockert AL, Stechschulte M. Allopurinol to febuxostat: How far have we come? *Clinical Medicine Insights: Therapeutics.* 2010;2. doi: 10.4137/cmt.s6286

Citation: Hussain F, Islam S, Vemula S, Regulski M. Giant Cell Tumor within the Tibialis Anterior Tendon: A Case Report. *SVOA Orthopaedics* 2024, 4:3, 49-54.

Copyright: © 2024 All rights reserved by Hussain F., et al. This is an open access article distributed under the Creative Commons Attribution License, which permits unrestricted use, distribution, and reproduction in any medium, provided the original work is properly cited.