

# A Novel PSAP Gene Mutation in A Lebanese Patient with A Limited Phenotypic Expression

Mohamad Wehbe<sup>1</sup>, Sacha Saad<sup>2</sup>, Mohamad Fattah<sup>3</sup> and Hicham Mansour<sup>4\*</sup>

<sup>1</sup> Faculty of Medicine, American University of Beirut, Beirut, Lebanon.

<sup>2</sup> Biology Department, American University of Beirut, Beirut, Lebanon.

<sup>3</sup> Department of Pediatrics, Military Hospital, Beirut, Lebanon.

<sup>4</sup> Department of Pediatrics, Saint George University Medical Center, Beirut, Lebanon.

\*Corresponding Author: Hicham Mansour, Department of Pediatrics, Saint George University Medical Center, Beirut, Lebanon.

DOI: <https://doi.org/10.58624/SVOAPD.2023.02.036>

Received: May 29, 2023 Published: June 13, 2023

## Abstract

Metachromatic leukodystrophy is an autosomal recessive neurodegenerative disorder that affects the central and peripheral nervous system and falls under the family of lysosomal storage diseases (LSDs). It is divided into three clinical forms (late infantile, juvenile, and adult) depending on how early the disease manifests and with varying prognosis for each form. Common presentations of the disease include cognitive, behavioral, and motor symptoms. Here, we present a Lebanese patient with a novel variant in the prosaposin gene, confirming the diagnosis of metachromatic leukodystrophy due to saposin B mutation, with a phenotypic expression of the disease limited to an attention deficit disorder, and a clear leukodystrophy.

**Keywords:** PSAP gene mutation; Metachromatic leukodystrophy (MLD); Saposin B mutation.

## Introduction

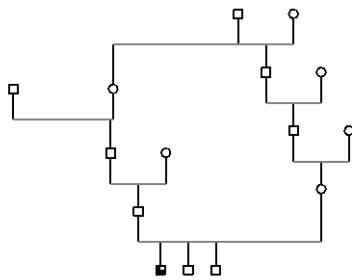
Metachromatic leukodystrophy (MLD) is a neurodegenerative disorder whereby the progressive demyelination of the central and peripheral nervous system results in symptoms of psychomotor regression, gait disturbances, ataxia, peripheral neuropathy, and visual disturbances leading to tonic spasms and decerebrate posturing and finally death. MLD is characterized by defects in degradation and accumulation of cerebroside-3-sulfate (sulfatides) in lysosomes of oligodendrocytes and Schwann cells leading to their death [1]. In vivo, sulfatides are usually metabolized by the lysosomal enzyme, arylsulfatase A (ARSA), in the presence of a sphingolipid activator protein called Saposin B (Sap-B) [2-4]. Genetic defects in genes coding for ARSA and Sap-B which are inherited as an autosomal recessive trait result in MLD. Most forms of MLD are associated with allelic variants in the ARSA gene locus while cases due Sap-B mutations are extremely rare but have been reported in the literature [5-7].

According to the age of onset of symptoms, MLD caused by mutations in the ARSA gene is usually classified into three main clinical forms: late infantile, juvenile (subdivided further into early and late juvenile forms), and adult. Earlier onset of the diseases is usually predictive of a severe phenotype and a worse prognosis overall. Therefore, both the late infantile (symptoms before 30 months of age) and early juvenile forms (symptoms after 30 months of age) present with a more rapid disease progression and a shorter life expectancy overall [5]. On the other hand, MLD caused by mutations in sulfatide activator proteins (Sap-B) have a similar clinical manifestation to those with ARSA deficiency but show ARSA activity within normal range. Sap-B protein is one derived from a large precursor protein, prosaposin encoded by a gene called PSAP located on chromosome number 10. This protein can be cleaved to give rise to four cleavage products which are saposins A, B, C, and D [8]. As a result, mutations in the PSAP gene can lead to conditions resembling MLD (mutations in Sap-B), Gaucher disease (mutations in Sap-C), or Krabbe disease (mutations in Sap-A) [9, 10].

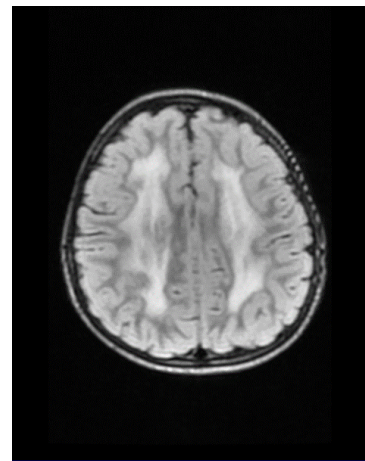
To date, only 10 PSAP pathogenic variants have been found in 26 MLD patients published in the literature where 17 of them had the late infantile form, 6 with juvenile onset, 1 adult form, and 2 patients reported to still be asymptomatic [5]. Here, we describe the first reported Lebanese patient with metachromatic leukodystrophy due to a novel Sap-B mutation presenting with limited phenotypic expression of the disease.

## Case Report

Here we present a case of a 3-year-old boy born to consanguineous parents (Figure 1). He was born at term after an uneventful pregnancy and a normal delivery with no complications. At the age of 1 year, he was able to stand up by himself, but he could not generate any speech. 6 months later, he was not answering when called by his name. Psychomotor and speech therapy sessions were initiated for a year, and significant improvements were observed. The patient presented to our institution at the age of 3 years with speech and cognitive delay. He was able to stand up and walk properly. He had a normal interaction with the surrounding environment and was not exposed to screens for a long time. The patient had a normal weight and height at the 50<sup>th</sup> percentile but had a head circumference of 52 cm (93<sup>rd</sup> percentile for age). Other than the cognitive delay, no abnormalities or significant findings were noted during physical examination. His speech therapist reported important improvement with respect to all behaviors, even though he wasn't responding as easily. A baseline workup for the patient showed normal CBC, CPK, SGOT, SGPT, sodium, and uric acid levels. Lactic acidosis was noted 35.59 mg/dL (reference range 4.5-19.8 mg/dL). Chromatography of amino acids in blood and of organic acids in urine showed no anomalies. Brain findings on MRI revealed wide symmetric periventricular white matter involvement and a tigroid pattern (Figure 2).



**Figure 1:** Patient's Pedigree.

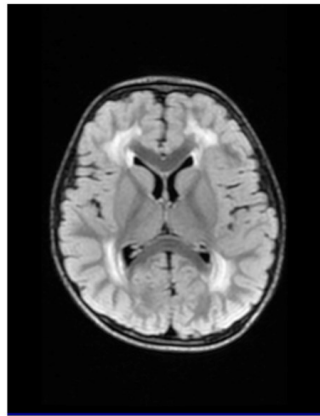
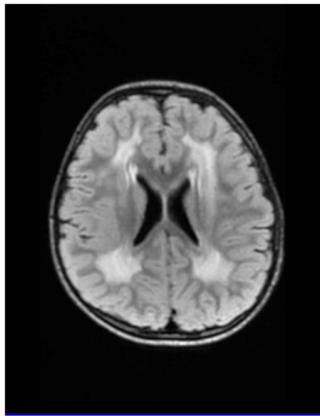


**Figure 2:** Axial Flair sequence MRI showing periventricular white matter changes and hyperintensity (black arrows).

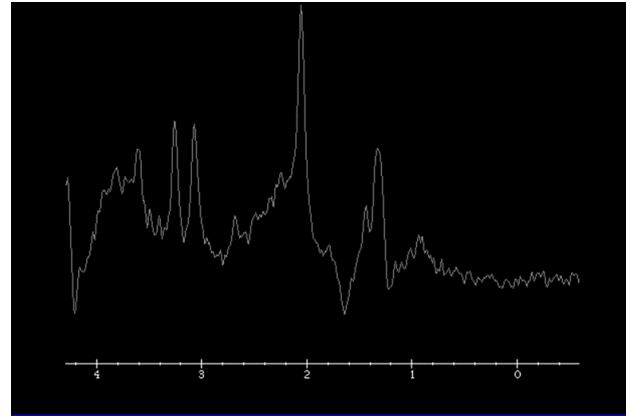
Frontal and infratentorial pathologic white matter hyperintensity on both sides sparing the juxtacortical region and U-cortical fibers are noted (Figure 3). Proton spectroscopic studies of the affected brain regions showed an elevated lactate peak (Figure 4).

After 5 months, of treatment with L-Carnitine, Coenzyme Q10 and Vitamin B2, the patient was expressing himself much better and showed signs of improved cognitive functioning, and an improved speech, the patient was able to speak normally, form full sentences, and exhibit better counting. It was also reported that he is doing better in school where he is now interacting better with his teachers. The Whole exome sequencing revealed a novel homozygous in frame deletion C1005\_1007del p.(Assn335del) of 3 bps deletion in exon 10 of the PSAP gene in favor of autosomal recessive metachromatic leukodystrophy due to Sap-B deficiency.

The patient continued to improve with persisting signs of agitation and hyperactivity. After 5 months, patient presented for follow-up where he showed better cognitive functioning overall, better speech, and improved interaction. His hyperactivity showed some improvement. New MRI images showed similar symmetrical white matter hyperintensities as previously seen. Overall, the child had a great tone of activity and was even reported to be doing well in school. After 4 years follow up the patient is doing well in school with mild dyslexia and dysgraphia. He was speaking Arabic fluently and was more attentive and showed better interaction and better contact overall.



**Figure 3:** Axial Flair MRI images showing white matter changes and hyperintensity in the frontal (black arrows) and infratentorial regions of the brain (white arrows).



**Figure 4:** Proton spectroscopic image showing lactate peak at 1.3 ppm.

## Discussion

MLD is an autosomal recessive neurodegenerative disease that belongs to the family lysosomal storage diseases (LSDs). MLD is one of the most common leukodystrophies in the world with a prevalence rate of 1 in 40,000-160,000 [11]. PSAP gene mutations in regions coding for the Sap-B domain are known to cause a rare MLD variant in which ARSA activity is normal but myelin sheath degeneration occurs due to the accumulation of sulfatides in oligodendrocytes and Schwann cells. According to the literature, 26 patients of different ancestries have been identified with 10 different PSAP mutations [12-15]. In this study, we report for the first time, a family of Lebanese origins with a mutation in Sap-B resulting in limited phenotypic expression of MLD and clinical stability. Usual symptoms of MLD such as gait disturbances, ataxia, peripheral neuropathy, and visual disturbances were absent in the patient and only cognitive regression was noted at first. The patient's cognitive symptoms and speech improved significantly with time while the ADHD-like symptoms of hyperactivity and distractibility persisted mildly, this clinical stability can be explained by the treatment of the secondary mitochondrial dysfunction expressed with the lactic acidosis. The neuro-radiological features observed under MRI such as the symmetrical periventricular white matter involvement as well as the trigoid pattern were in favor of the diagnosis, and the imaging stability and the clinical improvement seem to be linked to the penetrance of the mutation. The PSAP variant identified in this report is likely a novel mutation that has not been reported in the literature. The PSAP variant's coordinates are c.1005\_1007. This variant is an in-frame deletion of 3 base pairs in exon 10 of the PSAP gene which leads to loss of residue asparagine at position 335.

It has been described that protein stability of Sap-B is related to the formation of disulfide bridges where multiple cysteine residues have been reported to be linked to each other [16]. These disulfide bridges have also been well-localized leading to the interaction of distant saposin domains with the arrangement of these disulfide bridges playing a role in the Sap-B functionality [14]. The importance of this arrangement has been demonstrated experimentally in Sap-B deficient mice whereby a knock-in mutation of cysteine corresponding to human was introduced. Thus, no Sap-B protein was found in homozygous mice (-/-) where Sap-A, C, and D were all at normal levels [14]. Therefore, mutations affecting multiple regions in the PSAP gene such mutations leading to destabilization of disulfide bridges can lead to impaired Sap-B functioning within the body. Moreover, it has also been reported that splice site abnormalities in the PSAP gene leads to MLD with a wide range of symptoms and expression [17, 18]. Therefore, our report of a novel mutation in the PSAP gene can provide further evidence that phenotypes of patients with Sap-B deficiency can vary widely and have different expressions depending on multiple factors such as onset, type, and severity of symptoms which are not necessarily closely correlated with the type of mutation.

Another aspect should be highlighted with the occurrence of this rare mutation, is that despite the major shift to urban life style in Lebanon, high rates of consanguinity remain present. [19-20-21], necessitating the need of initiatives in health and sexual education as well as genetic counseling.

## Conclusion

In conclusion, this is the first Lebanese patient to be identified as a carrier of this novel PSAP mutation variant with limited phenotypic expression of metachromatic leukodystrophy (MLD) due to a specific mutation causing a deficiency in Sap-B. The patient presents a clinical stability and a cognitive improvement despite the central nervous system lesions.

The identification of a novel mutation in the PSAP gene emphasizes the wide variability and diverse expressions of phenotypes in patients with Sap-B deficiency. This underscores the importance of understanding that the type of mutation does not always closely correlate with the clinical presentation of the disease.

## Conflict of Interest

The authors declare no conflict of interest.

## References

1. Boltshauser, E., Aicardi's Diseases of the Nervous System in Childhood. *Neuropediatrics*, 2019. 50(3): p. 207.
2. Schuette, C.G., et al., Sphingolipid activator proteins: proteins with complex functions in lipid degradation and skin biogenesis. *Glycobiology*, 2001. 11(6): p. 81R-90R.
3. Fluharty, A.L., et al., Two new arylsulfatase A (ARSA) mutations in a juvenile metachromatic leukodystrophy (MLD) patient. *Am J Hum Genet*, 1991. 49(6): p. 1340-50.
4. Burk, R.D., et al., Early manifestations of multiple sulfatase deficiency. *The Journal of Pediatrics*, 1984. 104(4): p. 574-578.
5. Cesani, M., et al., Mutation Update of ARSA and PSAP Genes Causing Metachromatic Leukodystrophy. *Hum Mutat*, 2016. 37(1): p. 16-27.
6. Kolnikova, M., et al., Late Infantile Metachromatic Leukodystrophy Due to Novel Pathogenic Variants in the PSAP Gene. *J Mol Neurosci*, 2019. 67(4): p. 559-563.
7. Siri, L., et al., A novel homozygous splicing mutation in PSAP gene causes metachromatic leukodystrophy in two Moroccan brothers. *Neurogenetics*, 2014. 15(2): p. 101-6.
8. Kishimoto, Y., M. Hiraiwa, and J.S. O'Brien, Saposins: structure, function, distribution, and molecular genetics. *J Lipid Res*, 1992. 33(9): p. 1255-67.
9. Kose, M., et al., The Second Case of Saposin A Deficiency and Altered Autophagy. *JIMD Rep*, 2019. 44: p. 43-54.
10. Vaccaro, A.M., et al., Saposin C mutations in Gaucher disease patients resulting in lysosomal lipid accumulation, saposin C deficiency, but normal prosaposin processing and sorting. *Hum Mol Genet*, 2010. 19(15): p. 2987-97.
11. Shaimardanova, A.A., et al., Metachromatic Leukodystrophy: Diagnosis, Modeling, and Treatment Approaches. *Front Med (Lausanne)*, 2020. 7: p. 576221.
12. Kuchař, L., et al., Prosaposin deficiency and saposin B deficiency (activator-deficient metachromatic leukodystrophy): Report on two patients detected by analysis of urinary sphingolipids and carrying novel PSAP gene mutations. *American Journal of Medical Genetics Part A*, 2009. 149A(4): p. 613-621.
13. Al-Hassnan, Z.N., et al., Sphingolipid activator protein B deficiency: report of 9 Saudi patients and review of the literature. *J Child Neurol*, 2009. 24(12): p. 1513-9.
14. Sun, Y., et al., Neurological deficits and glycosphingolipid accumulation in saposin B deficient mice. *Hum Mol Genet*, 2008. 17(15): p. 2345-56.
15. Stenson, P.D., et al., The Human Gene Mutation Database: 2008 update. *Genome Med*, 2009. 1(1): p. 13.
16. Vaccaro, A.M., et al., Structural analysis of saposin C and B. Complete localization of disulfide bridges. *J Biol Chem*, 1995. 270(17): p. 9953-60.
17. Henseler, M., et al., Analysis of a splice-site mutation in the sap-precursor gene of a patient with metachromatic leukodystrophy. *Am J Hum Genet*, 1996. 58(1): p. 65-74.
18. Friede, R.L., *Metachromatic Leukodystrophy (Sulfatase A Deficiency) and Multiple Sulfatase Deficiency*, in *Developmental Neuropathology*, R.L. Friede, Editor. 1989, Springer Berlin Heidelberg: Berlin, Heidelberg. p. 461-469.
19. Les maladies rares au Liban: difficultés diagnostiques et thérapeutiques - Mansour H. - *Arch Pediatr*. 2015 May;22(5 Suppl 1):1-2. doi: 10.1016/S0929-693X(15)30002-6.
20. Nadine Jalkh, Sandra Corbani, Zahraa Haidar, Nadine Hamdan, Elias Farah, Joelle Abou Ghoch, Rouba Ghosn, Nabiha Salem, Ali Fawaz, Claudia Djambas Khayat, Mariam Rajab, Chebl Mourani, Adib Moukarzel, Simon Rassi, Bernard Gerbaka, Hicham Mansour, Malek Baassiri, Rawane Dagher, David Breich, André Mégarbané, Jean Pierre Desvignes, Valérie Delague, Cybel Mehawej and Eliane Chouery. The added value of WES reanalysis in the field of genetic diagnosis: lessons learned from 200 exomes in the Lebanese population *BMC Medical Genomics* 2019; 12:11 <https://doi.org/10.1186/s12920-019-0474-y>

21. Nair P, Sabbagh S, Mansour H, et al. Contribution of next generation sequencing in pediatric practice in Lebanon. A Study on 213 cases. *Mol Genet Genomic Med.* 2018;00:1–12. <https://doi.org/10.1002/mgg3.480>

**Citation:** Wehbe M, Saad S, Fattah M, Mansour H. A Novel PSAP Gene Mutation in A Lebanese Patient with A Limited Phenotypic Expression. *SVOA Paediatrics* 2023, 2:3, 73-77.

**Copyright:** © 2023 All rights reserved by Mansour H., et al. This is an open access article distributed under the Creative Commons Attribution License, which permits unrestricted use, distribution, and reproduction in any medium, provided the original work is properly cited.