

## Anemic Gastrointestinal Bleeding in *Campylobacter Jejuni* Infection

Julio César Moreno-Alfonso MD<sup>1\*</sup>, Giuseppa Antona MD<sup>1</sup>, Ada Molina Caballero MD<sup>1</sup> and Alberto Pérez Martínez MD, PhD<sup>1</sup>

<sup>1</sup> Department of Pediatric Surgery, Hospital Universitario de Navarra, Pamplona, Spain.

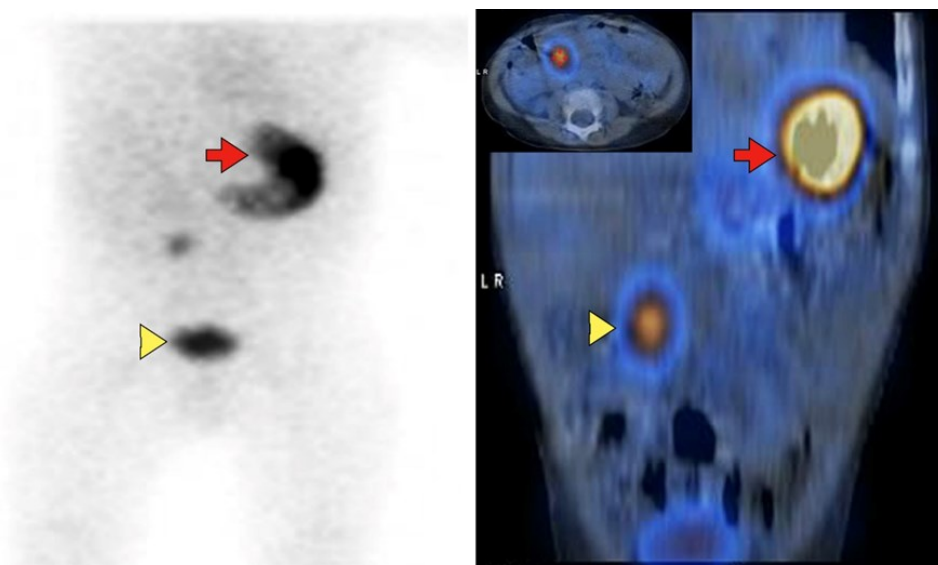
\*Corresponding Author: Julio César Moreno-Alfonso MD, Department of Pediatric Surgery, Hospital Universitario de Navarra. Pamplona, Spain.

DOI: <https://doi.org/10.58624/SVOAPD.2024.03.057>

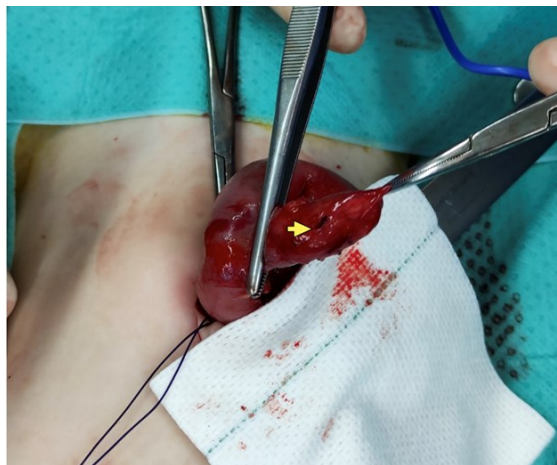Received: February 24, 2023 Published: March 20, 2024

We present a 13-month-old male with a history of multiple diarrheal episodes with mucus and blood due to *Campylobacter Jejuni* infection. He was admitted in the last of them due to mucosanguinous stools, fever and oral intolerance. He was treated with amoxicillin/clavulanic acid and a blood test was performed without leukocytosis ( $14 \times 10^9/L$ ) but with neutrophilia ( $10.2 \times 10^9/L$ ) and elevated CRP (85mg/L), in addition to abdominal ultrasound with minimal fluid tab in the right iliac fossa. On the second day of hospitalization, he presented an anemizing and painless gastrointestinal bleeding that required transfusion (hemoglobin 6.3g/dL), however, he was hemodynamically stable, with slightly painful abdomen in lower quadrants, but without peritoneal irritation.

In view of the severity of the analytical findings, a Technetium 99-m scintigraphy was requested, which revealed ectopic gastric mucosa (Fig. 1) and a Meckel's diverticulectomy was performed (Fig. 2). Six months later the patient is asymptomatic and stool cultures are negative. In the presence of recurrent and painless lower gastrointestinal bleeding, the presence of a remnant of the omphalomesenteric duct should be suspected (1,2), even if there are other intercurrent infectious processes that may explain the symptoms, since the ectopic gastric mucosa can be colonized, especially by bacteria of the *Campylobacter* genus (3,4).



**Figure 1.** Marker uptake in the orthotopic (arrow) and ectopic (arrowhead) gastric mucosa in the lower hemiabdomen, at the level of L1-L2.



**Figure 2.** Meckel's diverticulum 40 cm from the ileocecal valve, perforated in its middle third (arrow).

### Declaration of Interest

None

### Financial and material support

None to declare

### Consent statement

Informed consent was obtained from the patient's parents for the taking of photographs and their publication.

### References

1. Robles A, Mora OA, Andrade H, et al. Subacute Meckel's diverticulum perforation. *BMJ Case Rep.* 2021;14:e237840
2. Moreno JC, Molina AY, Pérez A, et al. Juvenile Polyp: The great simulator. *Rev Colomb Cir.* 2022;37:492-493
3. De Cothi GA, Newbold KM, O'Connor HJ. *Campylobacter*-like organisms and heterotopic gastric mucosa in Meckel's diverticula. *J Clin Pathol.* 1989;42(2):132-4
4. Morris A, Nicholson G, Zwi J, et al. *Campylobacter pylori* infection in Meckel's diverticula containing gastric mucosa. *Gut.* 1989;30:1233-5.

**Citation:** Moreno-Alfonso JC, Antona G, Molina Caballero A, Pérez Martínez A. Anemic Gastrointestinal Bleeding in *Campylobacter Jejuni* Infection. *SVOA Paediatrics* 2024, 3:2, 17-18.

**Copyright:** © 2024 All rights reserved by Moreno-Alfonso JC., et al This is an open access article distributed under the Creative Commons Attribution License, which permits unrestricted use, distribution, and reproduction in any medium, provided the original work is properly cited.