

# Tuberculosis Presenting as Anterior Mediastinal Mass - A Possibility in An Immunocompetent Child

Tahir Muhammad Yaseen<sup>1\*</sup>, Atif Zulfiqar<sup>2</sup>, Shabbir Hussain<sup>3</sup> and Aisha Fazal<sup>3\*</sup>

<sup>1</sup>Senior Registrar Pediatric Surgery, Liaquat National Medical College and Hospital Karachi, Pakistan.

<sup>2</sup>Resident Pediatric Surgery, Liaquat National Medical College and Hospital Karachi, Pakistan.

<sup>3</sup>Consultant Pediatric Surgery, Liaquat National Medical College and Hospital Karachi, Pakistan.

<sup>3\*</sup>Resident Pediatric Medicine, Baqai Medical University and Hospital Karachi, Pakistan.

**\*Corresponding Author:** Tahir Muhammad Yaseen, Senior Registrar Pediatric Surgery, Liaquat National Medical College and Hospital Karachi, Pakistan.

DOI: <https://doi.org/10.58624/SVOAPD.2024.03.059>

**Received:** March 02, 2023 **Published:** April 09, 2024

## Abstract

A case of an 8-year-boy is reported who presented with a two month history of high-grade fever, associated with reduction in his appetite and subjective weight loss. He was treated empirically on the lines of bronchopneumonia, however, with no relief in his symptoms. Chest radiograph showed mediastinal widening, which prompted the need for a computed tomographic (CT) scan of the chest revealing an anterior mediastinal mass abutting the pericardium and compressing the great vessels. The possibilities of lymphoma or germ cell tumour were considered. The serum tumor markers were unremarkable. The child underwent midline sternotomy, with complete excision of mass. The histopathology of the lesion revealed multiple epithelioid cell granulomas with necrosis, and final diagnosis of a tuberculous lesion was made. The clinical course of this patient and the relevant literature is presented in this paper.

**Keywords:** Tuberculosis, Anterior mediastinal mass, Mediastinal widening

## Introduction

The anterior mediastinum is a confined space, but the presence of diverse nature of anatomical structures and varied diseases associated with makes it a region of great clinical interest. It encloses ligaments, fat, muscles and parenchymatous organs. The diverse nature of anterior mediastinal masses poses a diagnostic problem because the differential diagnoses range from absolutely benign to highly malignant and a diagnostic delay can prove to be fatal. The common anterior masses include thymoma, lymphoma, and germ cell tumours [1, 2]. The presentation of tuberculosis as an isolated mediastinal mass without lung parenchymal lesion is not common [3, 4].

Here, we present a case of anterior mediastinal mass compressing the great vessels and associated cardiac structures which was surgically excised completely and later confirmed on histopathologically to be tuberculous and treated with antituberculosis therapy (ATT).

## Case Summary

A 8-year-old boy presented to us in April 2022 with high grade fever for the last 02months, along with history of decreased appetite and undocumented weight loss. He had history of orthopnea and shortness of breath upon exertion. However, there was no history of chest pain, hemoptysis, hoarseness of voice, or dysphagia. The family denied any history of TB contact. He was already treated empirically on the lines of bronchopneumonia.

However, there was no relief in his symptoms with persistent fever, along with associated worsening orthopnea and shortness of breath.

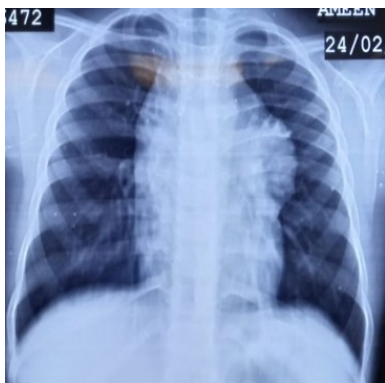
### Physical Examination

On examination, the patient was afebrile, pulse (80/minute), and respiratory rate (18/minute) lying propped up on bed. The lymph nodal examination was unremarkable.

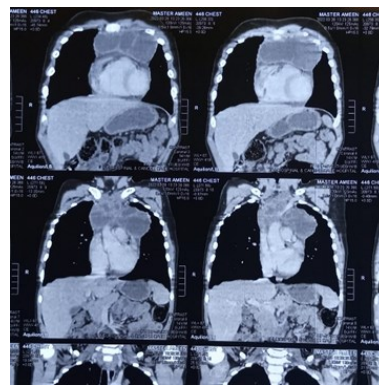
There was mild degree of facial puffiness, but no neck vein prominence. The rest of examination was unremarkable.

### Laboratory and Radiographic Findings

Blood investigations revealed a normal hemoglobin (10.0 gm/dL), total leukocyte counts (13000/dL), and platelets ( $396 \times 10^3$ /dL). Chest radiograph revealed a mediastinal widening (Figure 1). A computed tomographic scan of chest was done with intravenous contrast for procuring the anatomy of the lesion. It showed a multi septate homogenous anterior mediastinal lesion abutting the great vessels and pericardium, with associated minimal pericardial effusion (Figure 2). The tumor markers were sent, which revealed a serum LDH of 301 and alpha feto-protein of 4.96; both being within the normal range. On the basis of above findings, lymphoma or germ cell tumour were considered.



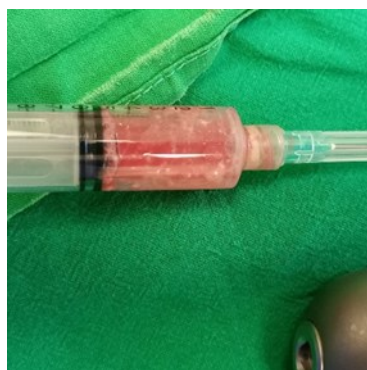**Figure 1:** Chest radiograph showing mediastinal widening.



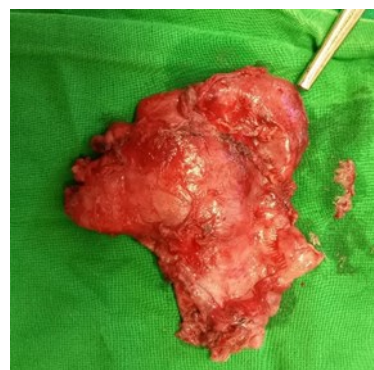**Figure 2:** Contrast enhanced chest computed tomography revealing multi septated homogenous anterior mediastinal lesion abutting the great vessels and pericardium.

### Clinical Course

As the lesion was in close proximity to the cardiac structures, therefore, the cardiothoracic team was taken on board. The child underwent median sternotomy, the lesion meticulously dissected off its surroundings, especially the left innominate artery, to which it was densely adherent. The aspiration of lesion contents was done revealing cheesy white material raising the possibility of it being tuberculous (Figure 3). The lesion was removed (Figure 4) and sent for histopathology which later revealed epithelioid cell granulomas with necrosis, therefore, diagnosis of tuberculosis was entertained.



**Figure 3:** Syringe showing aspirated lesion contents being cheesy white material.



**Figure 4:** Anterior mediastinal lesion excised in toto.

## Discussion

Tuberculosis can have varied manifestations however, presenting as an isolated mediastinal mass without parenchymal lesion is uncommon [3, 5]. It is, however, not so unusual in immunocompromised patients [6]. Common differential diagnoses of an anterior mediastinal mass include lymphoma, thymoma, teratomatous neoplasms, vascular masses, thyroid mass, lymph node enlargement secondary to metastases or granulomatous disease, and pleuropericardial and bronchogenic. In younger age group, the one like ours, germ cell tumours and lymphoma are more likely [1]. It is a difficult task to differentiate one pathology from another on the basis of radiology. The attenuation values on CT scan for fat, water, calcium, or necrosis may assist in tunnelling down the differential diagnoses. Along with this the exact site and morphology of the mass along with clinical features such as age, gender, signs and symptoms, and biochemical values, would assist in narrowing down the differentials. [1, 2, 6]. However, histopathology of the tissue is mandatory for definite diagnosis. [1, 2, 7].

The diagnosis of germ cell tumors is based on histopathology and associated increase in serum  $\alpha$ -fetoprotein or  $\beta$  hCG levels. In our patient, histology showed epithelioid cell granulomas with necrosis. Differential diagnosis of sarcoidosis, tuberculosis, or fungal infections may be considered. Sarcoidosis is characterized by nonnecrotizing granulomatous inflammation. Both tubercular as well as fungal granulomas may be necrotic. In order to differentiate between them, Ziehl-Neelsen staining is a quick and definitive method of diagnosis.

A striking feature in this patient was involvement of vessels and abutting with the adjacent pericardium, which is unusual with tubercular lymphadenopathy. Teratoma and lymphomas have similar presentation during adolescence [6].

## Conclusion

In conclusion, tubercular infection can have varied presentations. Though presentation as an isolated mediastinal mass is rare in immunocompetent children, but keeping in view Pakistan's clinical setting, supported with clinical, radiological and histopathological support, the diagnosis should be given due consideration in view of anterior mediastinal lesions.

## Conflict of Interest

The authors have indicated they have no potential conflicts of interest to disclose.

## References

1. Strollo DC, Rosado de Christenson ML, Jett JR. Primary mediastinal tumors. Part 1: tumors of the anterior mediastinum. *Chest*. 1997;112(2):511-522. doi:10.1378/chest.112.2.511
2. Strollo DC, Rosado-de-Christenson ML, Jett JR. Primary mediastinal tumors: part II. Tumors of the middle and posterior mediastinum. *Chest*. 1997;112(5):1344-1357. doi:10.1378/chest.112.5.1344
3. Kim HY, Song KS, Goo JM, Lee JS, Lee KS, Lim TH. Thoracic sequelae and complications of tuberculosis. *Radiographics*. 2001;21(4):839-860. doi:10.1148/radiographics.21.4.g01jl06839
4. Maguire S, Chotirmall SH, Parihar V, et al. Isolated anterior mediastinal tuberculosis in an immunocompetent patient. *BMC Pulm Med*. 2016;16:24. Published 2016 Feb 3. doi:10.1186/s12890-016-0175-7
5. Hadlock FP, Park SK, Awe RJ, Rivera M. Unusual radiographic findings in adult pulmonary tuberculosis. *AJR Am J Roentgenol*. 1980;134(5):1015-1018. doi:10.2214/ajr.134.5.1015
6. Quint LE. Imaging of anterior mediastinal masses. *Cancer Imaging*. 2007;7 Spec No A(Special issue A):S56-S62. Published 2007 Oct 1. doi:10.1102/1470-7330.2007.9014
7. Tscheikuna J, Suttinont P. Is cytology necessary in diagnosis of mediastinal mass?. *J Med Assoc Thai*. 2009;92 Suppl 2:S24-S29.

**Citation:** Yaseen TM, Zulfiqar A, Hussain S, Fazal A. Tuberculosis Presenting as Anterior Mediastinal Mass - A Possibility in An Immunocompetent Child. *SVOA Paediatrics* 2024, 3:2, 22-24.

**Copyright:** © 2024 All rights reserved by Yaseen TM., et al. This is an open access article distributed under the Creative Commons Attribution License, which permits unrestricted use, distribution, and reproduction in any medium, provided the original work is properly cited.